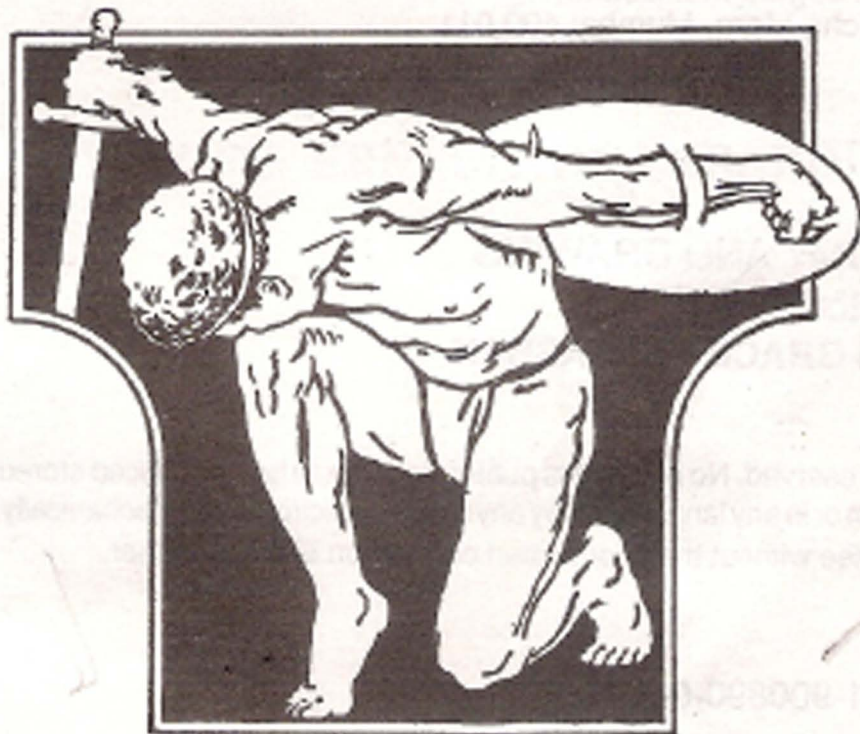


# ANATOMY AND DRAWING BY VICTOR PERARD

Art Instructor Traphagen Art School, New York City.  
Lecturer on Anatomy, formerly Art Instructor Cooper Union, New York City.  
Graduate Ecole des Beaux-Arts, Paris, the National Academy of Design and Art  
Students' League, New York City—Painter and Illustrator.



*Published by*  
**GRACE PRAKASHAN**

Arts De Trio, 183, J.S. Road, Girgaum, Bombay 400 004  
All rights to publish, distribute and sell in India reserved to the Publishers.

## CONTENTS

OVER A THOUSAND ILLUSTRATIONS

	PREFACE	vii
I	PROPORTION AND DRAWING	1
II	THE SKELETON	29
III	THE HEAD AND NECK	37
IV	THE TORSO	63
V	THE ARM	83
VI	THE HAND	111
VII	THE LEG	143
VIII	THE FOOT	165
IX	THE ECORCHE	179



## PREFACE

The purpose of this book is to present in a simple and direct manner the subject of anatomy as it is applied to Art. As little text as possible has been used, and much dependence has been placed on pictorial representation because the latter are a more direct means of impressing the artist with construction and form. For this reason this work has been copiously illustrated, often showing various views of the same structures and action.

To the beginner the study of anatomy is too often dull, prosaic and difficult and this is due, in large part, to the fact that many text books on the subject contain insufficient descriptive drawings. Even though the student plows through many pages of text, he often fails to visualize the subject properly. Therefore it has been endeavored to substitute

illustrations for descriptive text whenever practical. The drawings have been arranged in groups for the purpose of comparison, and in this way they become accustomed to observe much which otherwise might escape attention.

To express outward form correctly requires a knowledge of the internal structure, that is, of the bones which compose the framework and define its proportions and of the muscles and tendons which direct its action.

Every figure artist finds sooner or later, as he advances in his artist career, that his work needs strengthening through a well grounded knowledge of anatomy. The great masters of the past realized this and their grasp on the fundamentals of anatomy is reflected not only on their finished works, but in such of their preliminary sketches as are still preserved.

The ability to construct figures correctly from the imagination rather than to depend entirely on models is a distinct aid to the draftsman and to the sculptor. The student of anatomy should therefore test his skill by making memory drawing and by applying his knowledge to compositions of his own fancy.

When working from living models, the artist will find that his knowledge of anatomy will enable him to analyze and interpret the forms before him in a more understanding way

then he could without such information. It will develop in him greater powers of observation. An understanding of anatomy is an instrument in the mechanics of Art: a means to be employed to assist but never allowed to dominate. The artist must learn properly to evaluate his anatomical information and to know the part it is to play in the development of his art. The studies he makes will then be done more intelligently and with better draftsmanship as an inevitable result.

VICTOR PERARD



## NOTES ON PROPORTION

Since proportion is the comparative relation of one thing to another, some standard or unit of measure must arbitrarily be established. In Art, this unit is known as the "head" which is the distance from the top of the skull to the tip of the chin. The illustrations in this book are based on the proportion of seven and a half "heads" to the height of an erect figure. The use of this standard will obviate much

descriptive text. It is well, however to bear in mind that this standard of proportion is modified by such elements as race, sex, age and physical differences peculiar to the individual. For this reason the following notes on proportion are grouped under the heads: Male, Female, Children and General Observations.

*Proportions of the Male.* The greatest width of the male figures is at the deltoids, a little below the shoulders and the width here is about two heads.

The width between the hips should equal one and one half heads, and the width between the nipples one head.

The height of the figure, seven and one-half heads, should approximate one "head" for the head, two and three-quarter heads for the neck and trunk, and three and three-quarter heads for the lower extremities.

From the finger tips to the elbow should measure two heads.

*Proportions of the Female.* The bones of the female are shorter and have less rough surface than those of the male. The sternum or breast bone is shorter and more curved and the pelvis is broader and shallower which gives a greater width to the hips. The sacrum is wider and projects at an angle backward.

The posterior superior iliac spines and the anterior iliac

spines are further apart than those of the male. The distance from the rib cage to the pelvis is greater due to the shallower and broader pelvis.

There is less distance from the crest of the iliacs to the great trochanters of the hips, because the anterior iliac spines are spread out and lower, and further apart. In the female figure the Poupert's ligaments and the furrow of the groin are more horizontal.

The shoulders are narrower and the collar bones (clavicles) straighter and shorter thus giving a more graceful and longer neck and more sloping shoulders in comparison with the square shoulders of the male.

The arms are shorter in proportion to the trunk which is due to the shorter humerus bone of the female, and because the humerus bone is shorter, the elbow is higher.

Variations in the length of the female leg are more frequent than those of the trunk and so it is more difficult to judge the height of the female figure when seated. But the length of the torso is proportionately longer than in the other sex. The legs are shorter and the skull smaller.

The center of the female figures is above the pubic bone while in the male, the center is about at the pubic bone. The width of the female hips is about the width of the chest wall plus that of one arms and is greater than that of the male of the same height. The fact that the female sacrum is at a greater



angle than that of the male and that there is more fat on the buttocks gives these a greater diameter.

The female abdomen, is more rounded and the thighs are thicker from the back to the front than in the other sex.

*Proportions of Children.* The child of three is about one half the height of the adult, and at ten, about three-quarters the height of the adult. As the child grows older the relative sizes of the head and the trunk change. At twenty-five the figures is full grown.

At birth the centre of the figure is a little above the navel, at two years at the navel and at three years the center is level with the iliac bone.

With advancing age this point gradually lowers depending to great extent on the length of the legs.

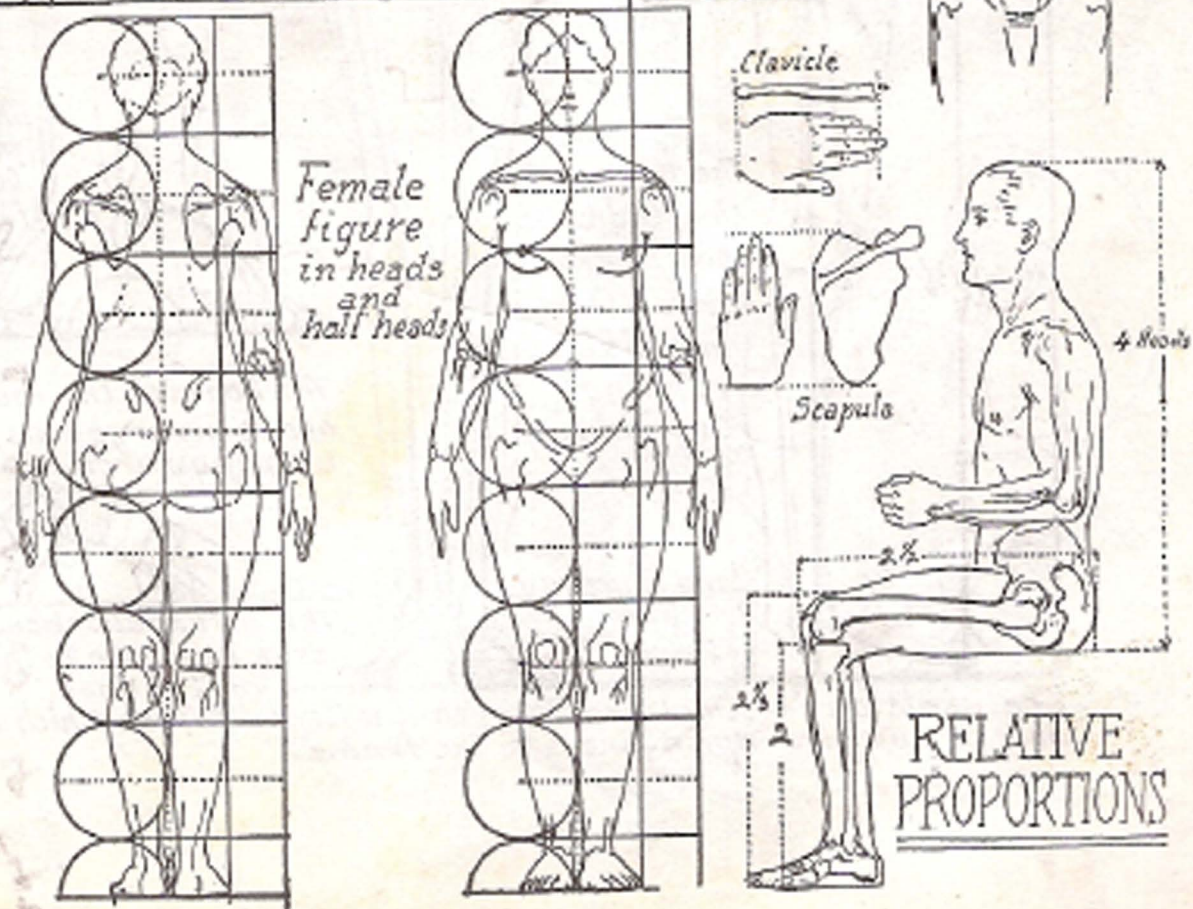
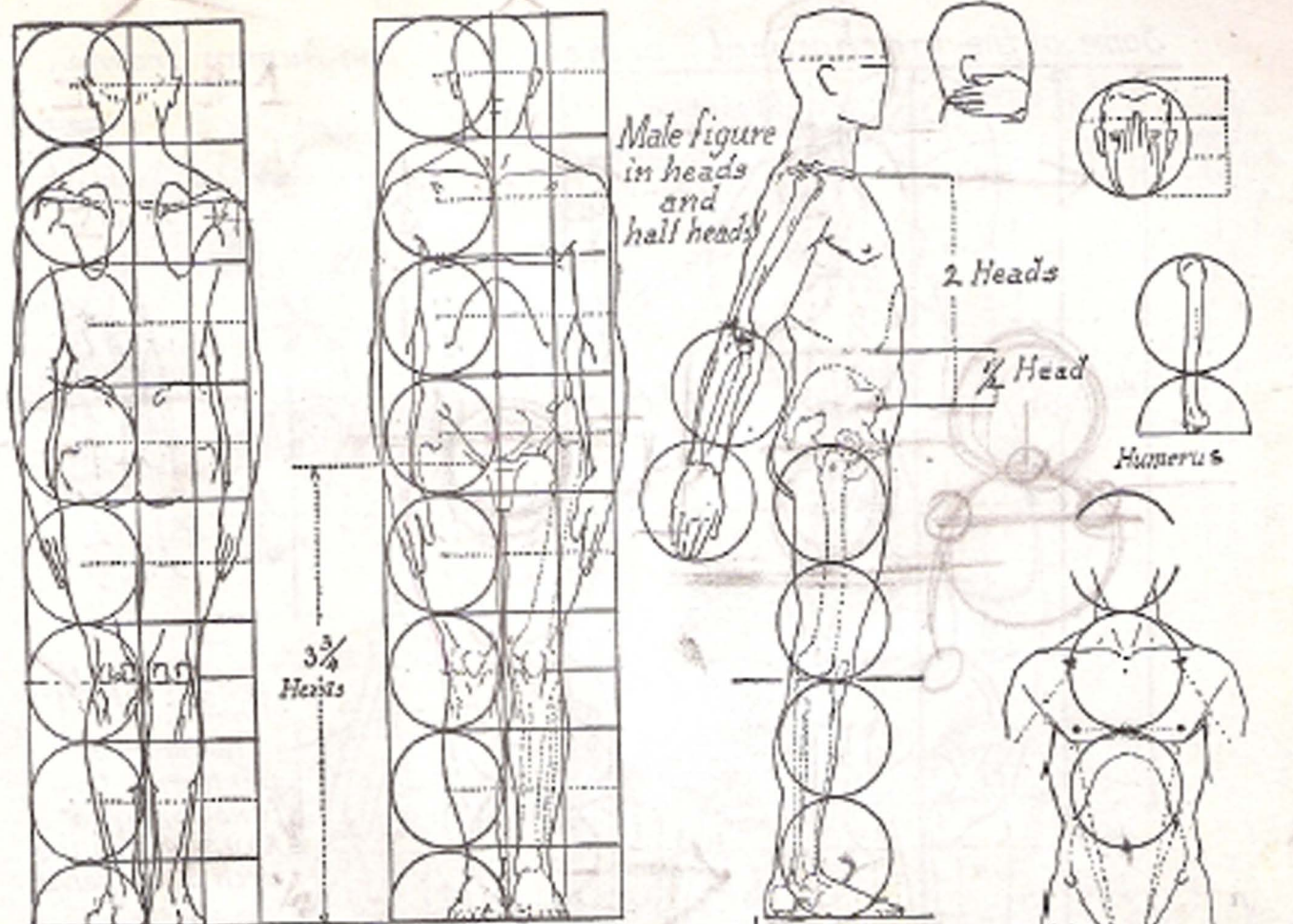
*General Observations.* The clavicle bone continues to grow for a considerable period after the other bones of the body have attained their full development and therefore the shoulders are said to broaden

Only very tall people have a height of eight heads. Short people are seven heads or less. The muscles of the adult account for about one half the weight of the body.

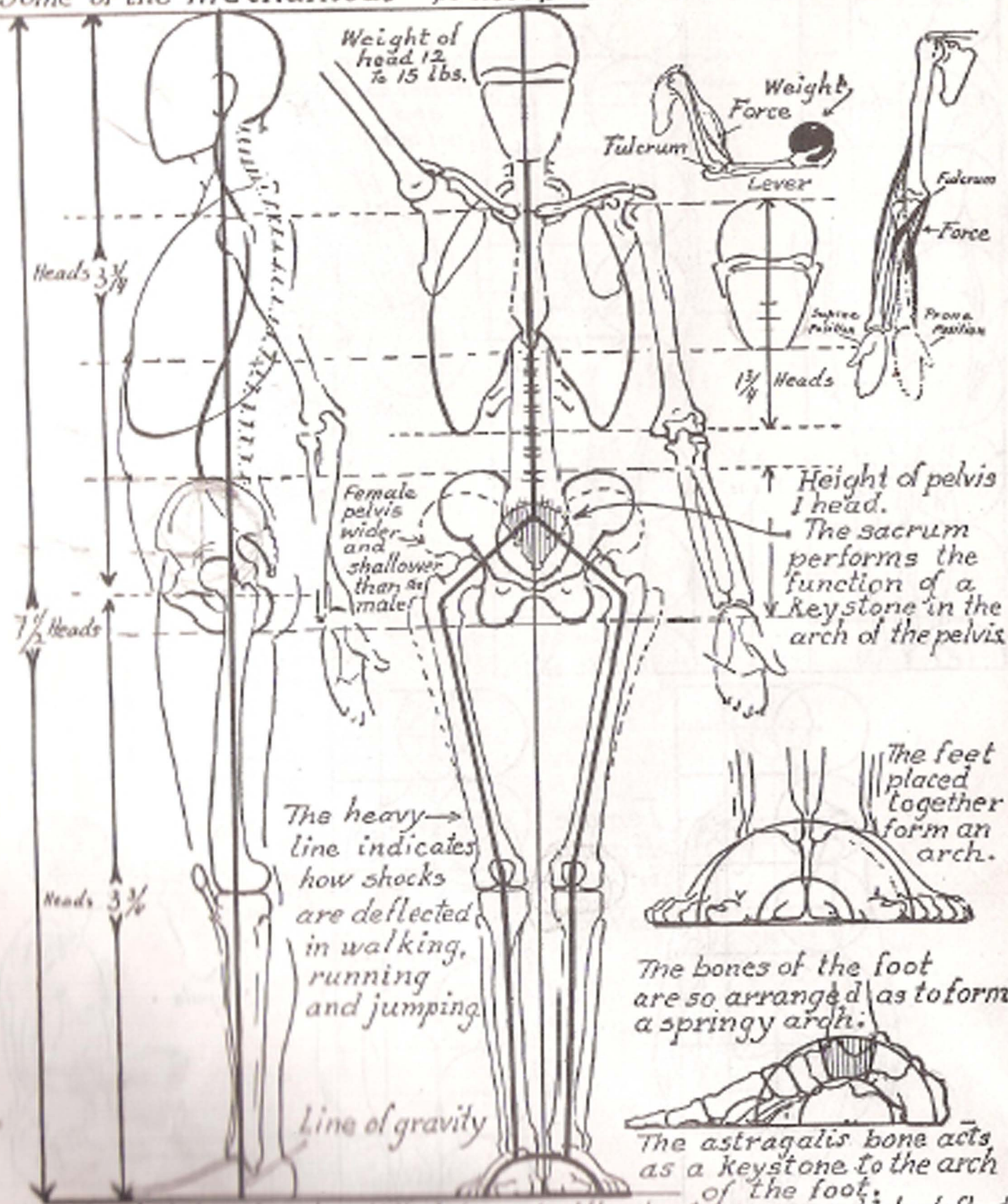
The skeleton always provides the proportions of the figure with slight allowances for the padding between the joints, between each vertebra, and under the heel and foot. In old age the figure shortens due to the hardening and shrinking of the cartilages between the bones.



PART I  
PROPORTION  
AND  
DRAWING



*Some of the mechanical principles of the human frame.*



Weight of head 12 to 15 lbs.

Heads  $3\frac{3}{4}$

$1\frac{3}{4}$  Heads

$7\frac{1}{2}$  Heads

Heads  $3\frac{3}{4}$

Female pelvis wider and shallower than male

Height of pelvis 1 head.  
The sacrum performs the function of a keystone in the arch of the pelvis

The heavy line indicates how shocks are deflected in walking, running and jumping.

Line of gravity

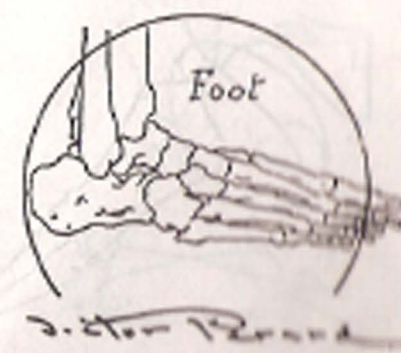
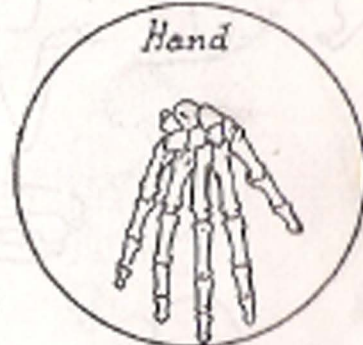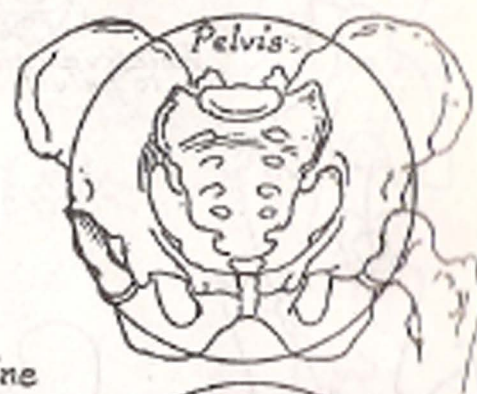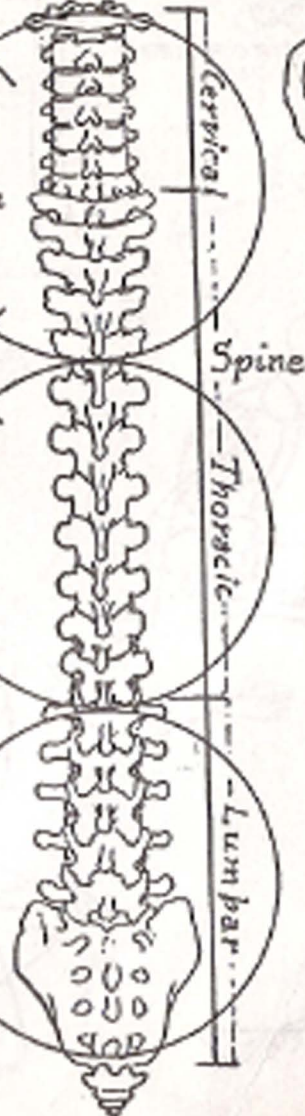

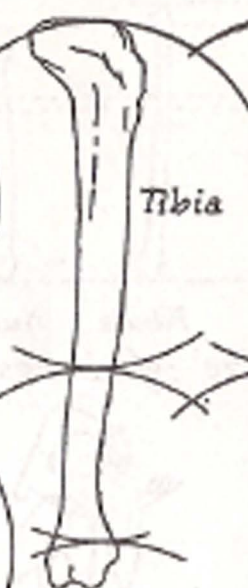
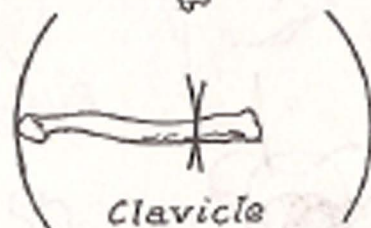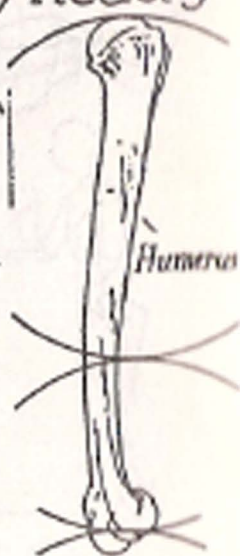
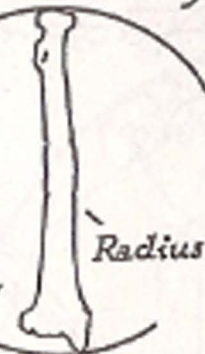
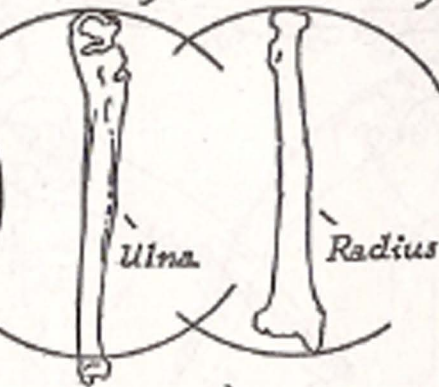
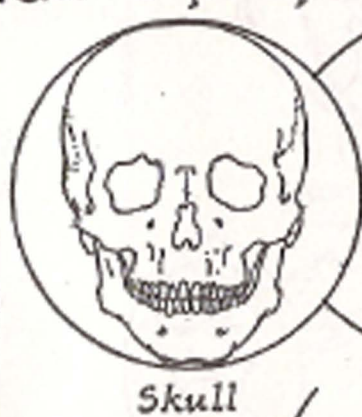
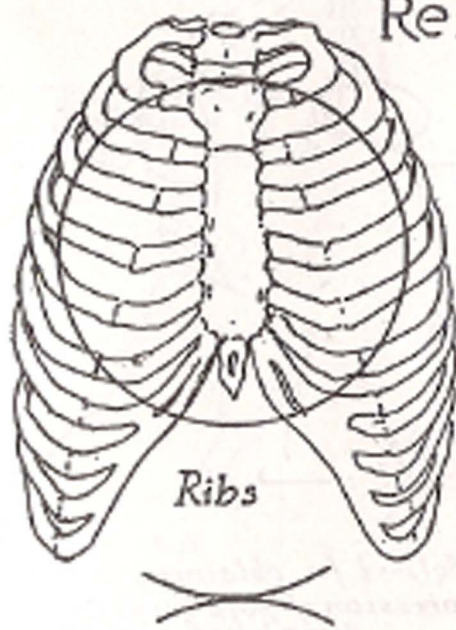
The feet placed together form an arch.

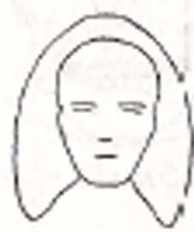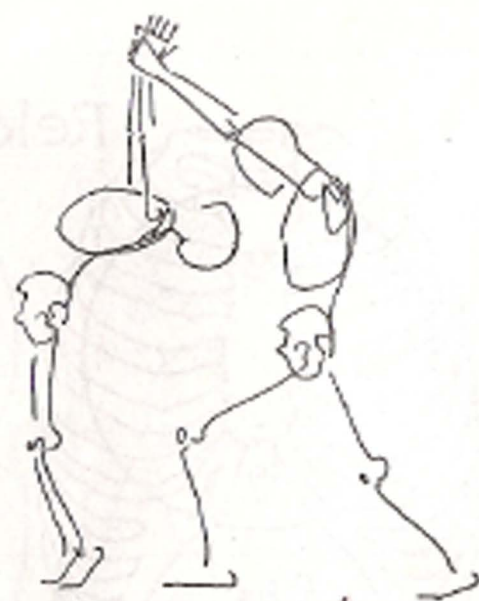
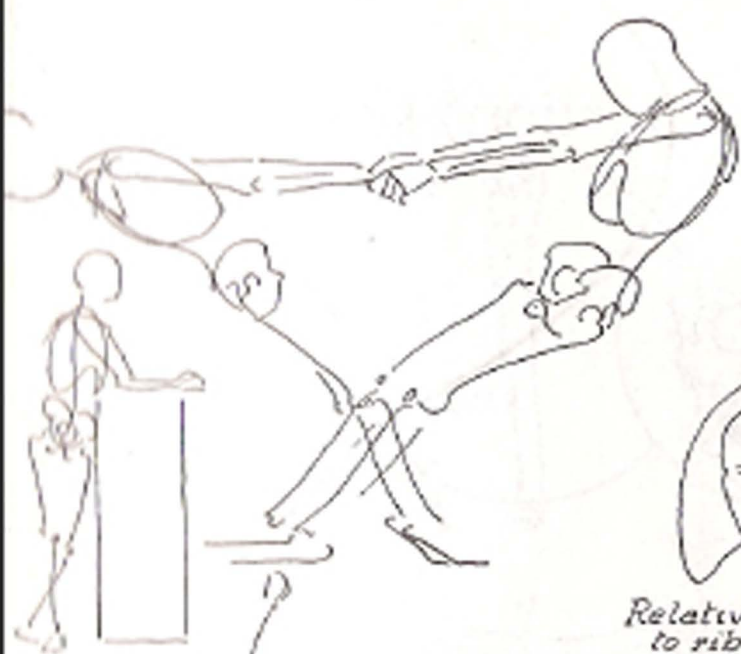
The bones of the foot are so arranged as to form a springy arch.

The astragalus bone acts as a keystone to the arch of the foot.

The skeleton in simplified form to illustrate curves which deflect shocks and give springiness to the frame.

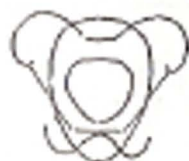## Relative proportion of bones by heads



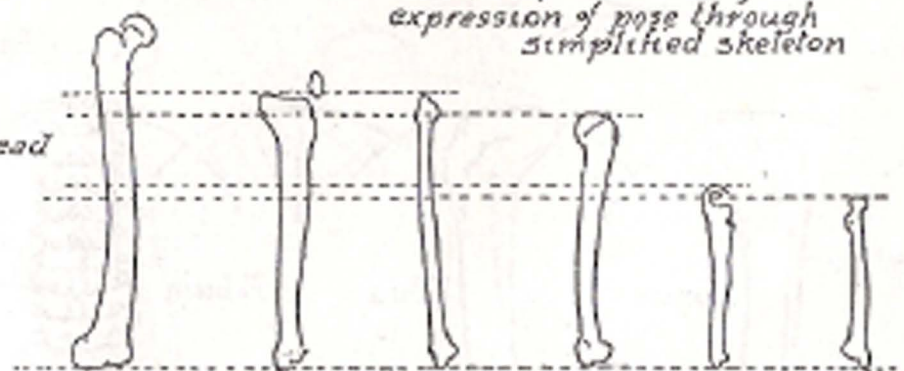


*Relative size of head to rib cage*

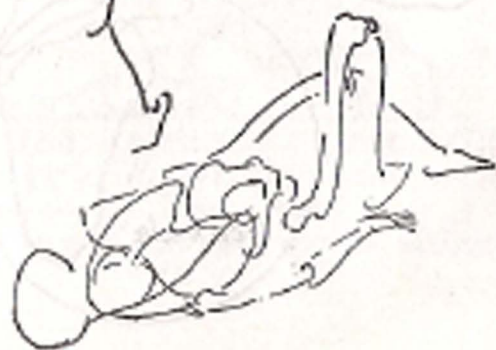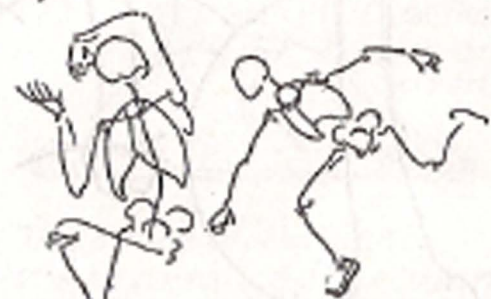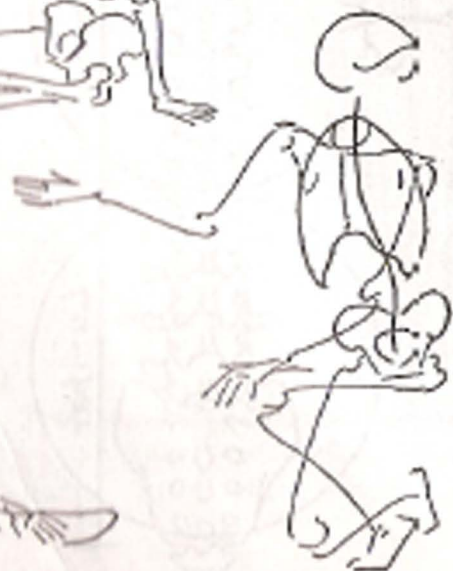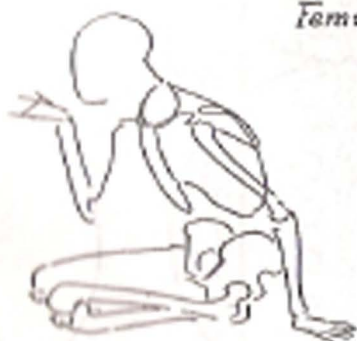*Method for obtaining expression of pose through simplified skeleton*

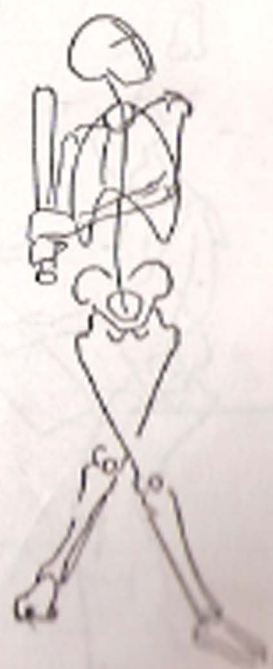
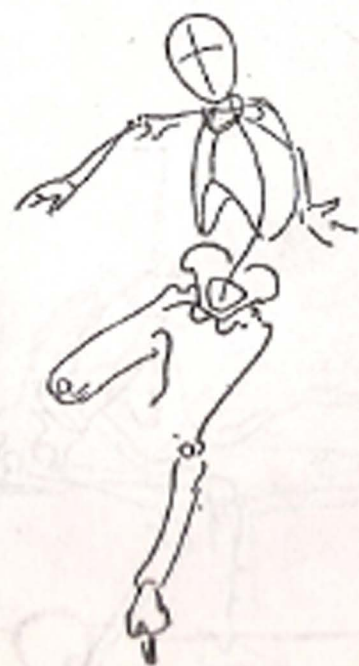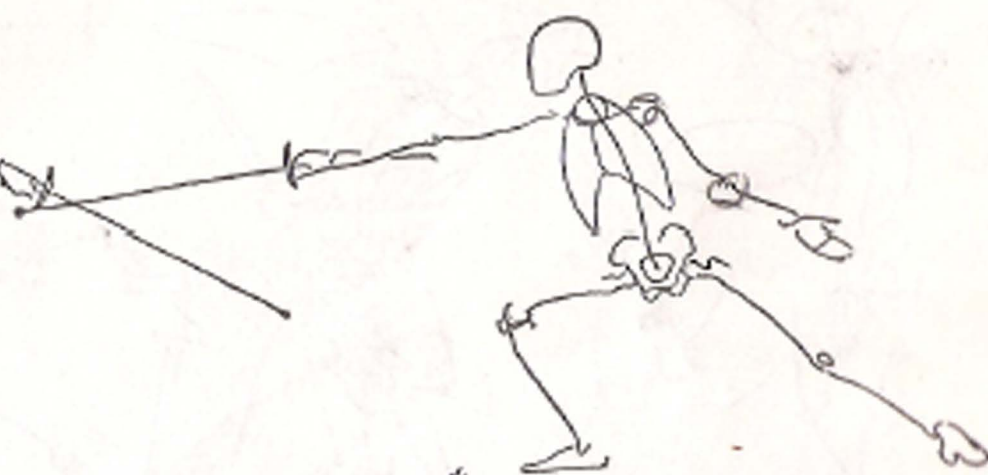

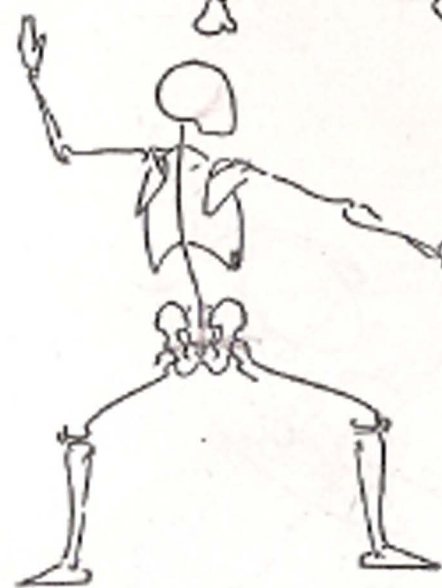
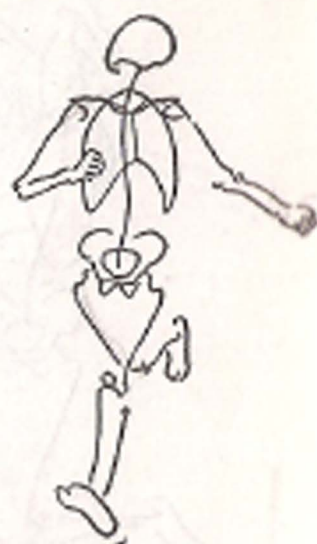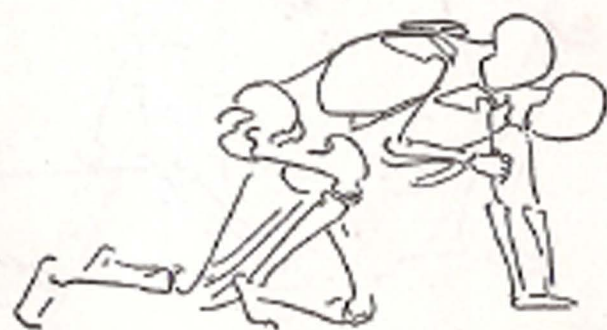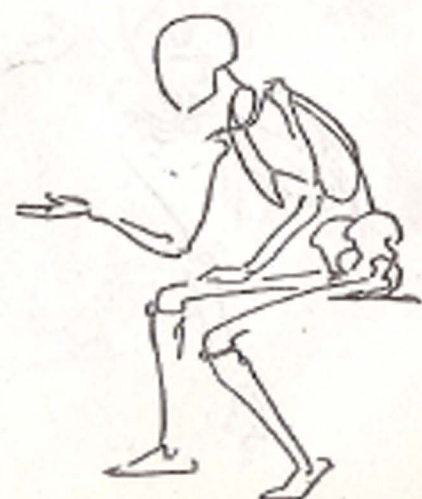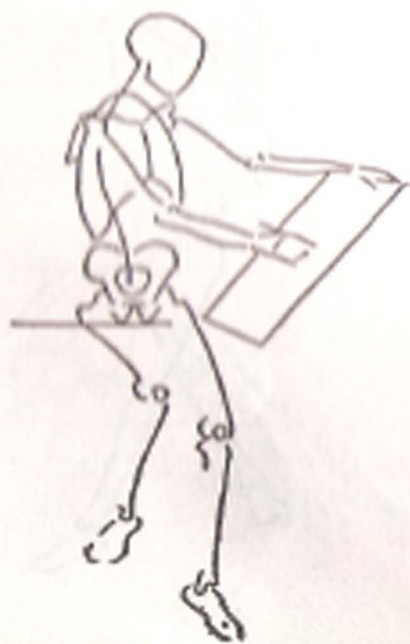
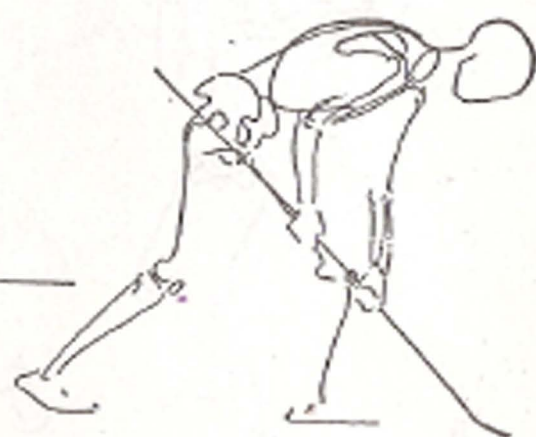
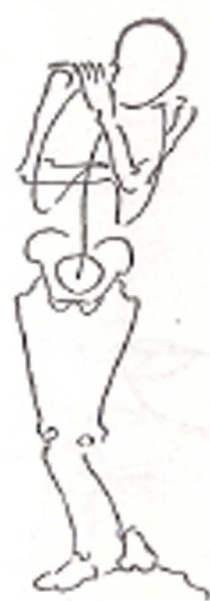
*Relative size of head to pelvic bone*



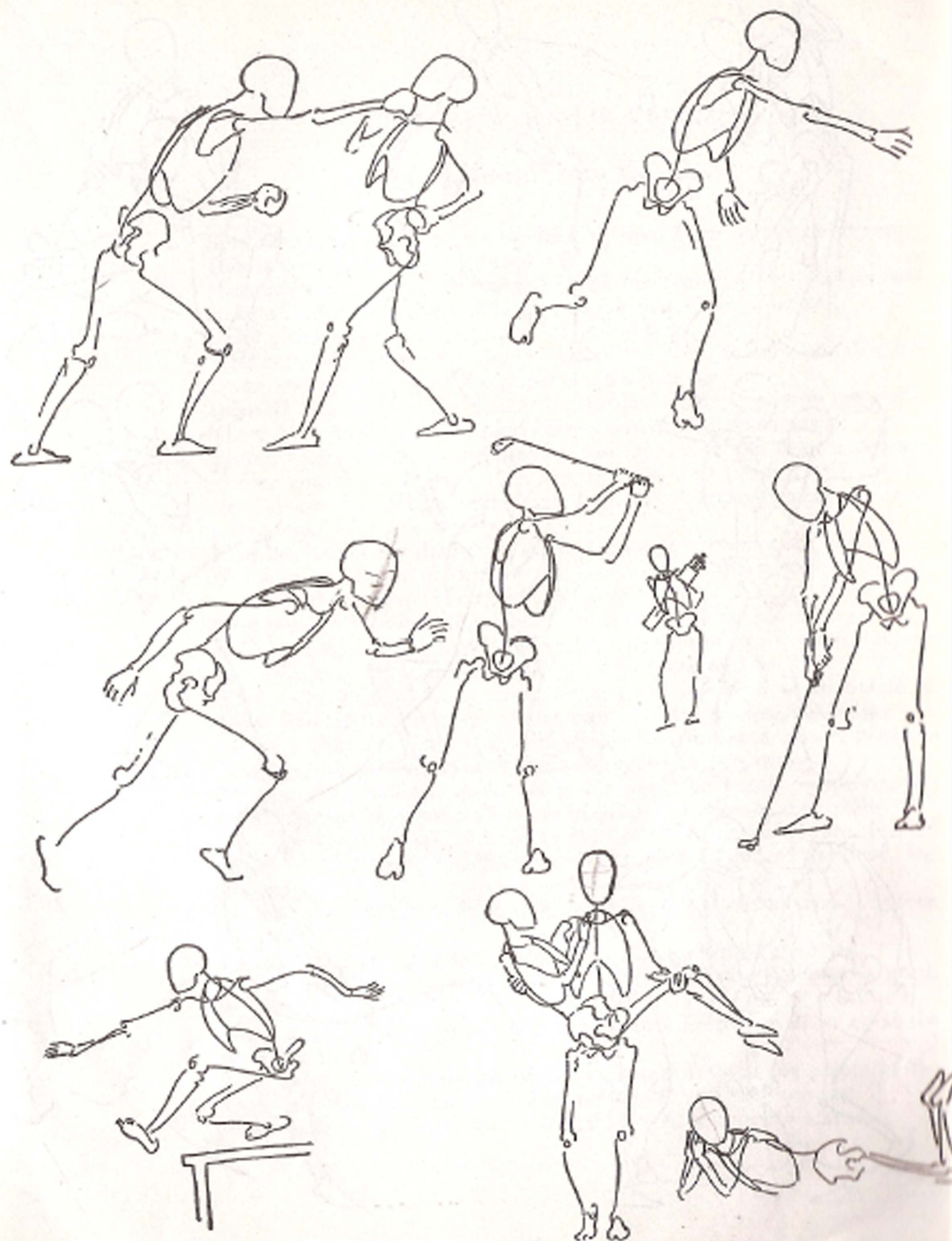
*Femur Tibia Fibula Humerus Ulna Radius*  
*Relative size of bones*

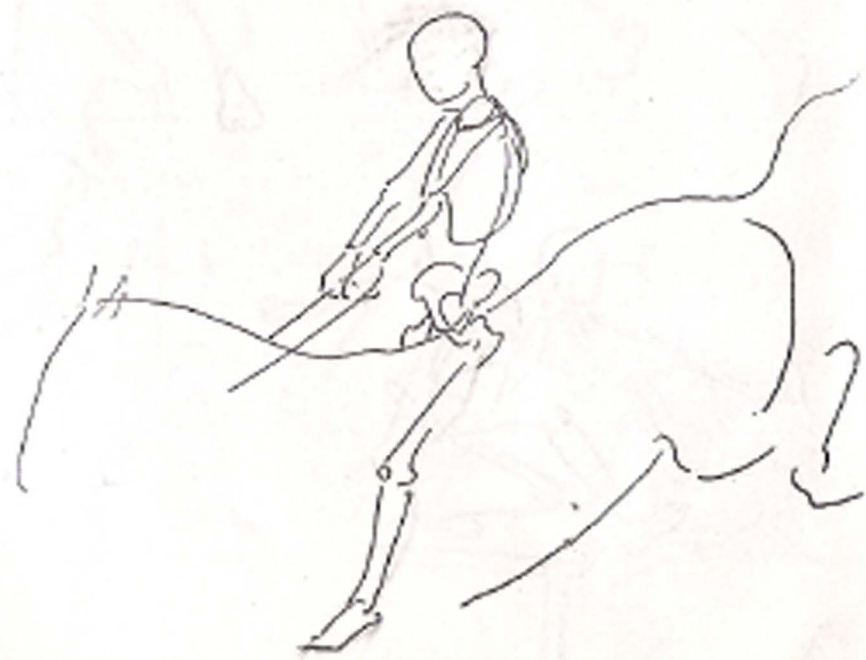
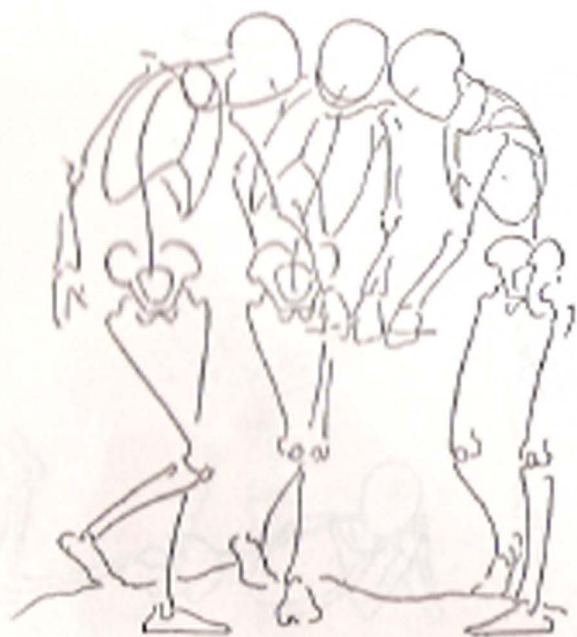
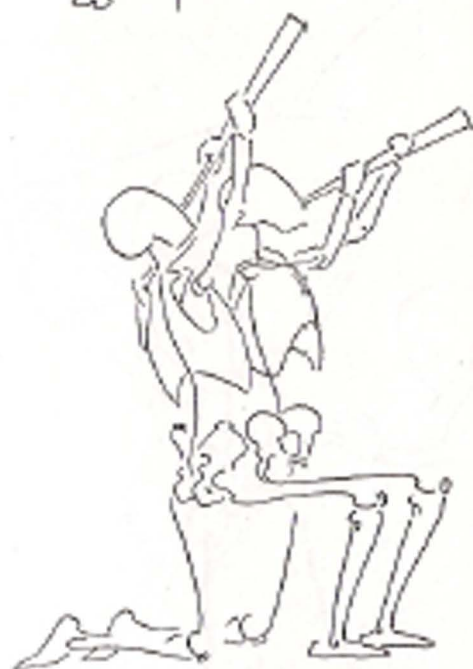
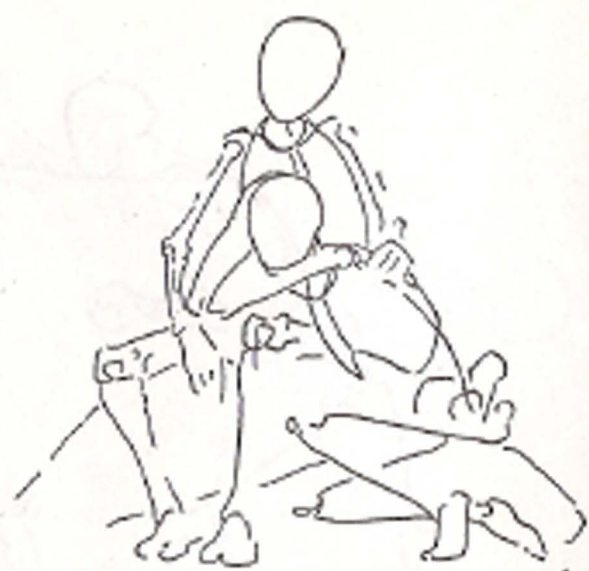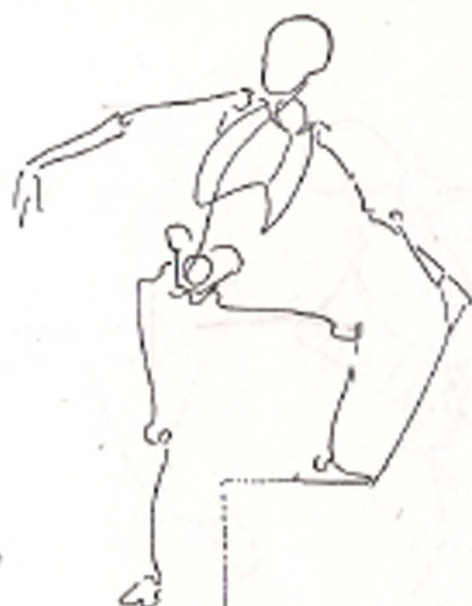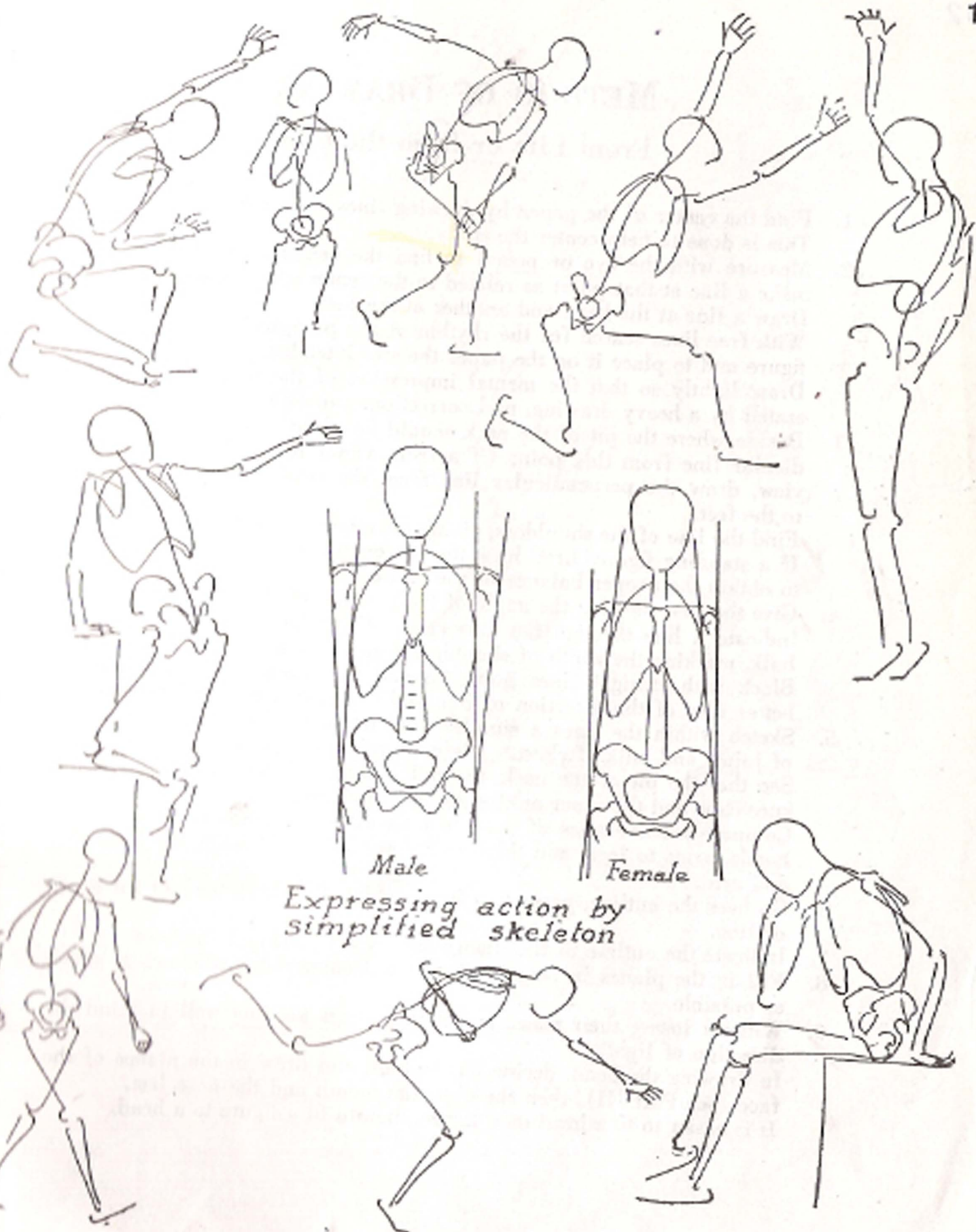








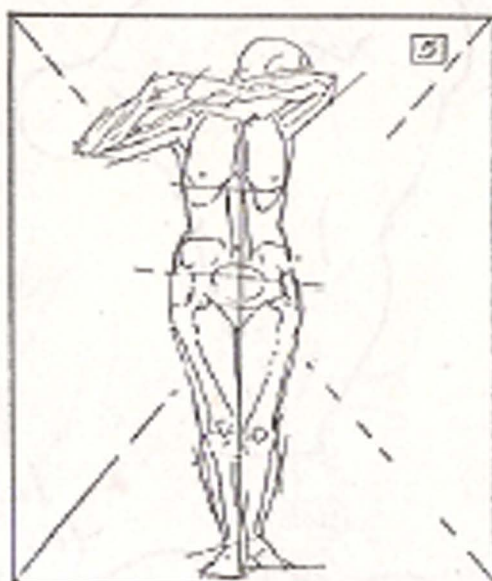
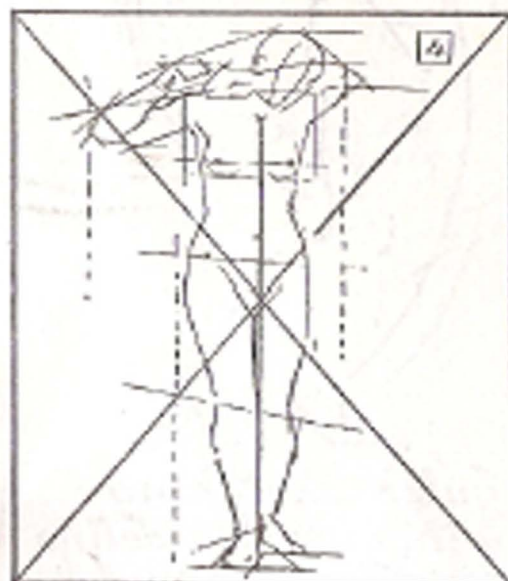
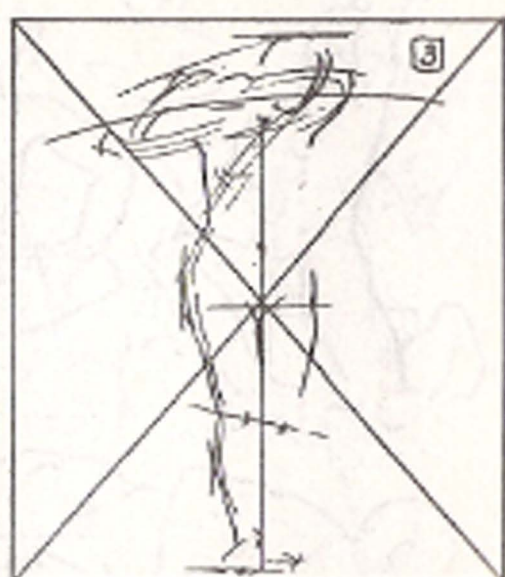


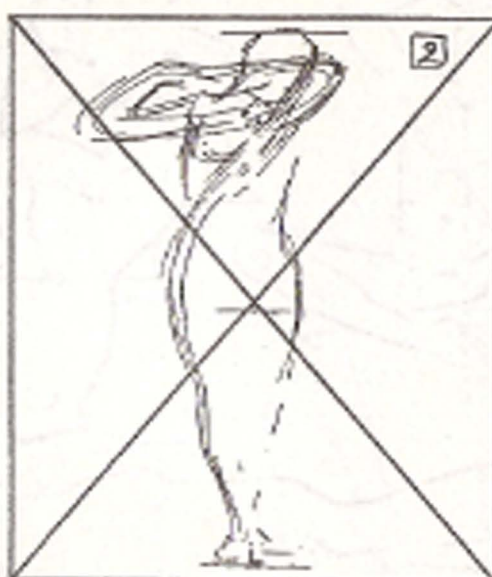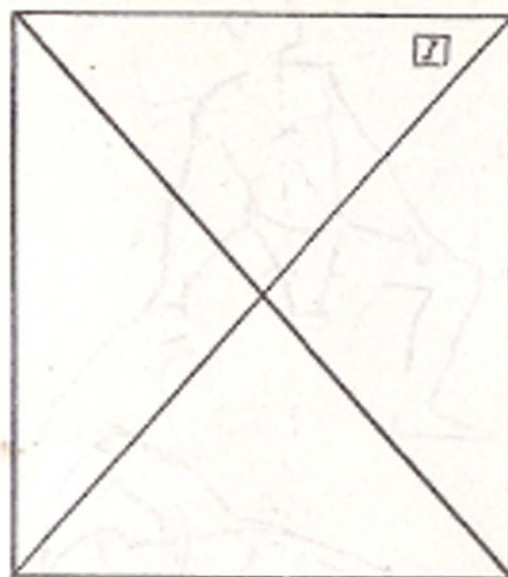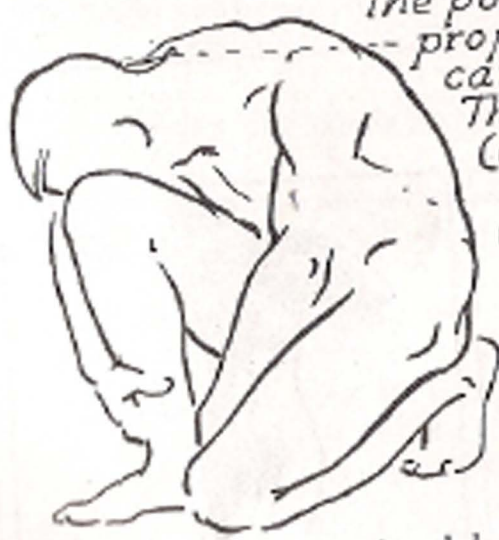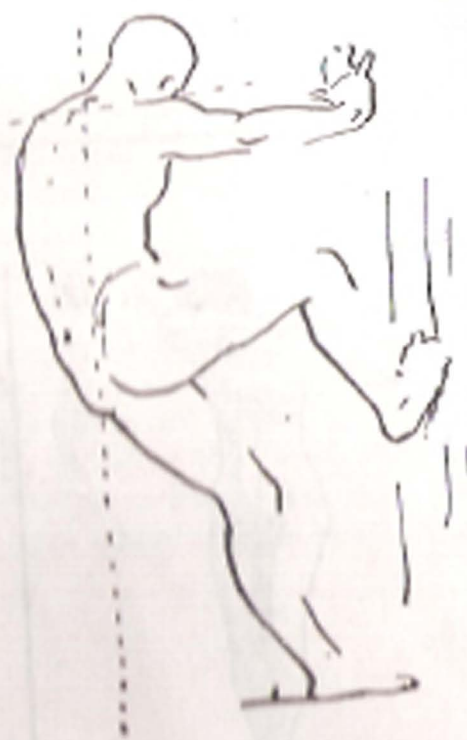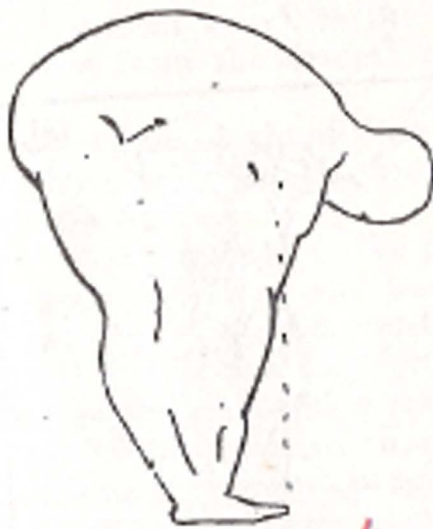


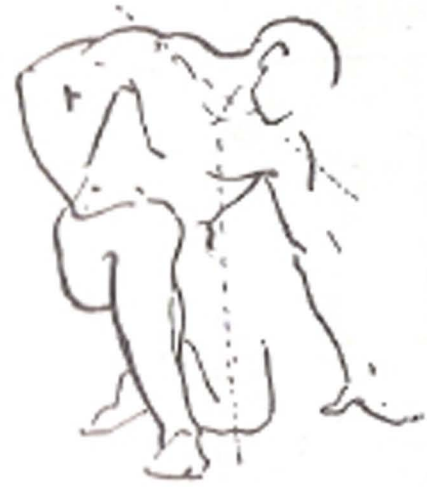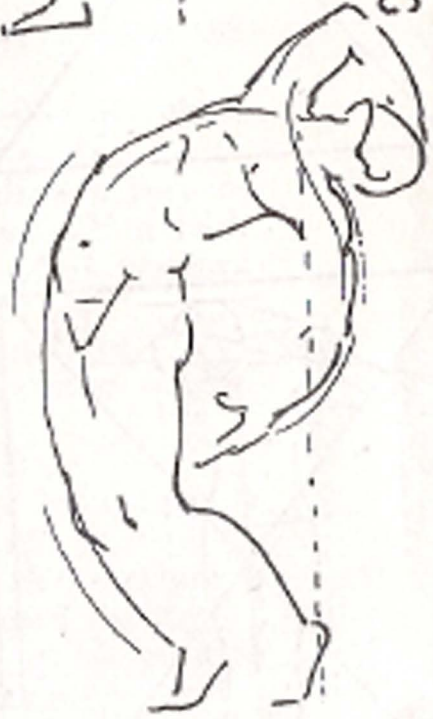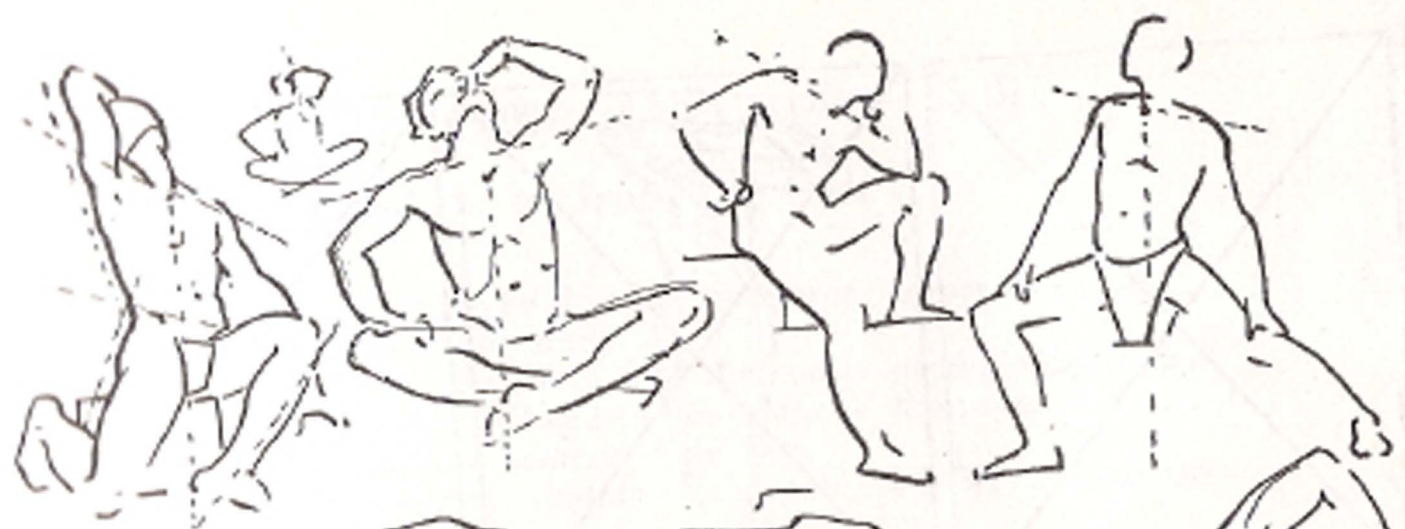## METHOD OF DRAWING

### From Life or from the Cast

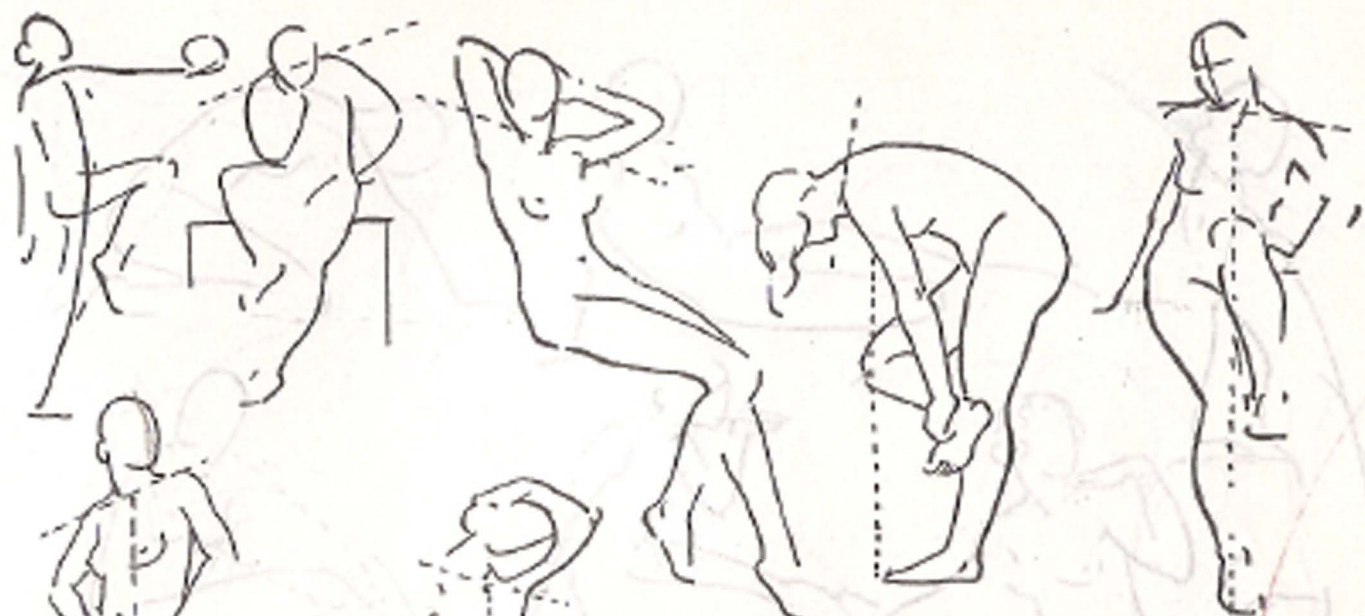
1. Find the center of the paper by drawing lines from corner to corner. This is done to help center the study.
2. Measure with the eye or pencil to find the center of the subject and make a line at that point as related to the center of the paper. Draw a line at the head and another at the feet. With free lines search for the rhythm of the pose, to help visualize the figure and to place it on the paper the size intended. Draw lightly so that the mental impression of the figure is not obliterated by a heavy drawing, and corrections can be easily made.
3. Decide where the pit of the neck should be placed and draw a perpendicular line from this point (if a front view) to the feet. If a back view, draw the perpendicular line from the seventh cervical vertebra to the feet. Find the line of the shoulders, giving the angle of their positions. If a standing figure, first draw the leg on which there is most weight, to obtain the proper balance of the figure.
4. Give the line showing the angle of the position of the pelvis. Indicate a line through the knee-caps. Draw the torso, indicating its bulk, marking the width of shoulders, hips, neck and head. Block with straight lines going beyond the intersections to obtain a better idea of the direction of line and to avoid a cramped feeling.
5. Sketch within the lines a simplified skeleton, to check up on position of joints and bulk of chest. (Refer to pages on proportion.) See that the pit of the neck, the pubic bone, the navel, the pelvis, the knee-caps and the inner ankles are in proper relation to each other. Compare relative sizes of head to bulk of torso, hands to face, feet to hands, arms to legs, and thickness of the neck to that of the head, leg and arm.
6. Go over the outline, perfecting it, searching for character and for grace of line.
7. Indicate the outline of the planes and of the principal shadows.
8. Fill in the planes in large surfaces, and connect the shadows as much as possible.
9. Without losing their mass, model the planes keeping well in mind the direction of light. In drawing the head, decide on the bulk and draw in the planes of the face (see Part III), then the eyes, the mouth and the nose last. It is easier to fit a head on a figure, than to fit a figure to a head.





*k* In quick sketching the points used to define proportions should be carefully marked. Then essential lines (often continuous) drawn. Other lines indicated with strict economy.

Speed should be acquired through judgment, not haste.




*Aids to quick sketching.  
Indicate the angle of the  
shoulders, then the line  
of gravity, then  
express the pose  
with as few lines  
as possible*

*Line of  
gravity*

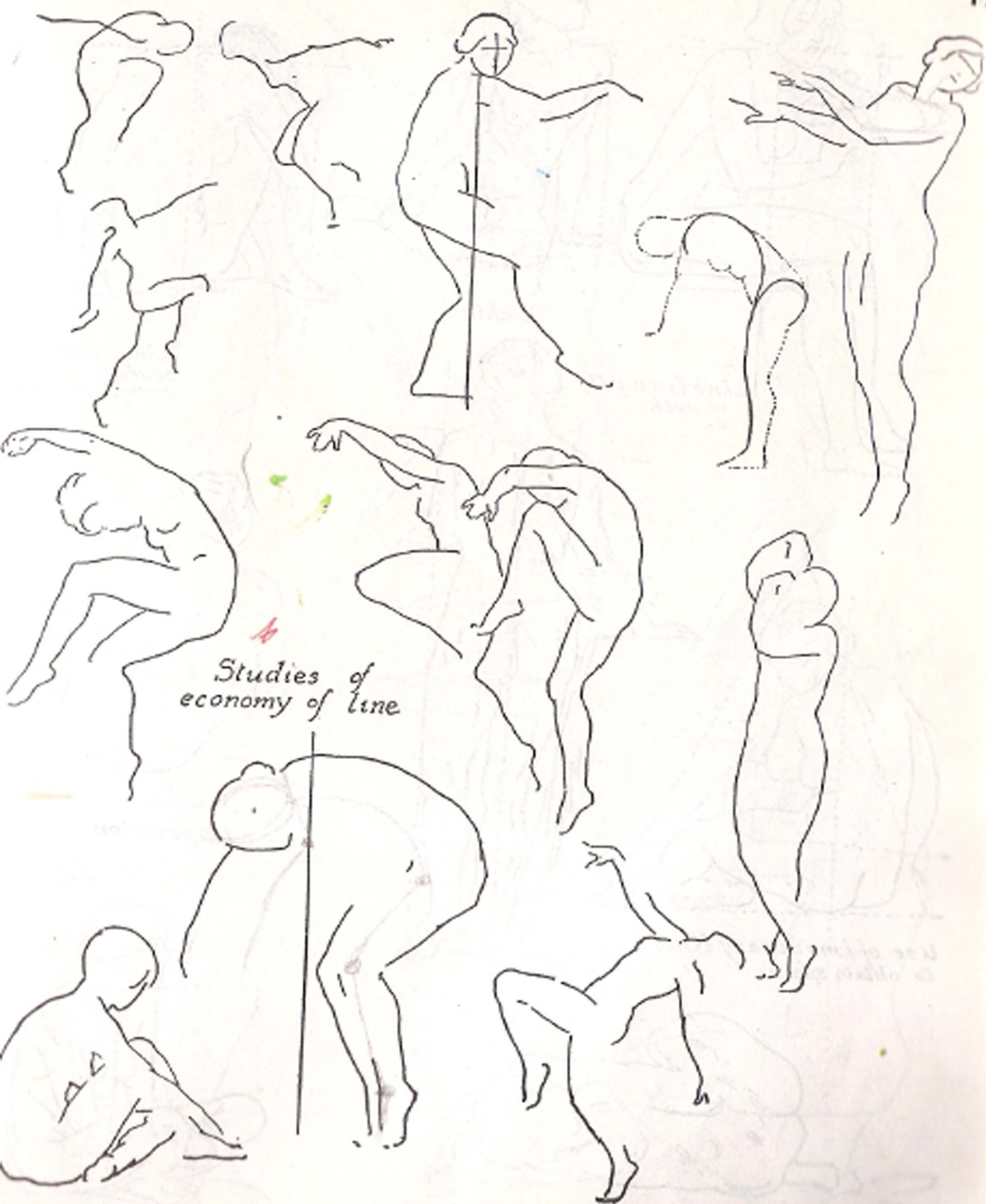


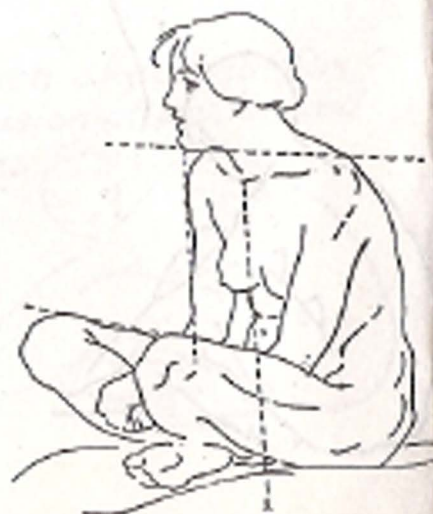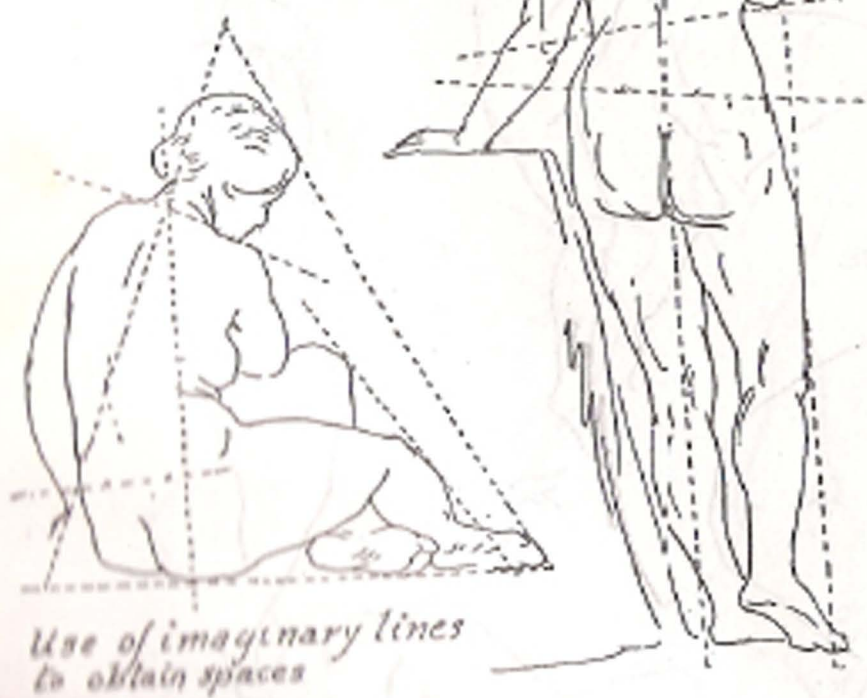
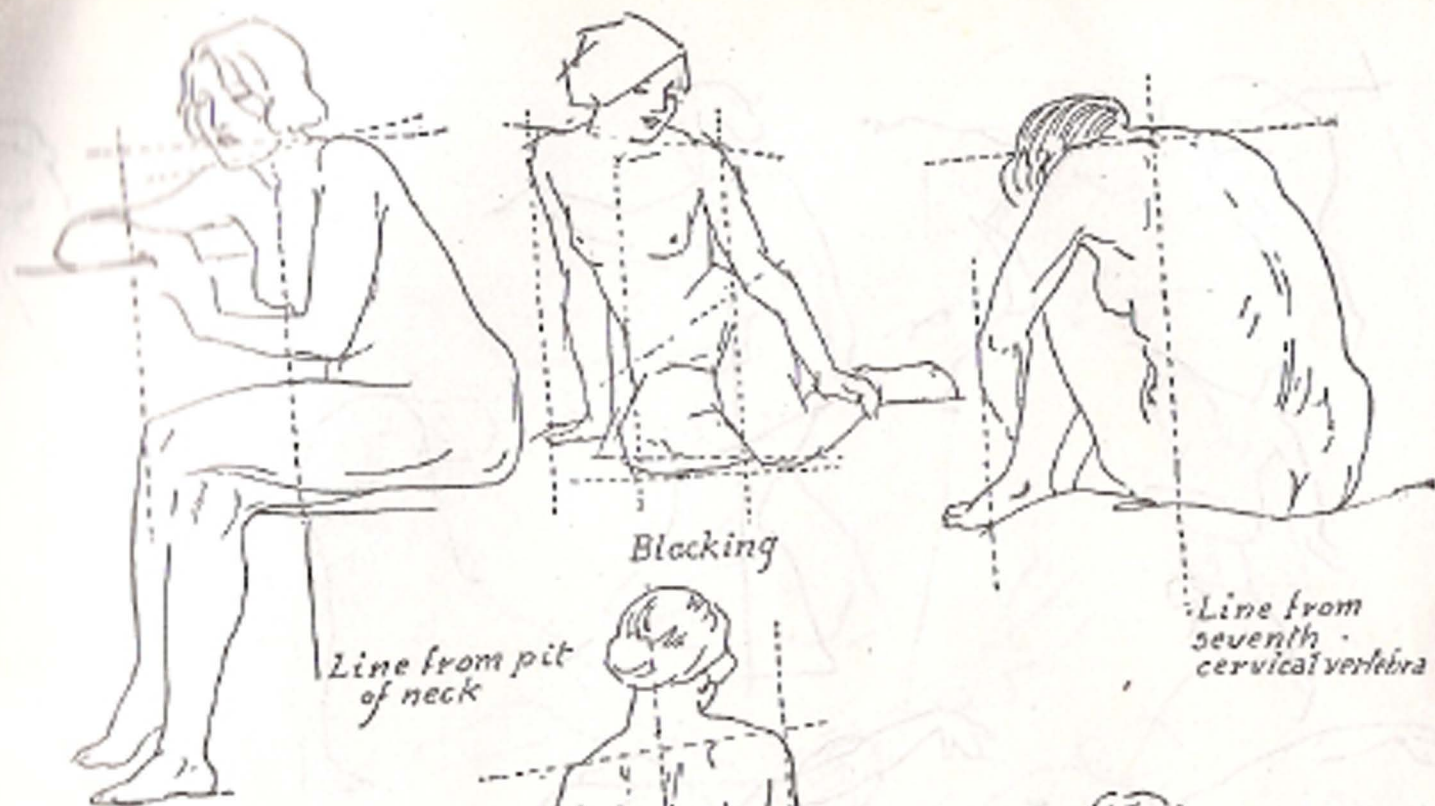
*For line of  
gravity in  
back view,  
draw a  
vertical  
line from  
back of the  
neck.*

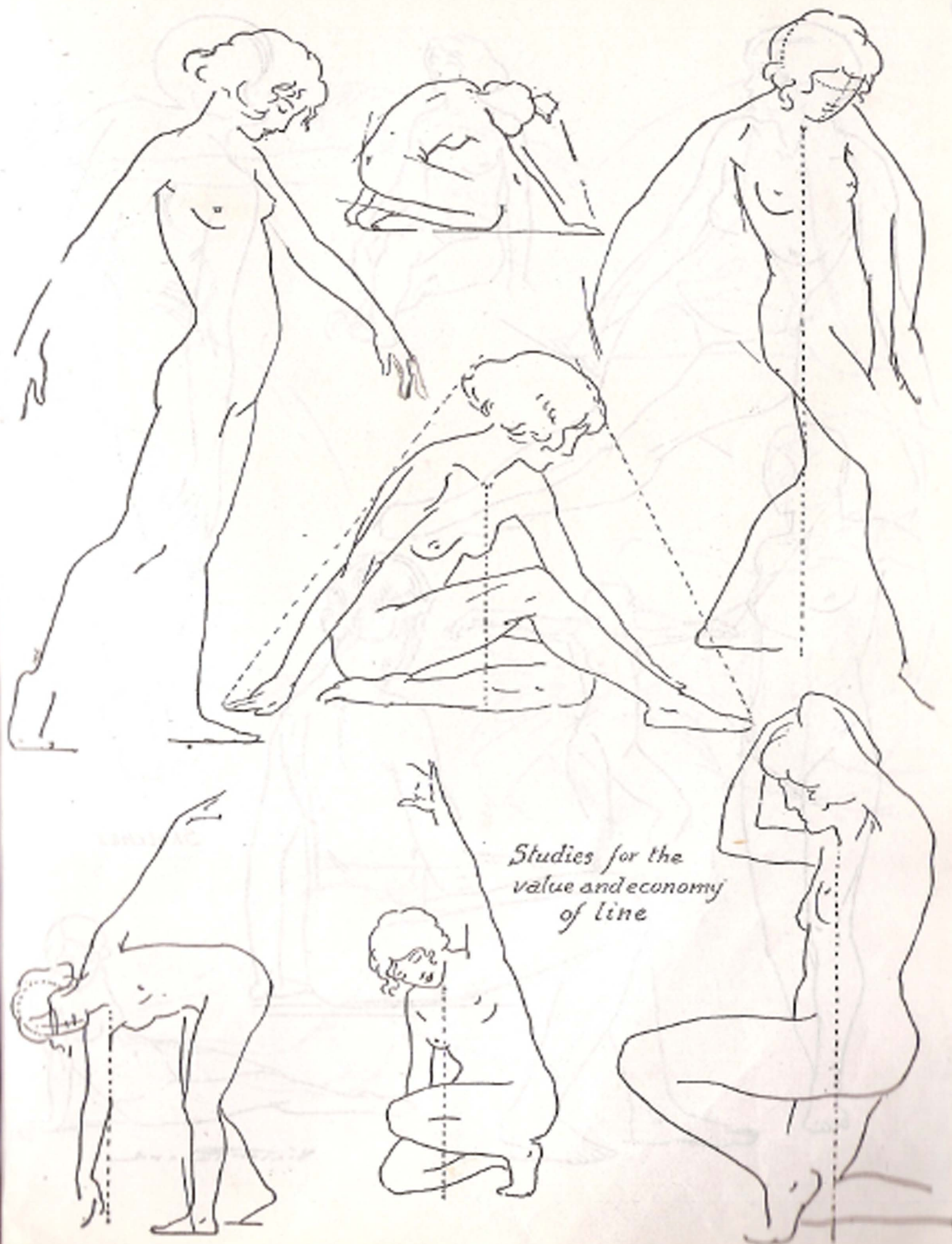


*Five minute sketches for quick decision of action and proportions*

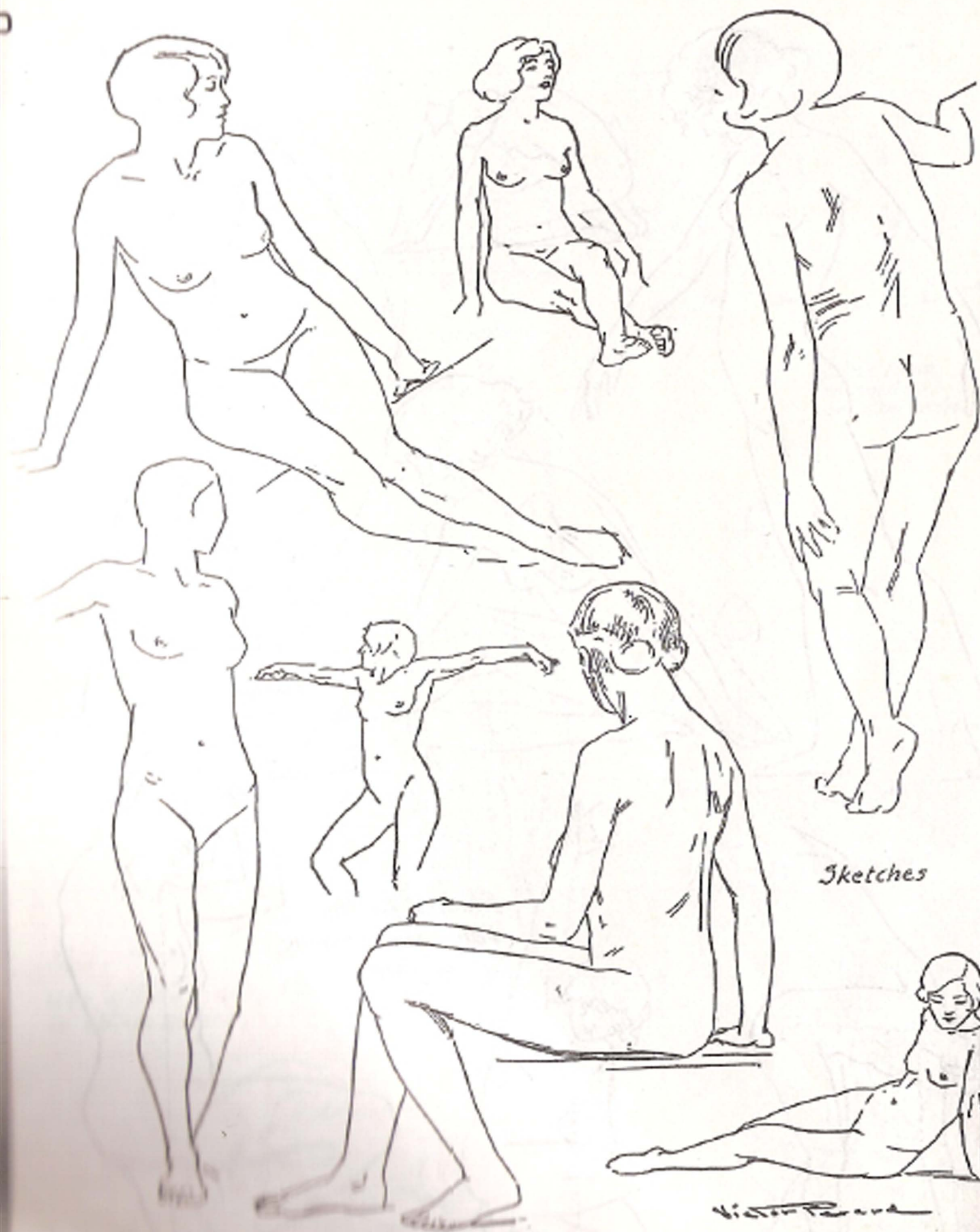






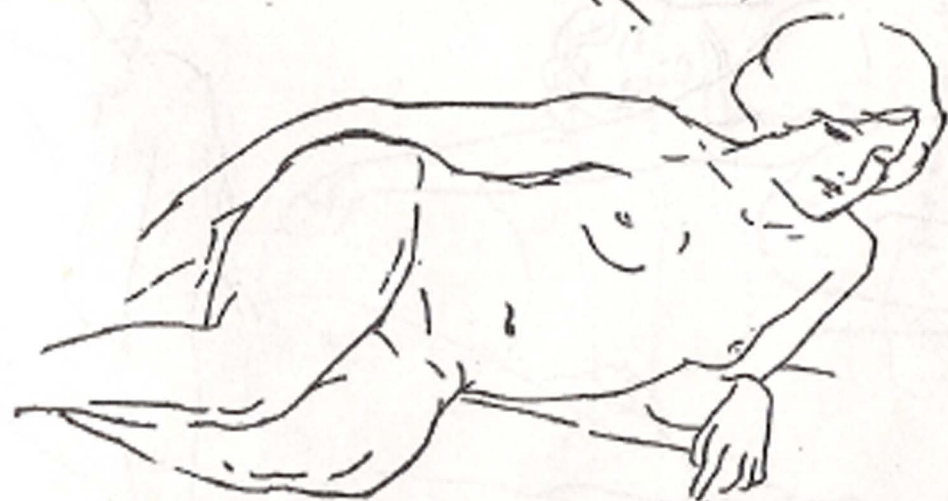
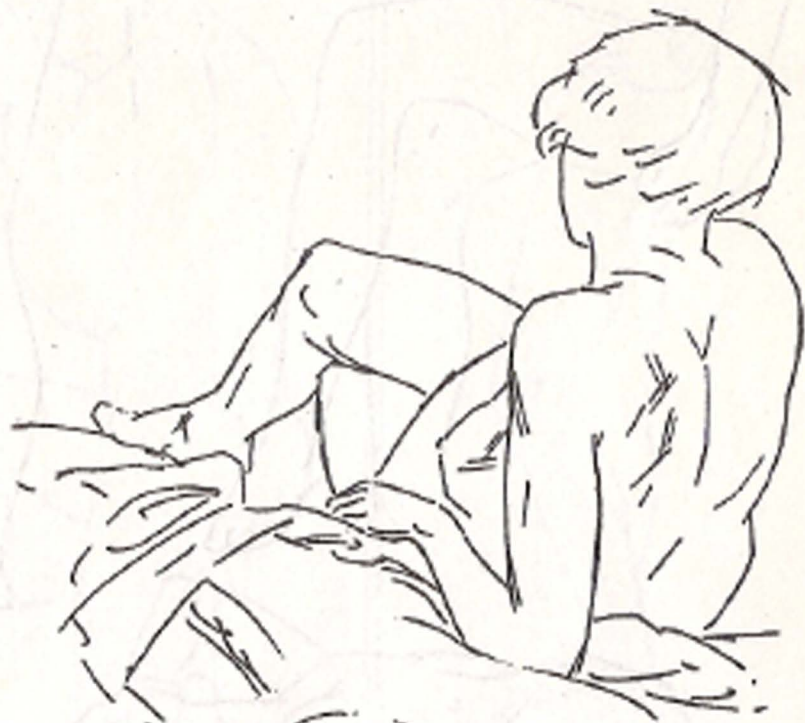
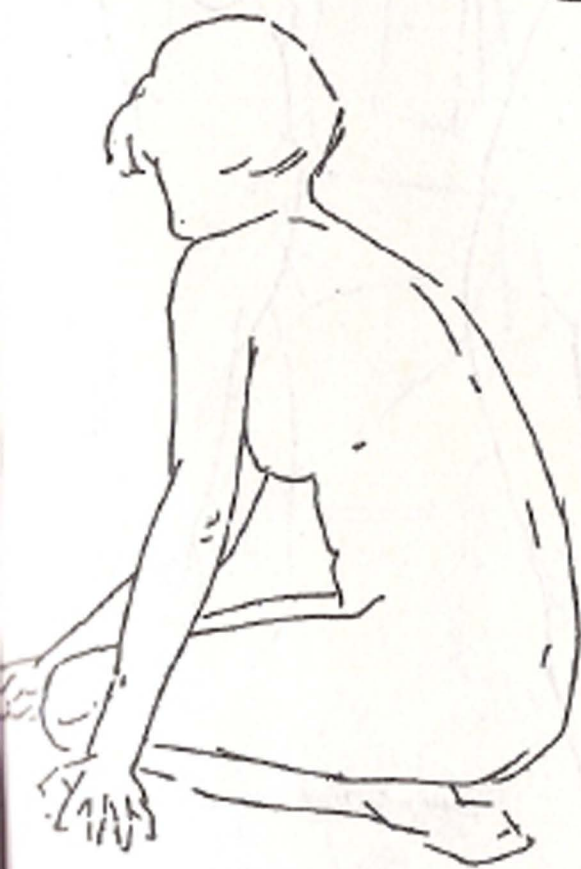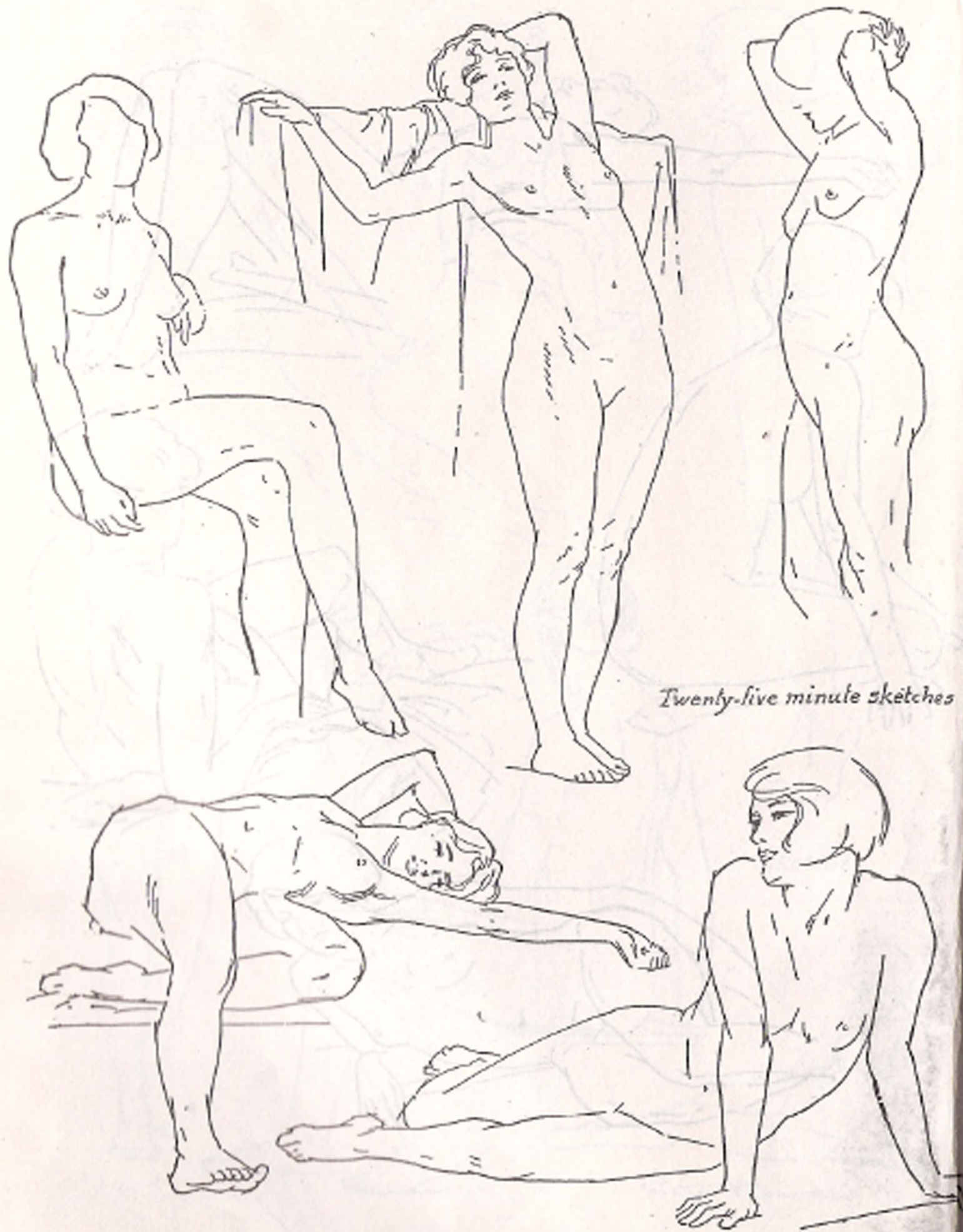
*Studies for the  
value and economy  
of line*



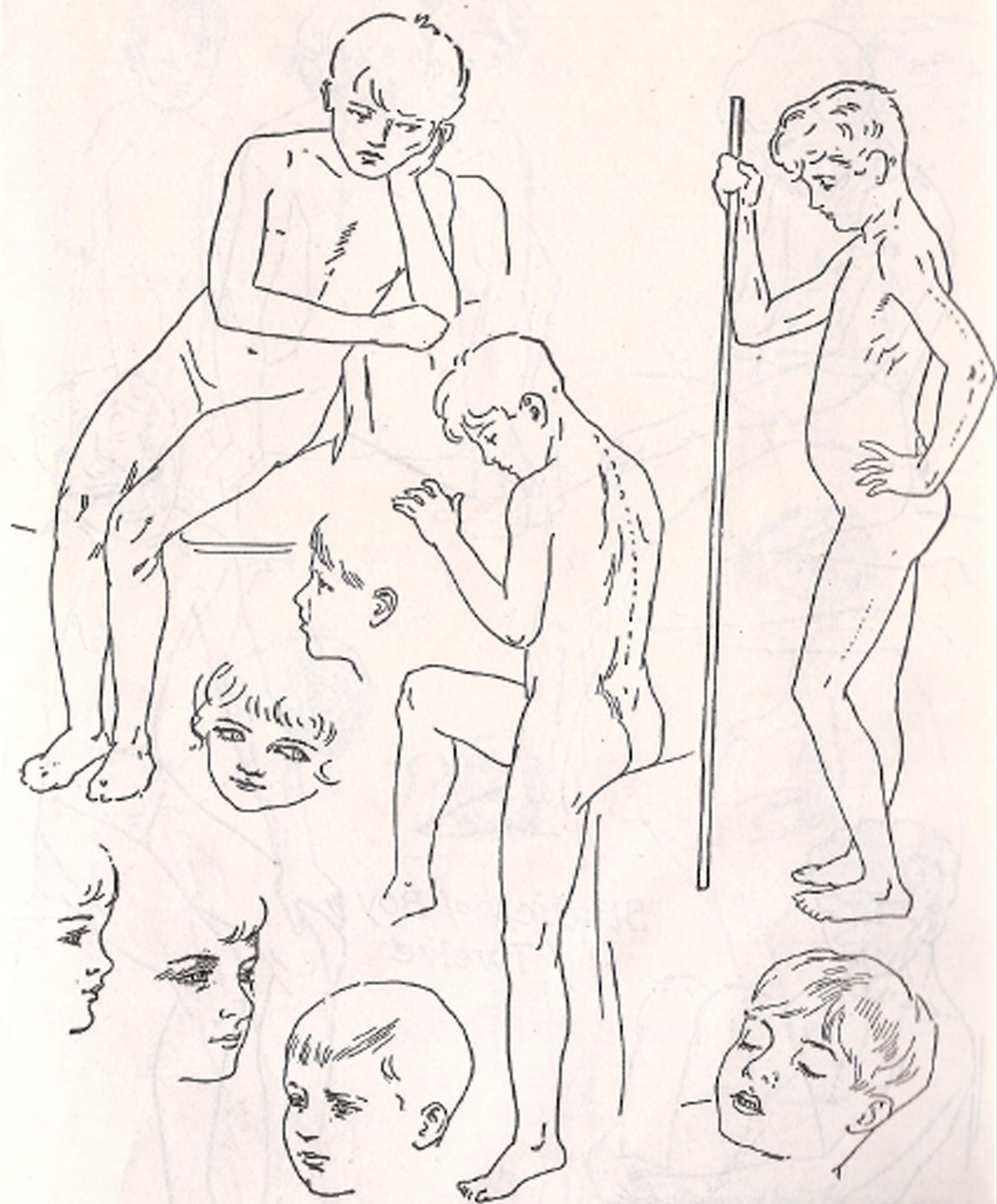
Sketches


Victor Rava





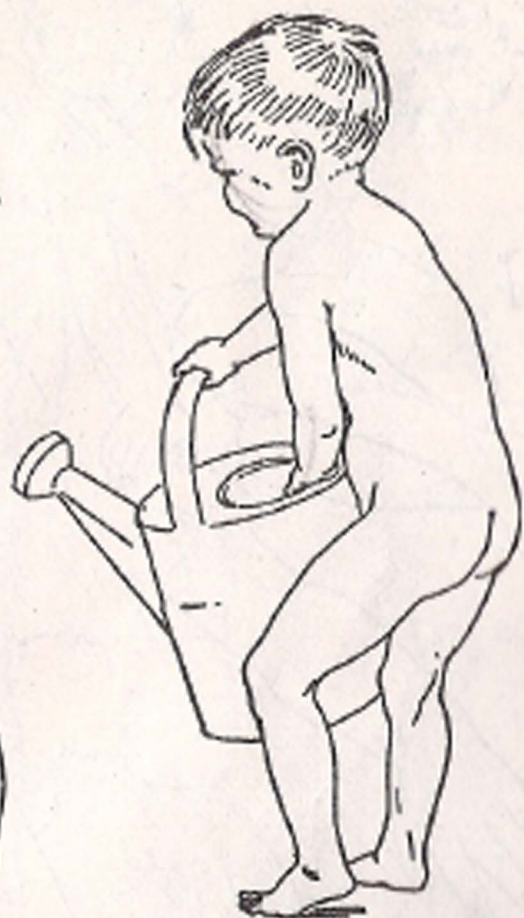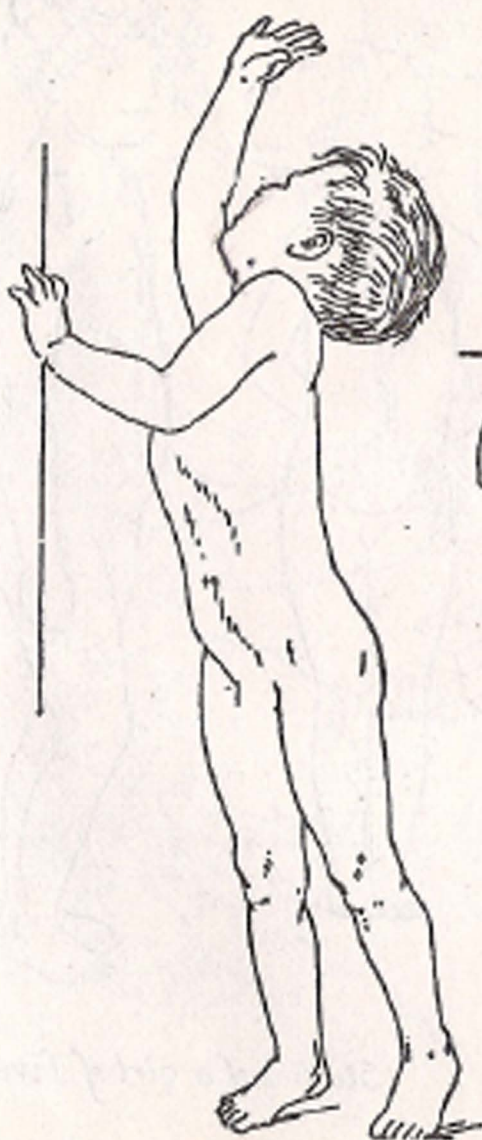
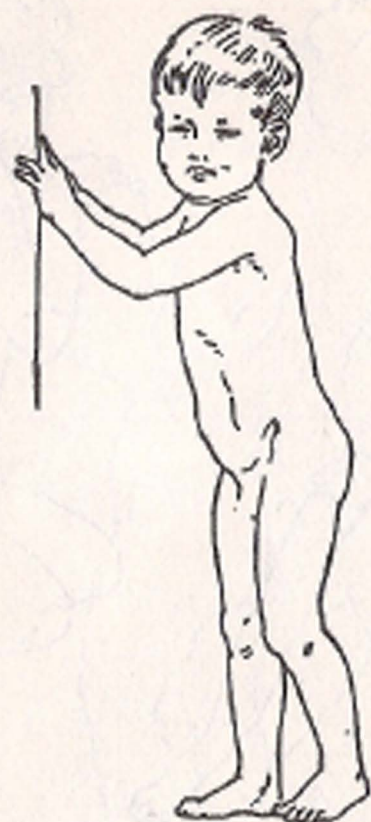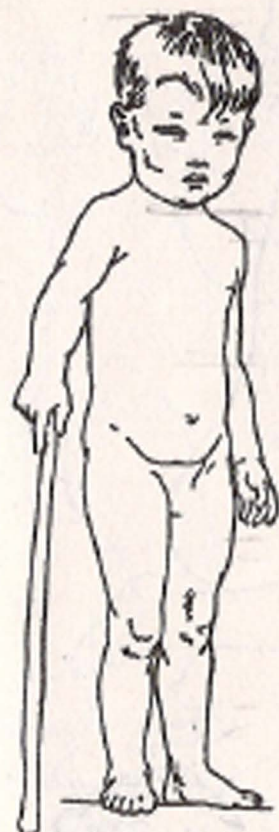
*Twenty-five minute sketches*



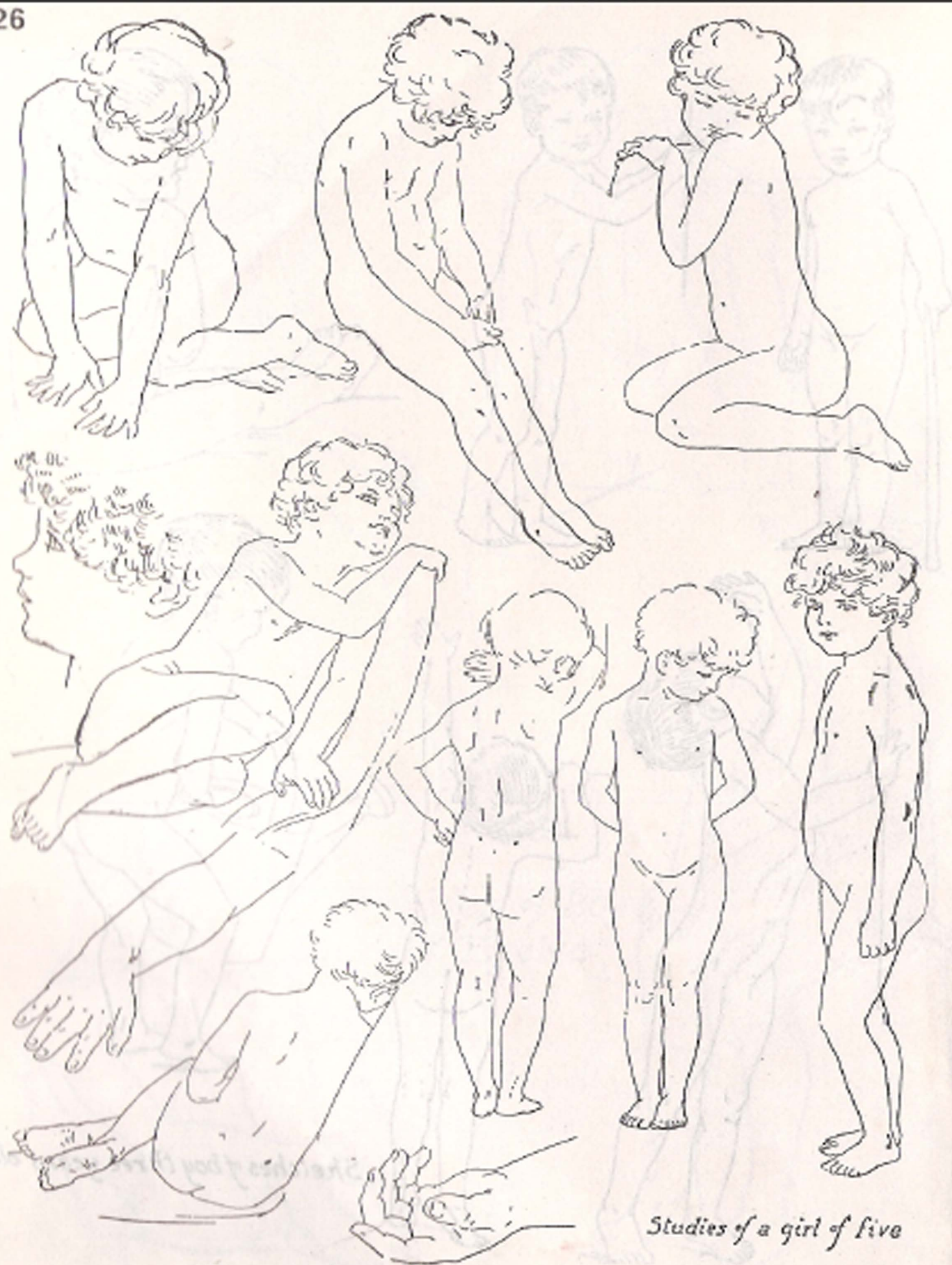

*Studies of Boy  
of Twelve*






*Sketches of boy three years old*



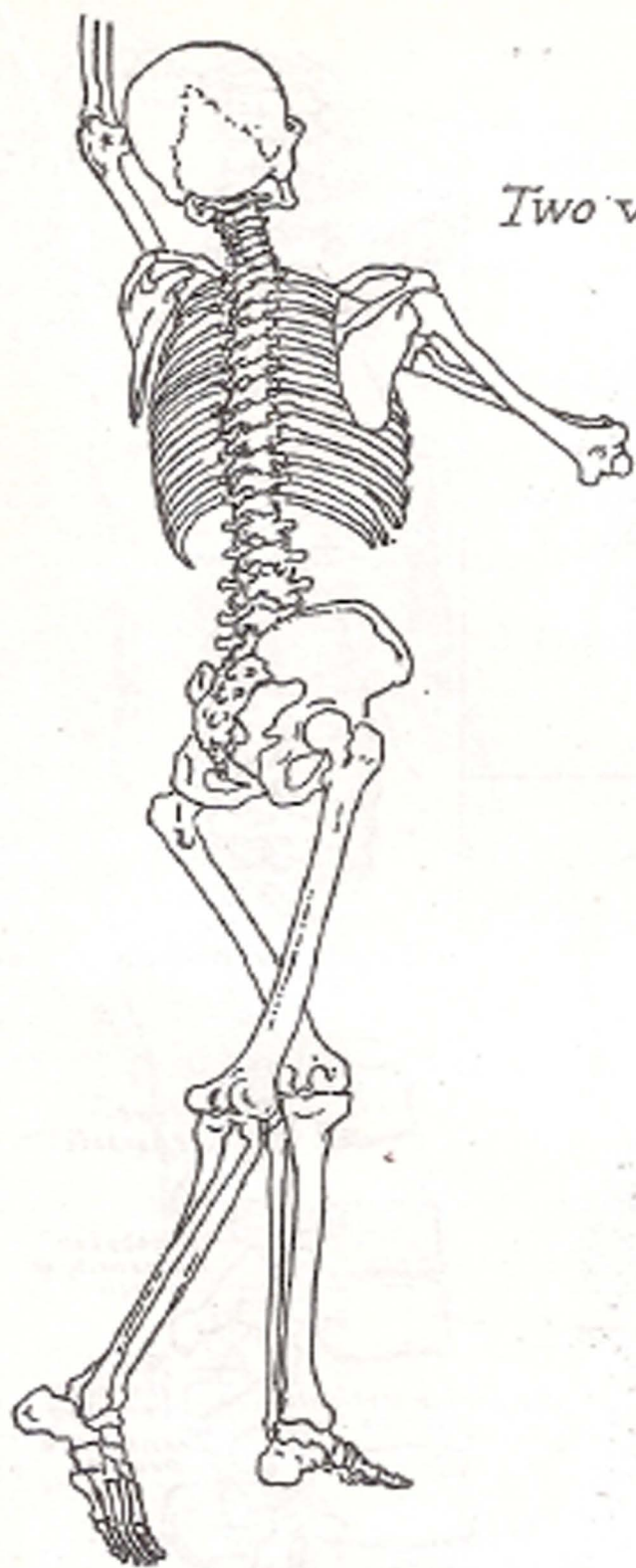
*Studies of a girl of five*



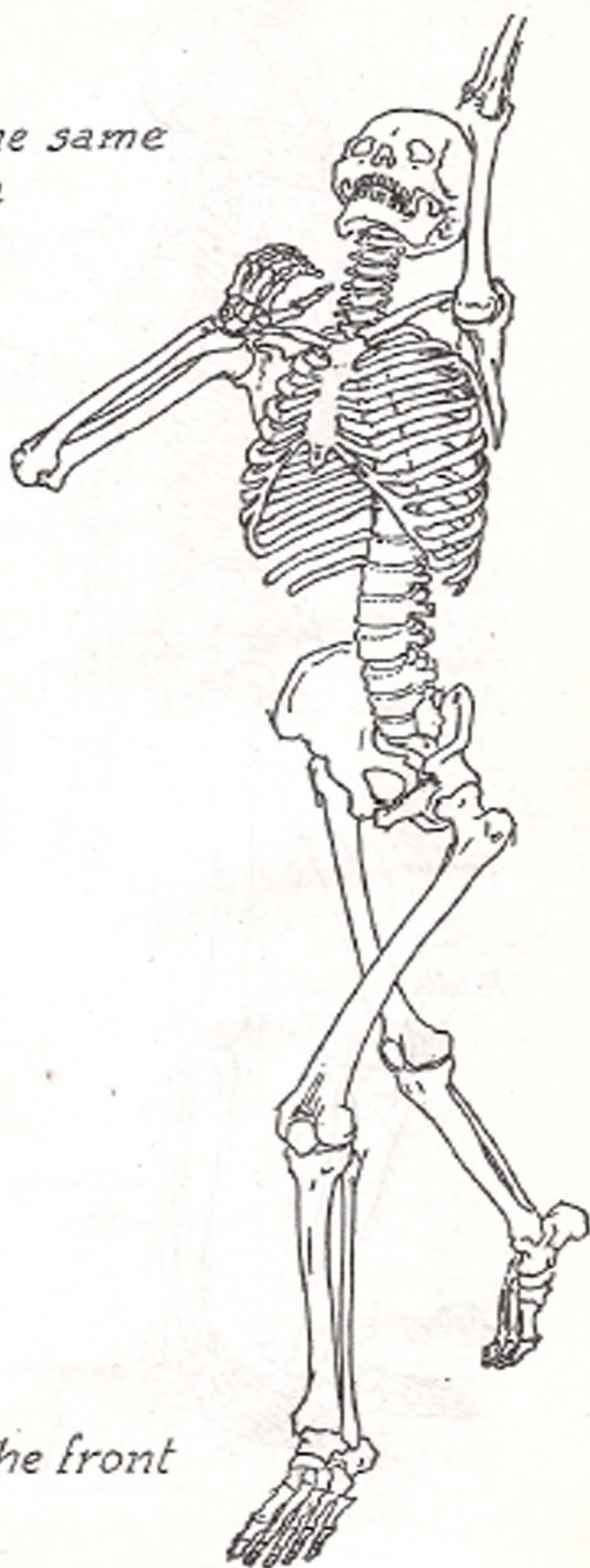
Curve of infant spine



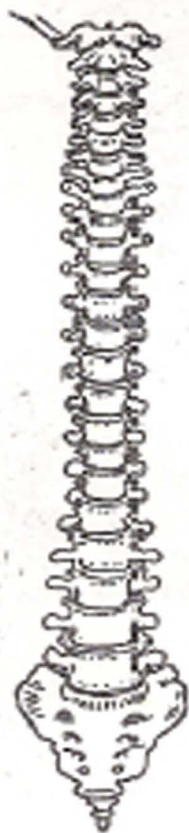PART II  
THE SKELETON

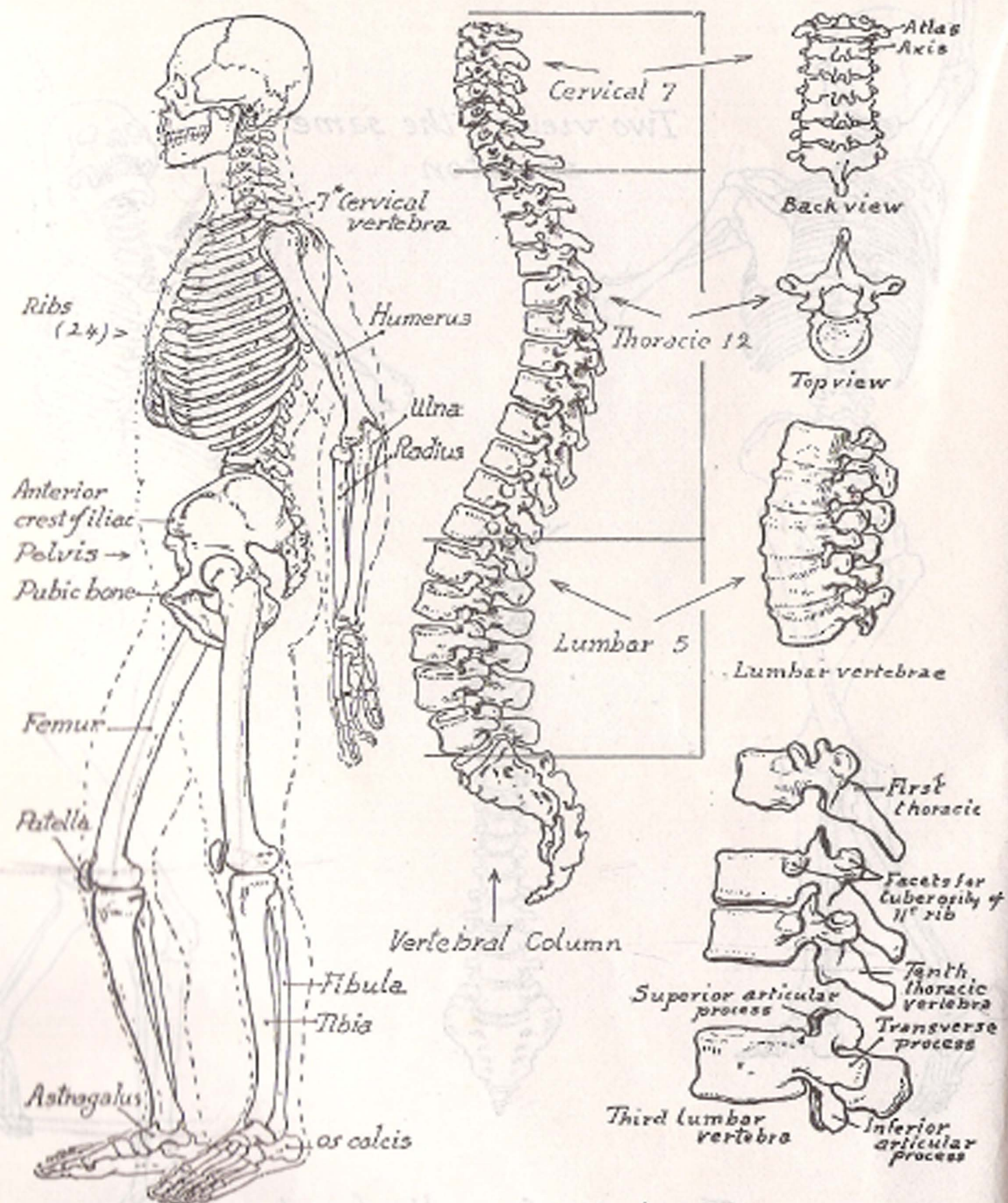


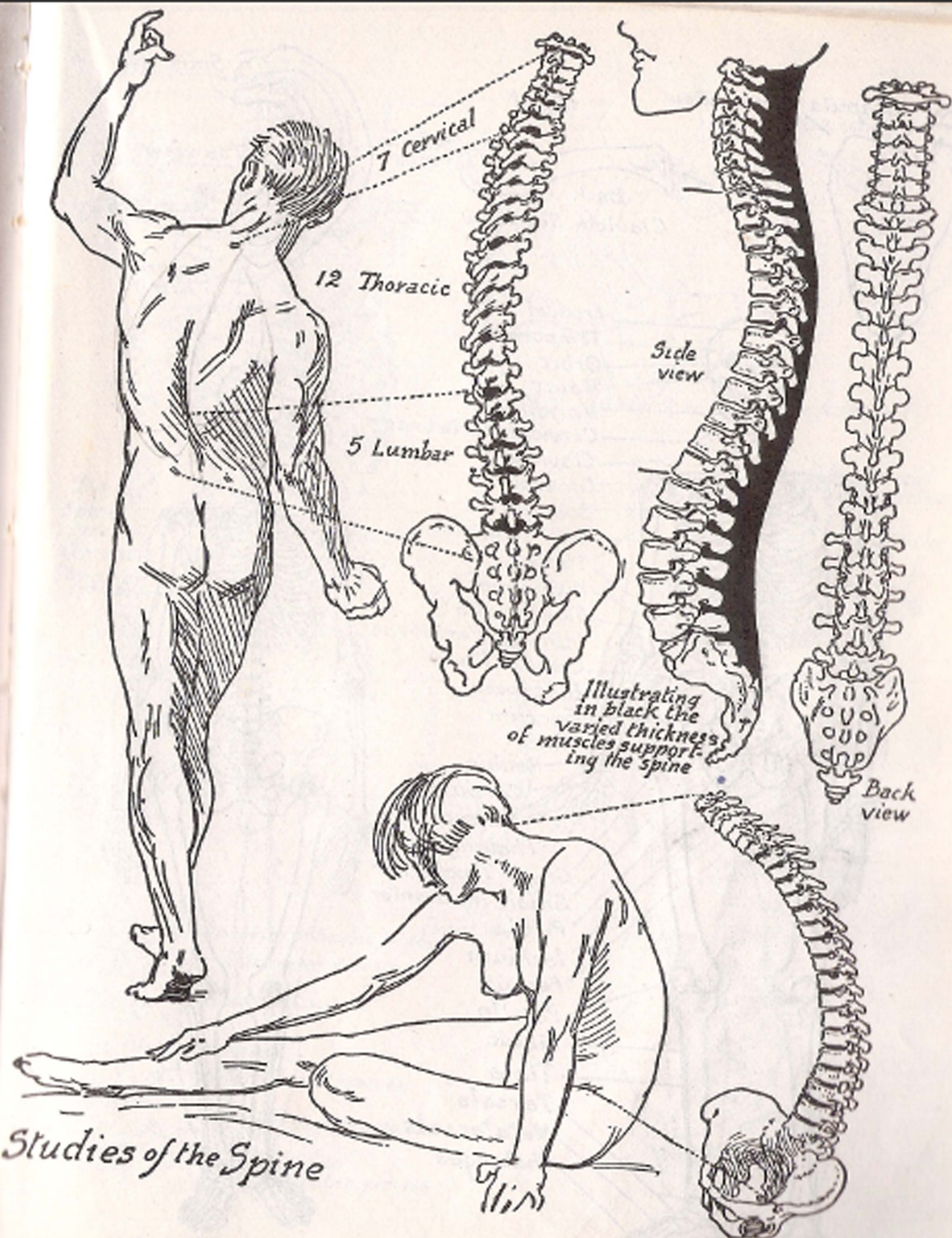
*Two views of the same  
skeleton*



*The spine from the front*







7 Cervical

12 Thoracic

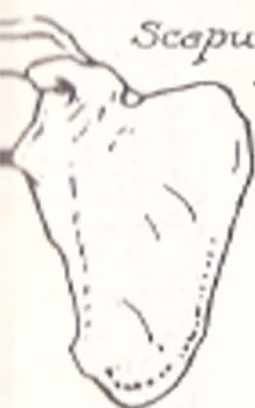5 Lumbar

Side view

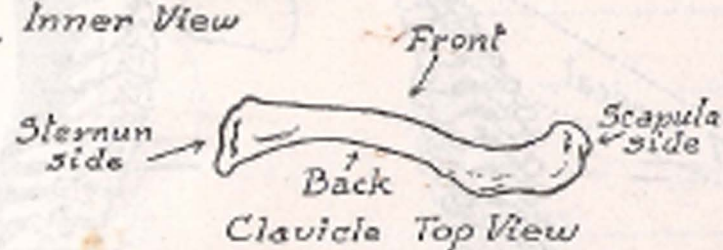Back view

Illustrating in black the varied thickness of muscles supporting the spine

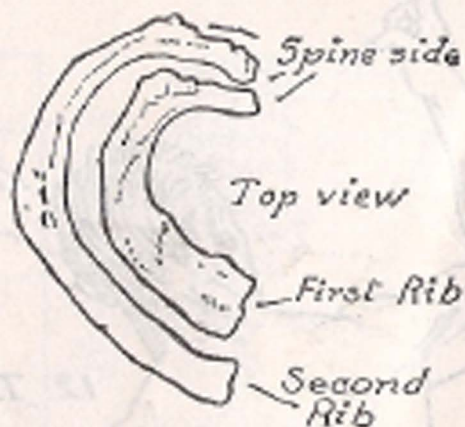
Studies of the Spine



Scapula Inner View



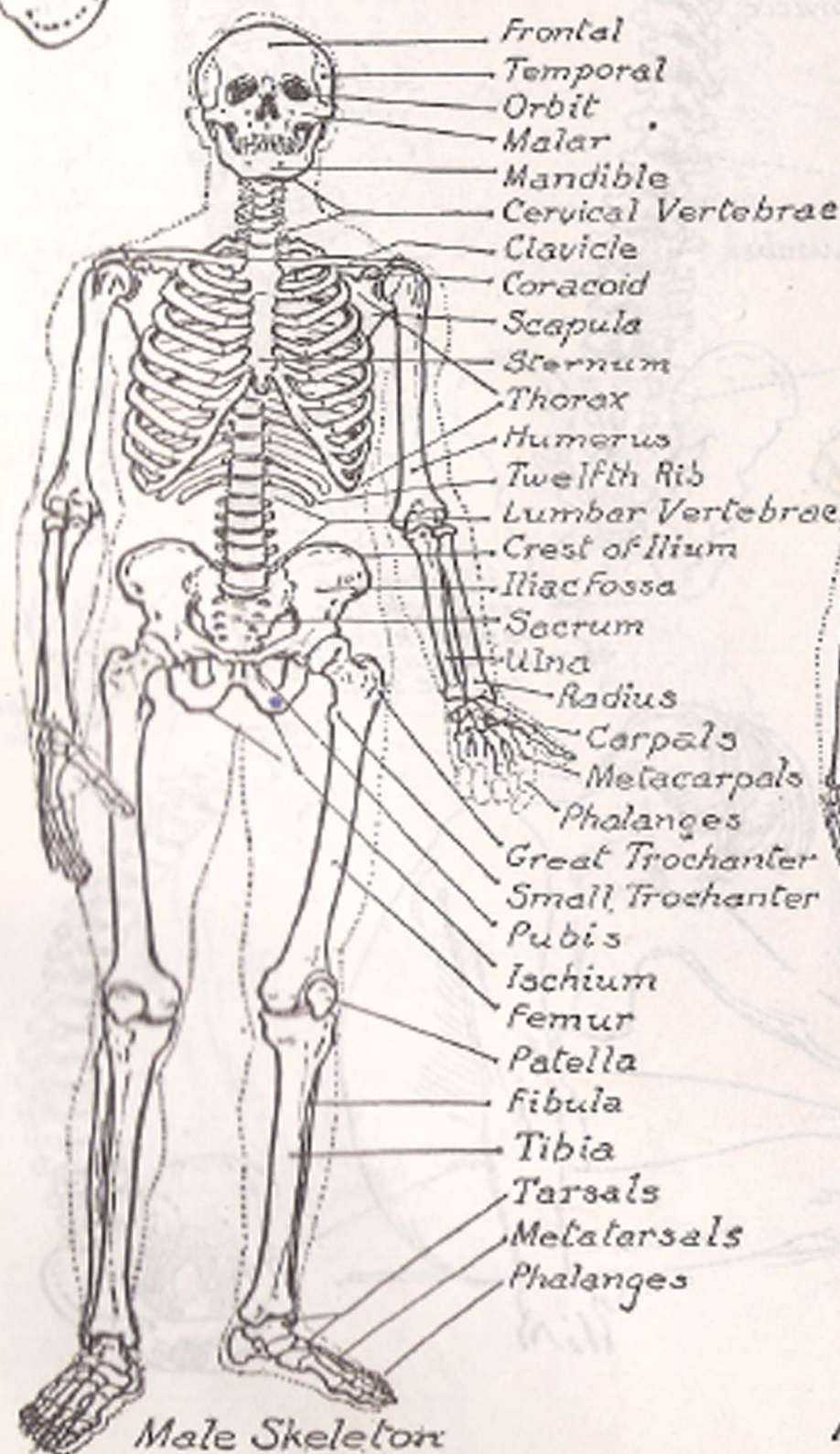
Clavicle Top View



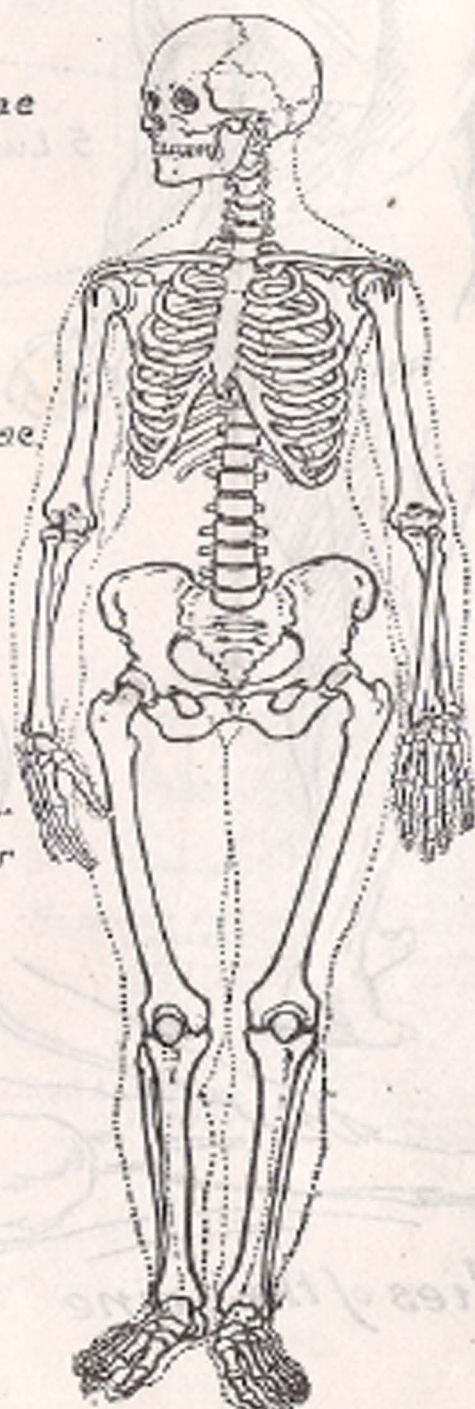
Top view

First Rib

Second Rib



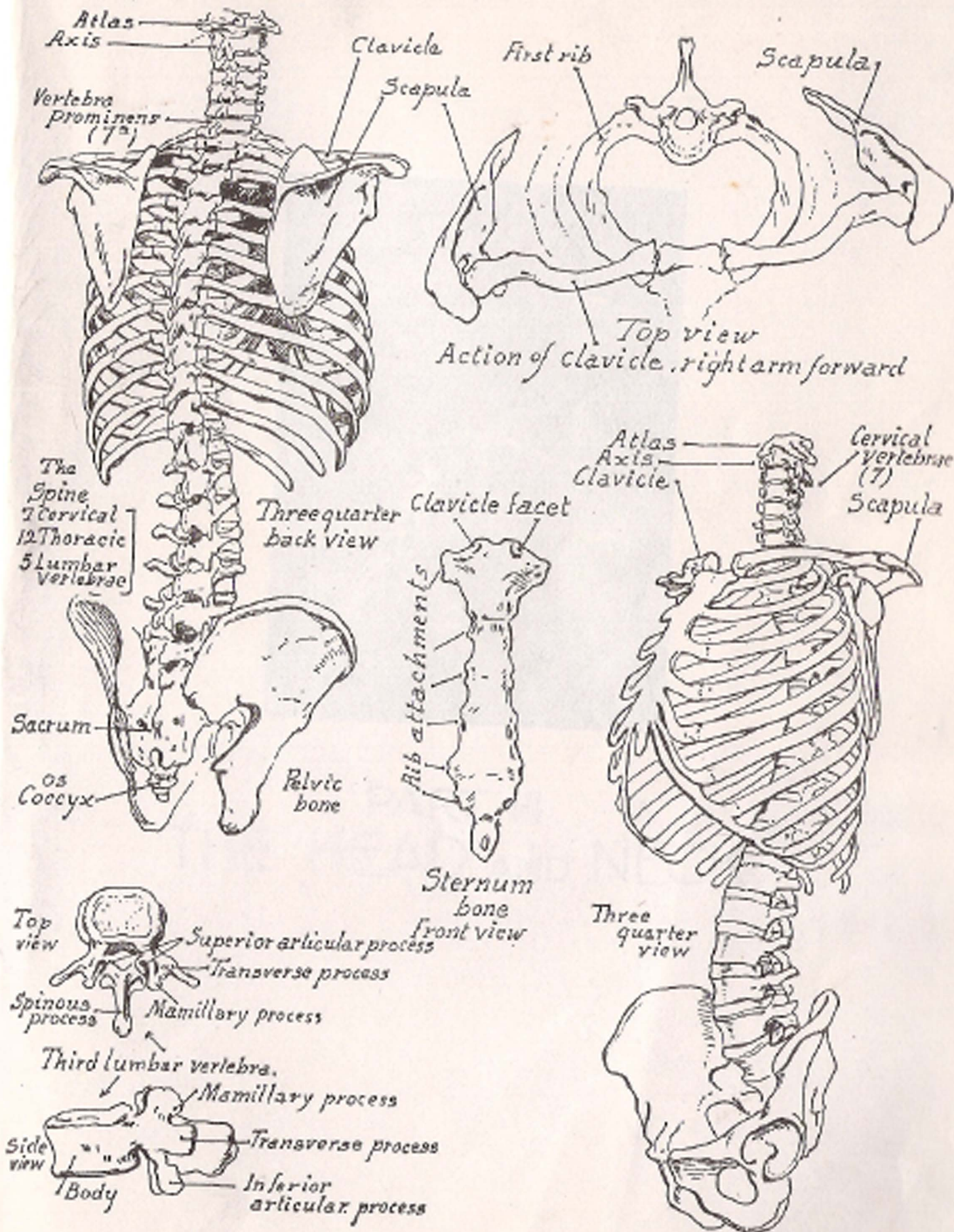
Male Skeleton



Female Skeleton

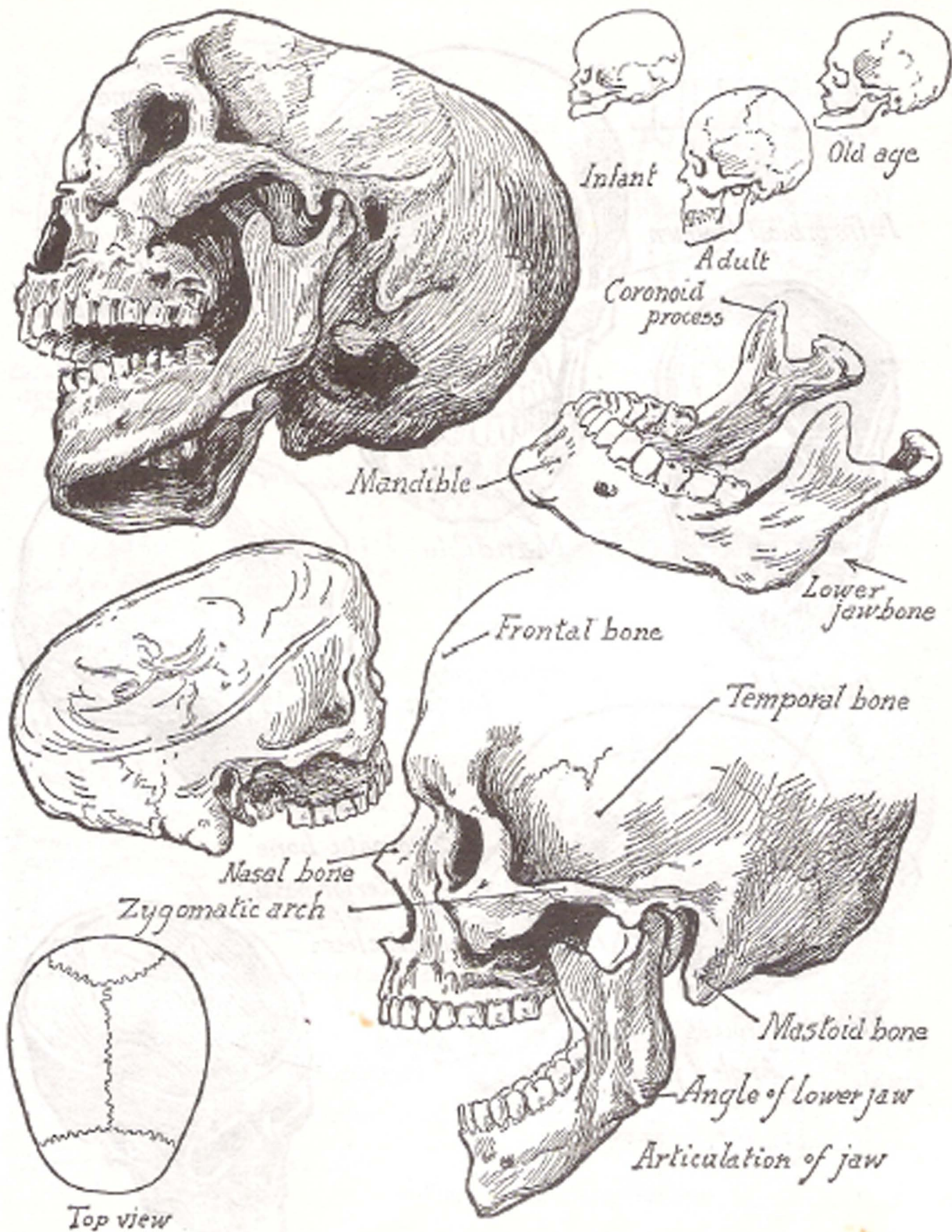
- Frontal
- Temporal
- Orbit
- Malar
- Mandible
- Cervical Vertebrae
- Clavicle
- Coracoid
- Scapula
- Sternum
- Thorax
- Humerus
- Twelfth Rib
- Lumbar Vertebrae
- Crest of Ilium
- Iliac Fossa
- Sacrum
- Ulna
- Radius
- Carpals
- Metacarpals
- Phalanges
- Great Trochanter
- Small Trochanter
- Pubis
- Ischium
- Femur
- Patella
- Fibula
- Tibia
- Tarsals
- Metatarsals
- Phalanges



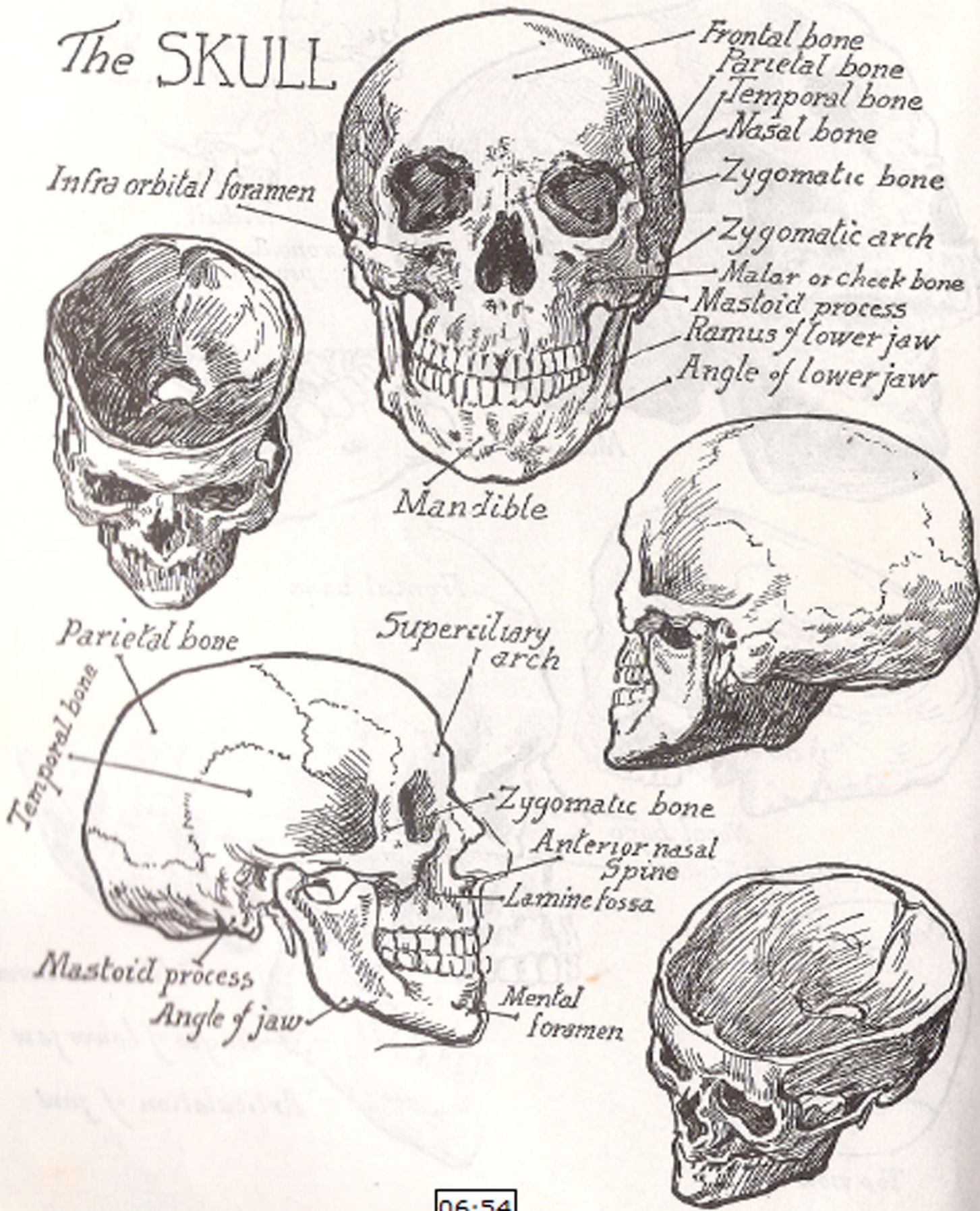


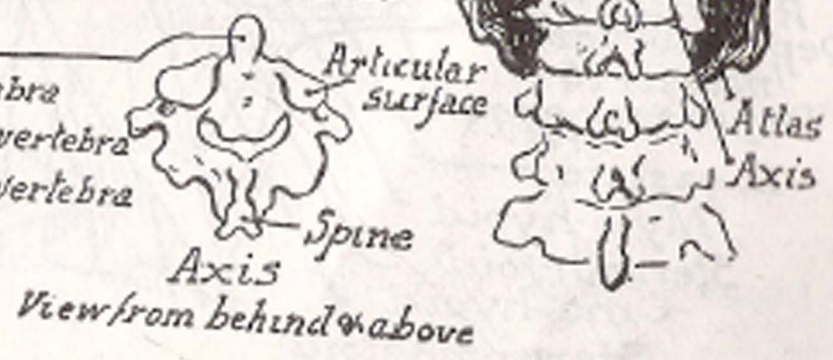
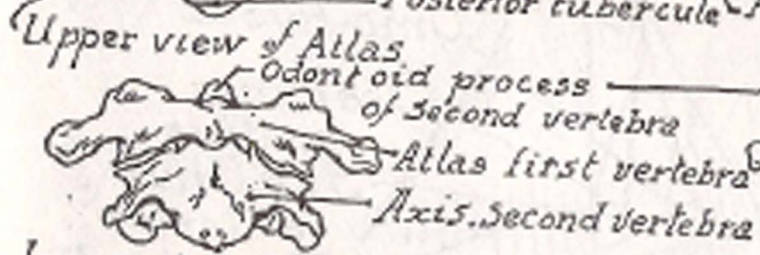
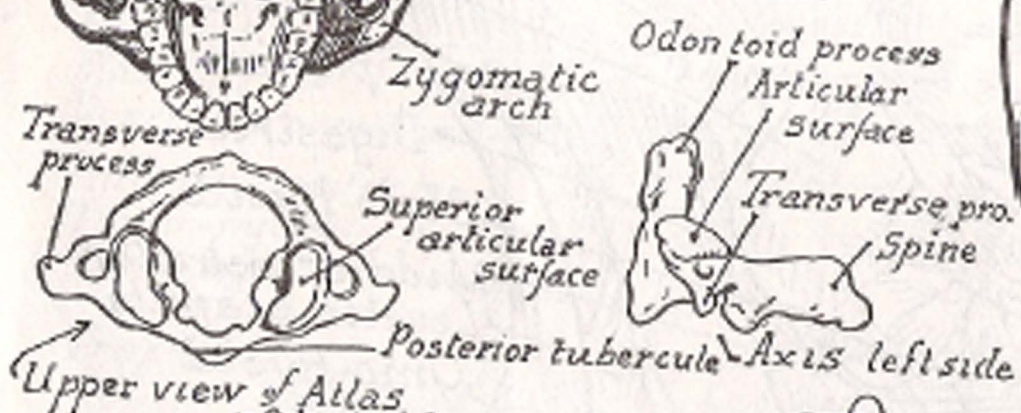
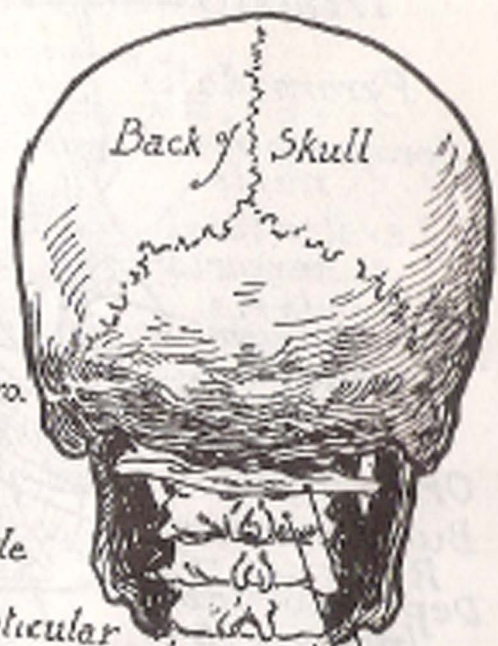
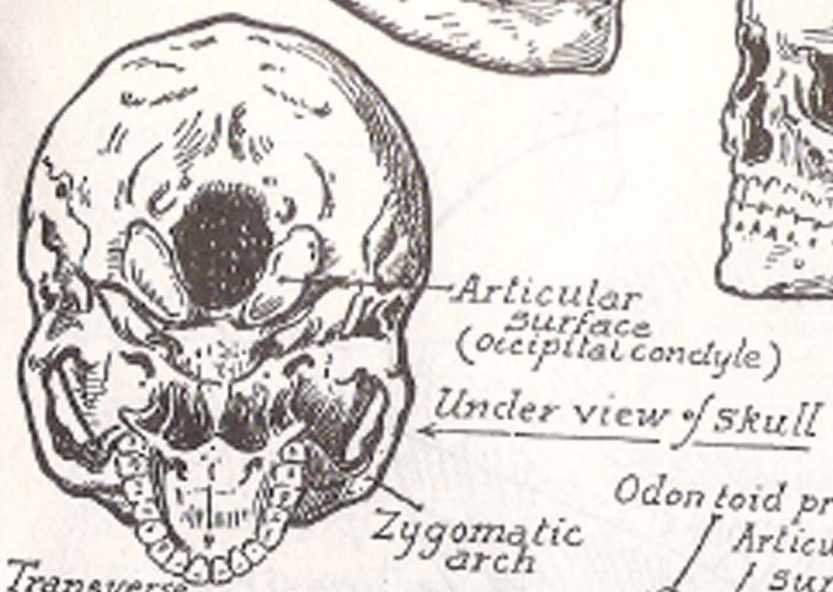
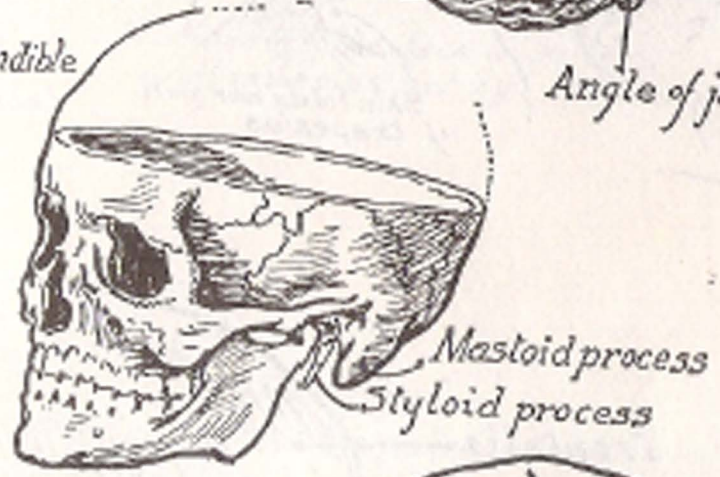
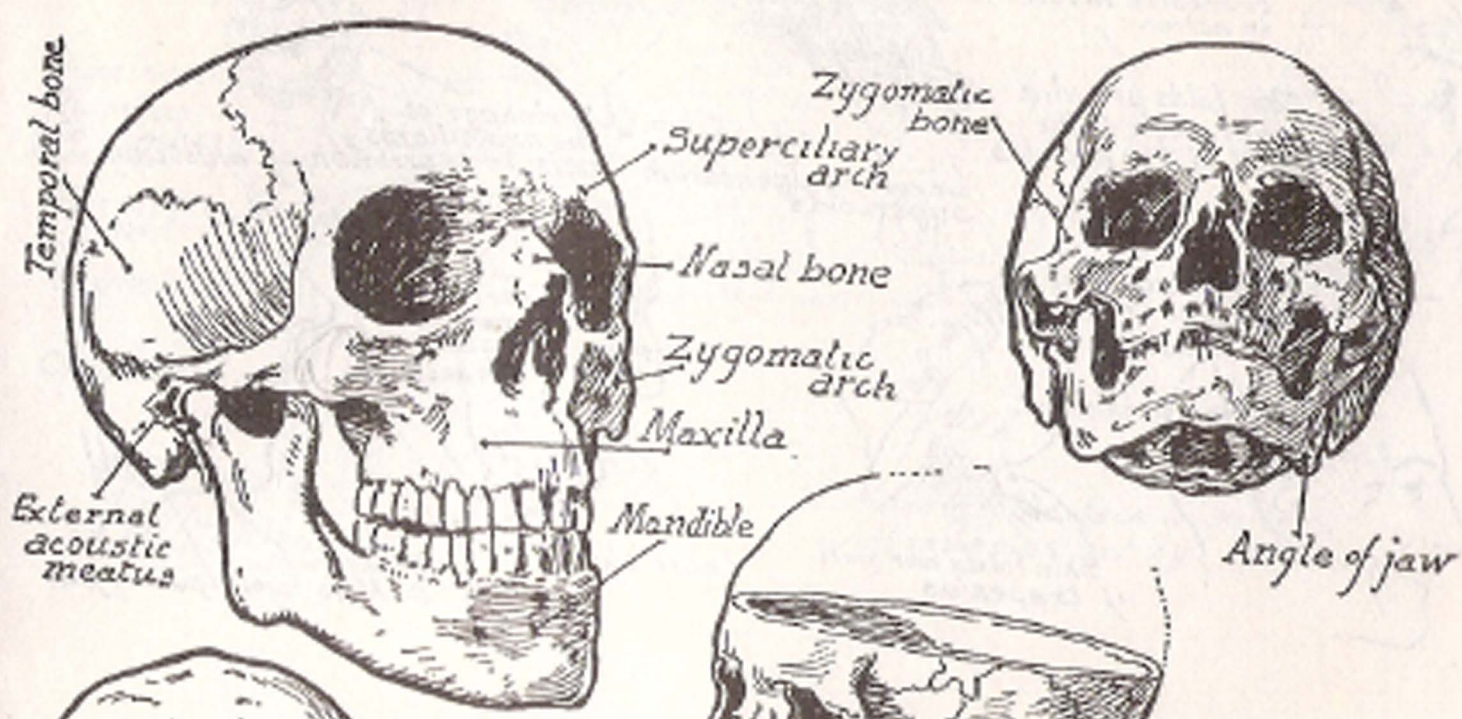


PART III  
THE HEAD AND NECK

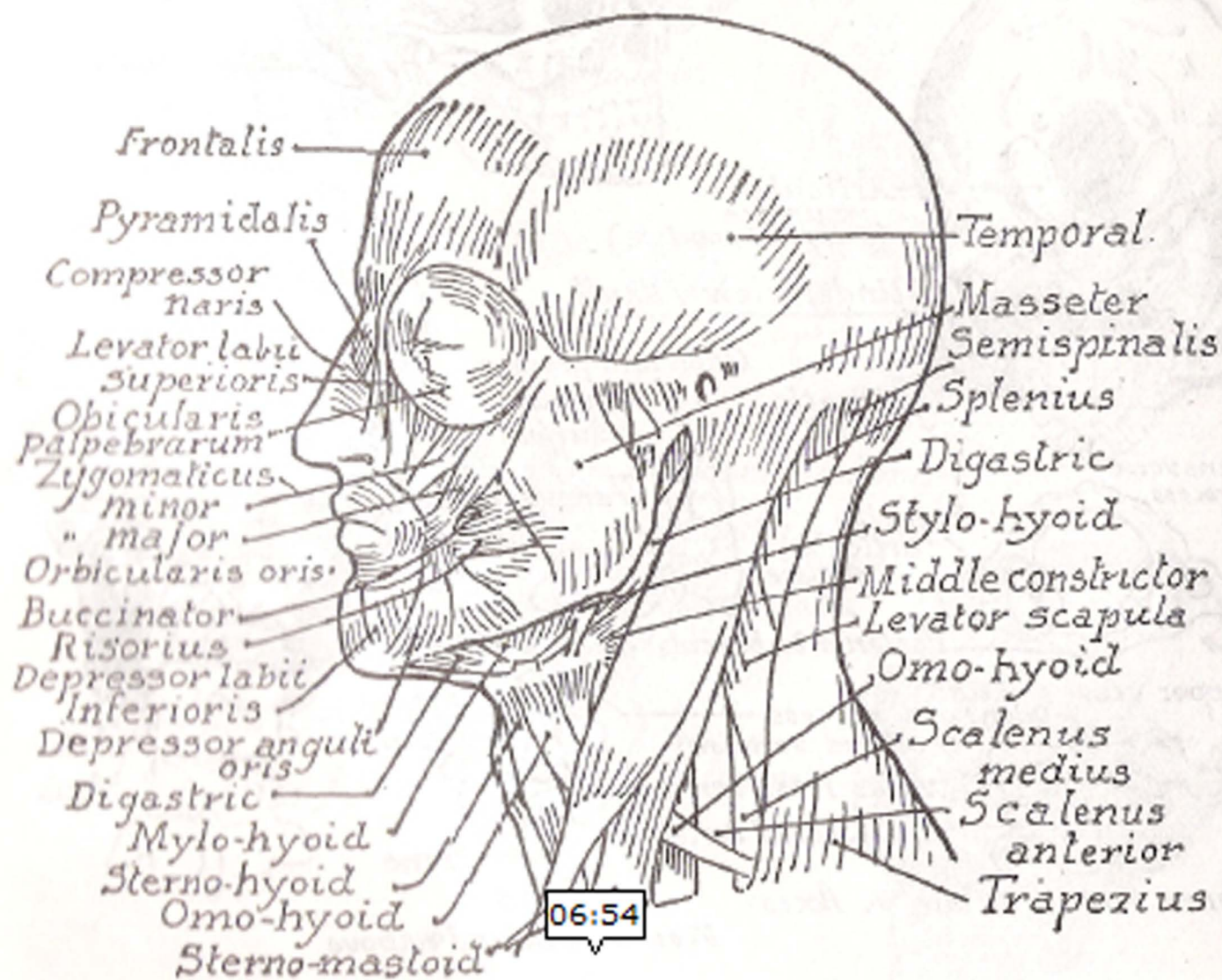
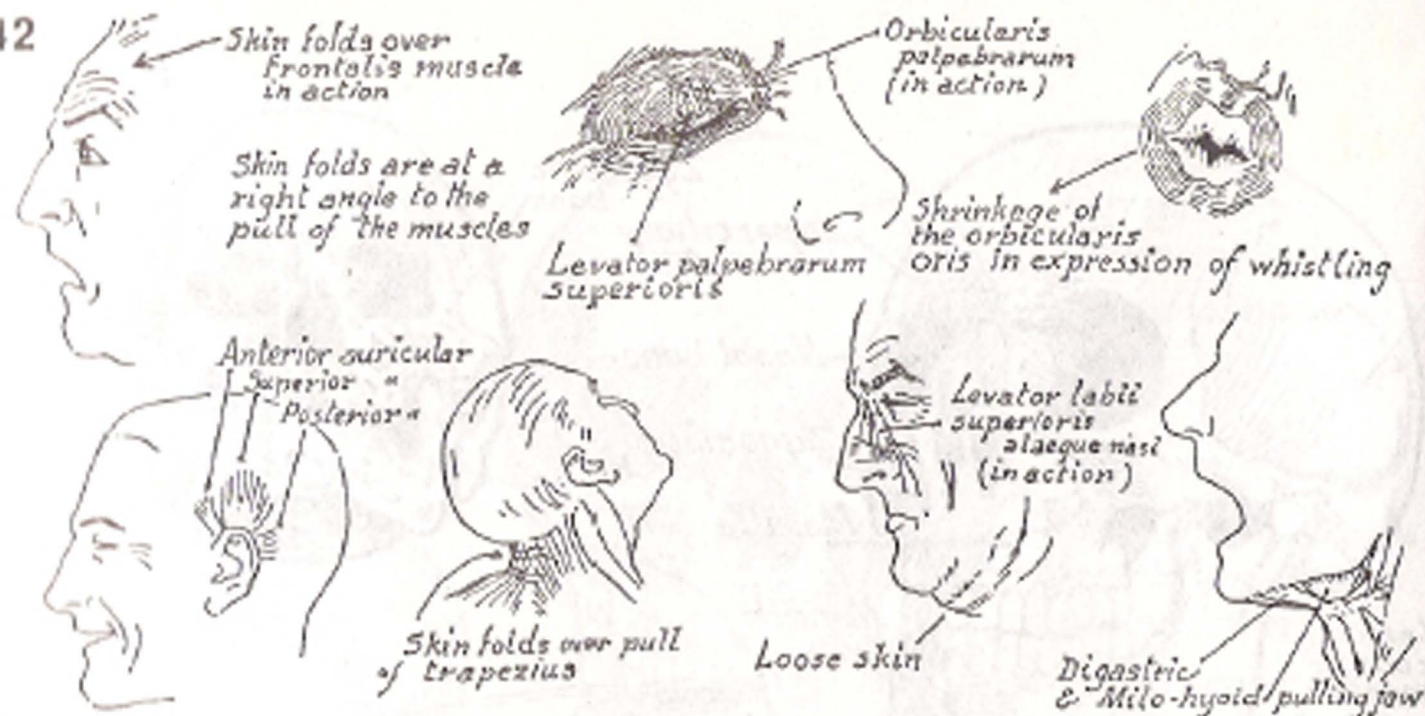


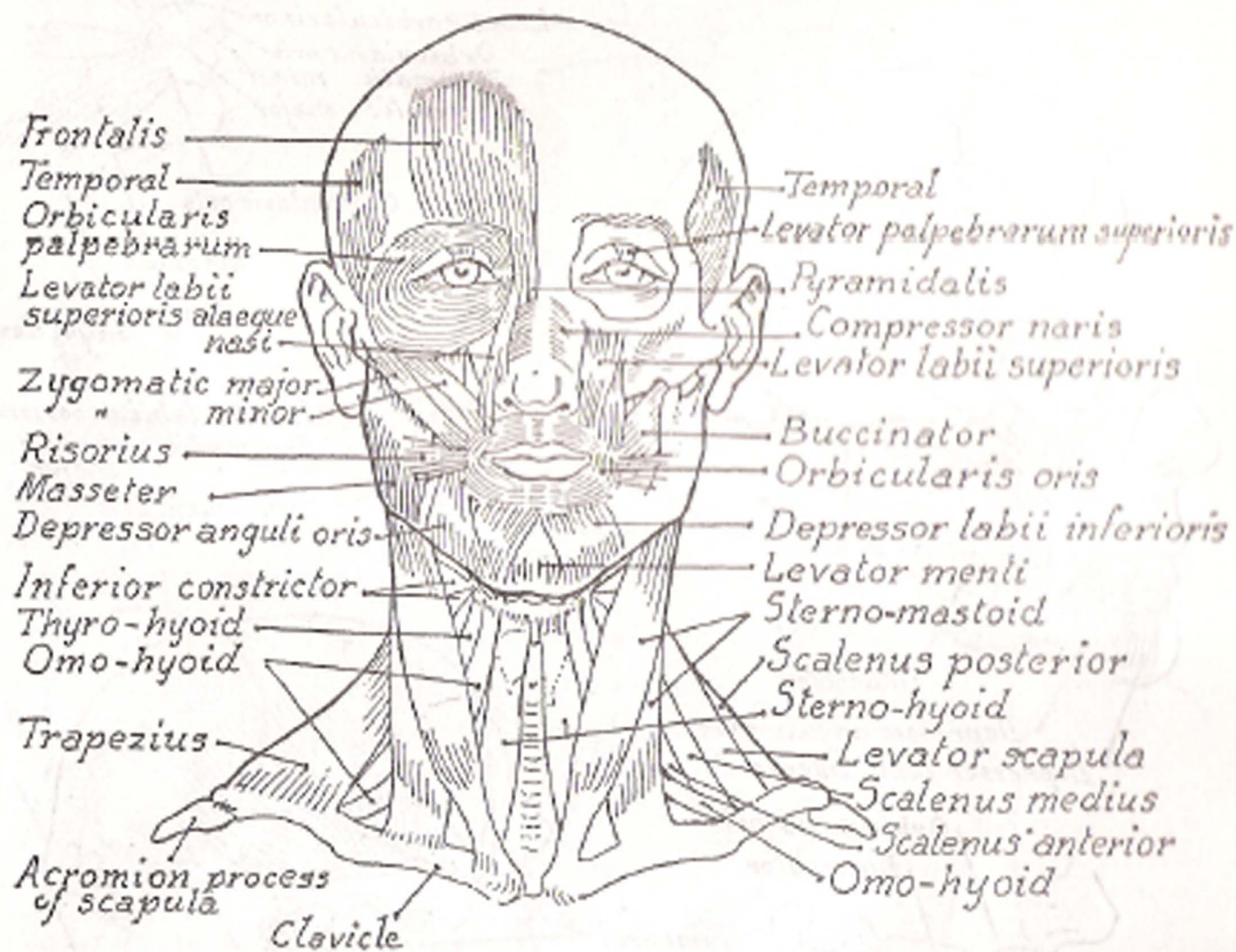
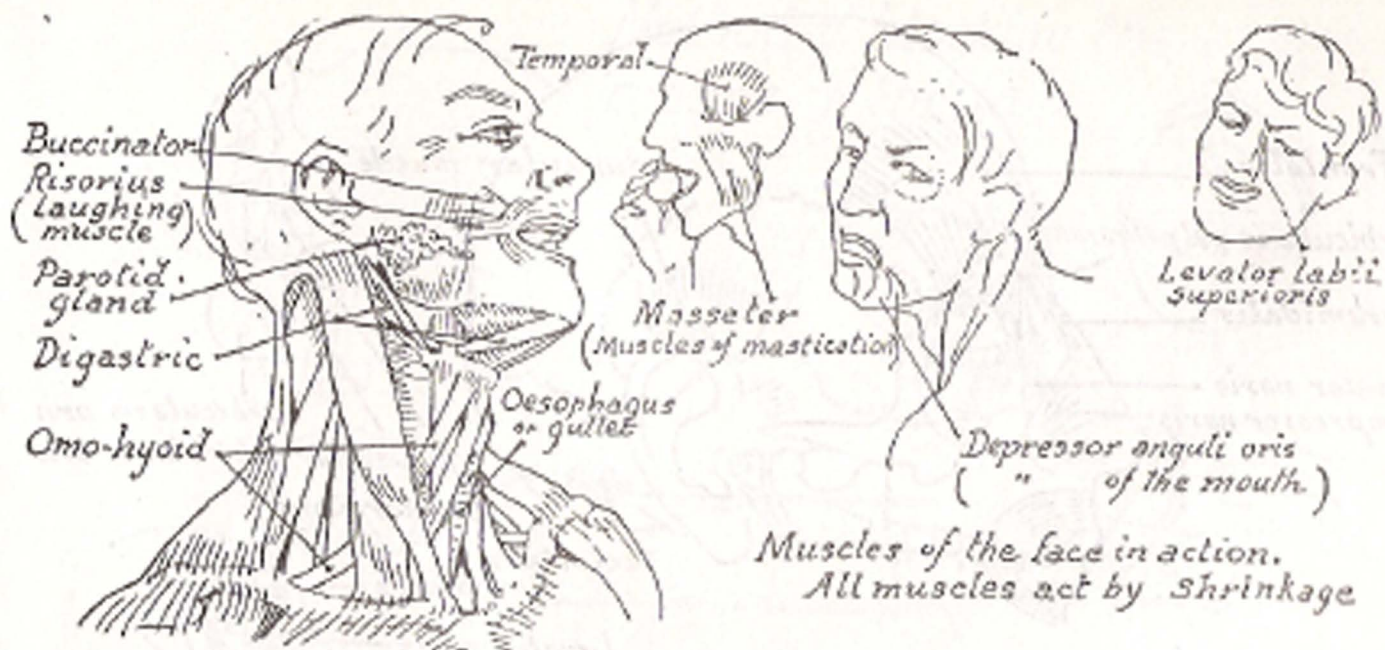
# The SKULL



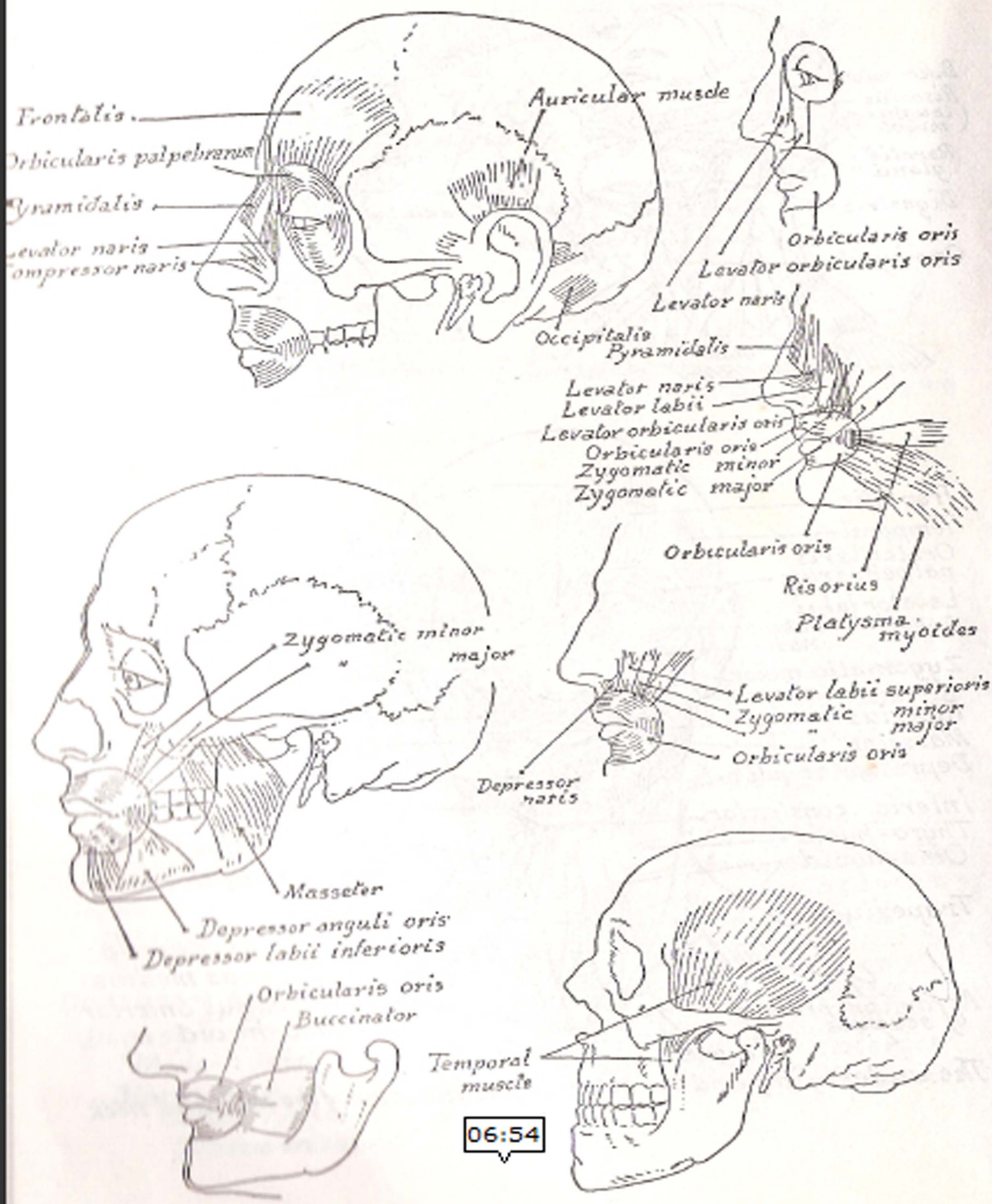


Inner view of Atlas & Axis






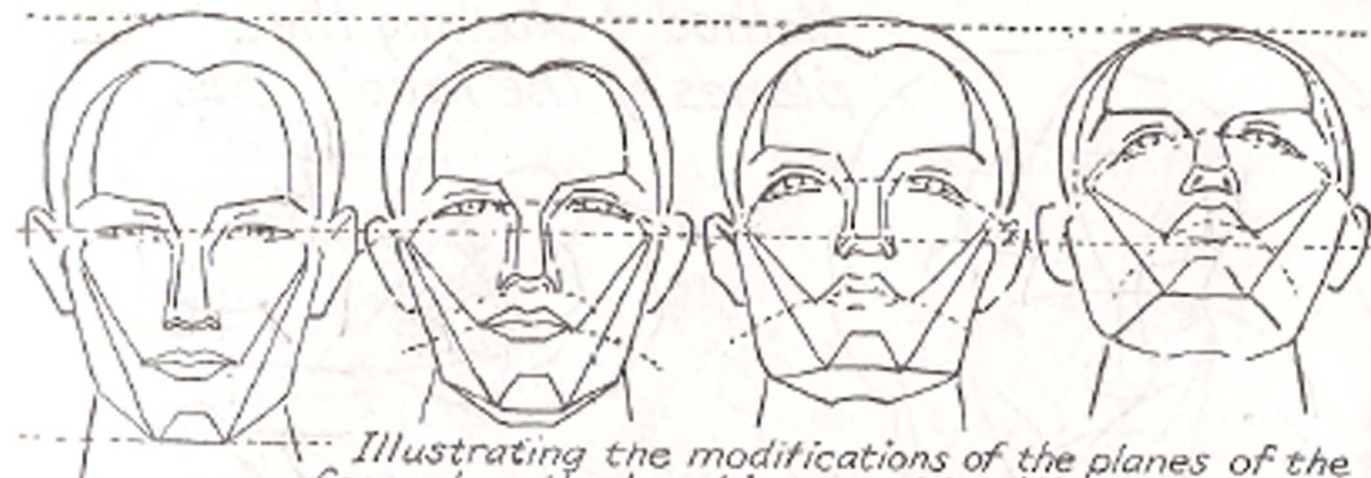
The underlying and the superficial muscles of the face and neck



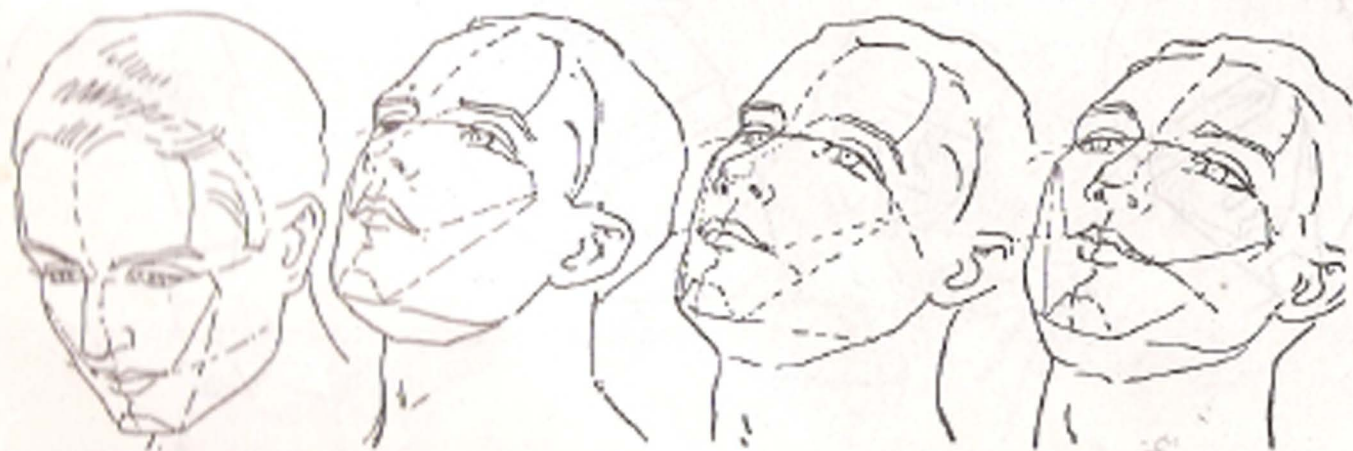
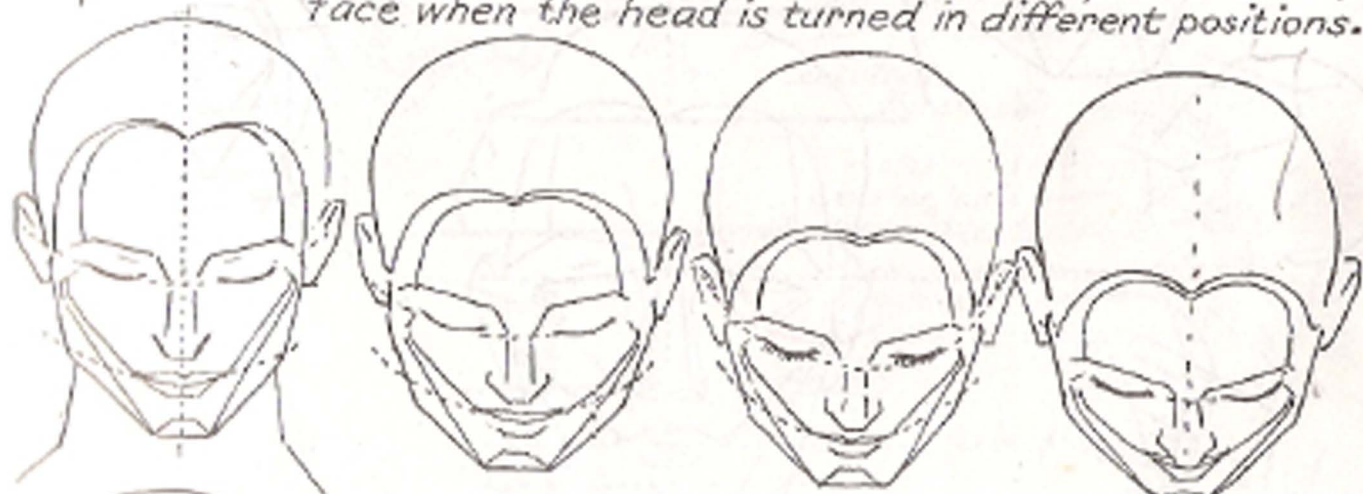


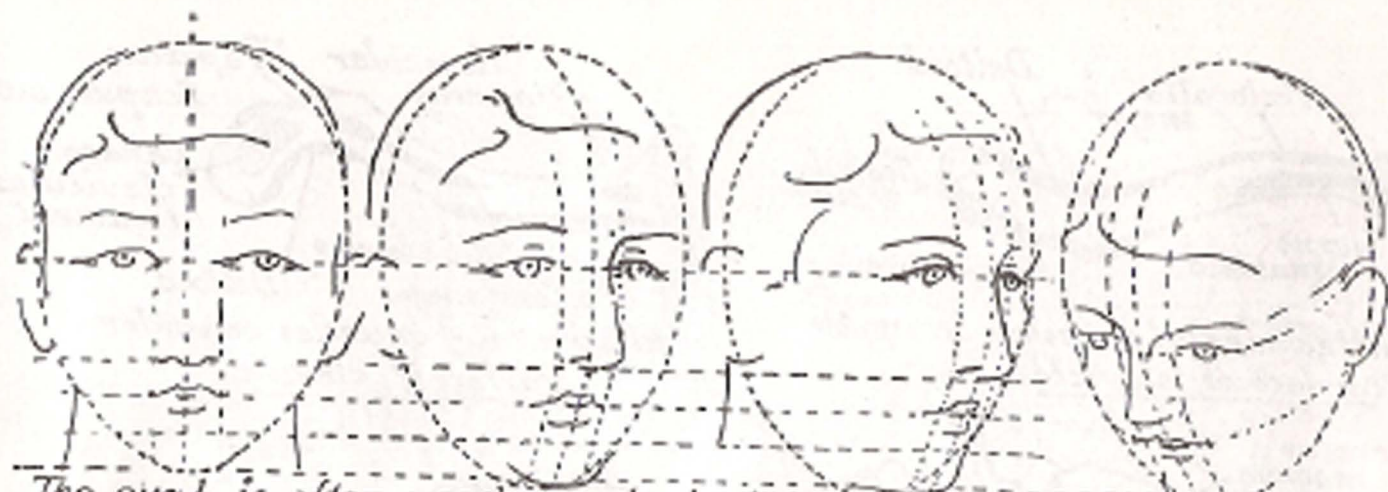Method of blocking the planes of the face



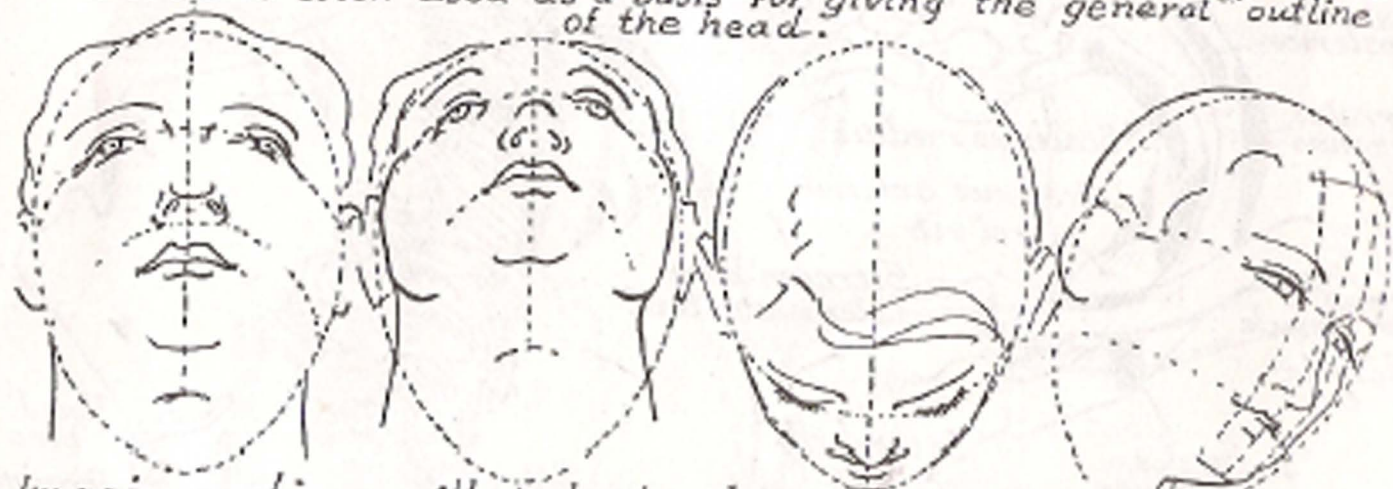

*Illustrating the modifications of the planes of the face when the head is turned in different positions.*





The oval is often used as a basis for giving the general outline of the head.

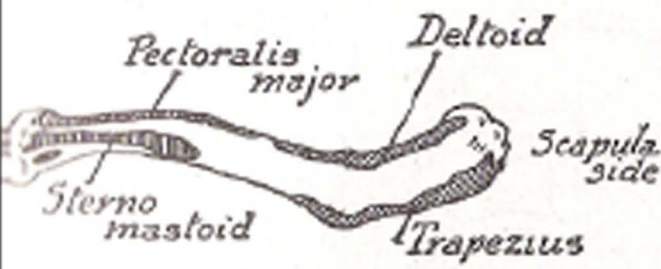


Imaginary lines will help to place the features in their proper relation and to give convexity to the head.

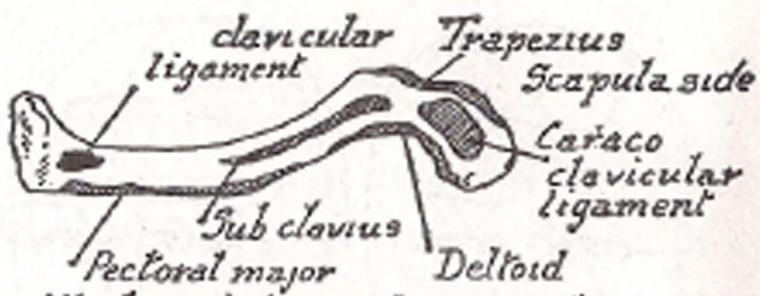


Showing changes in the relative proportions of features and skull at different ages. The nose gradually straightens, then lengthens, the ears lengthen, the eyes are placed higher.

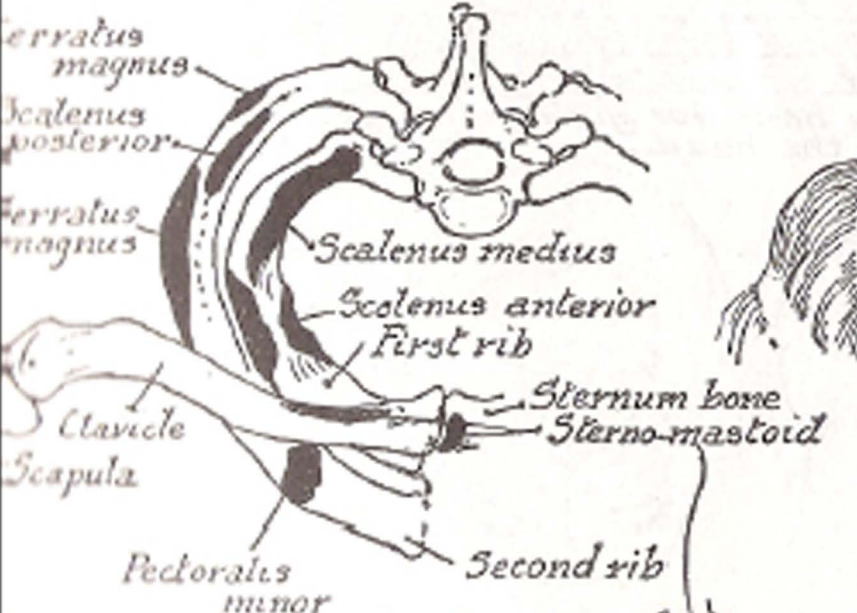




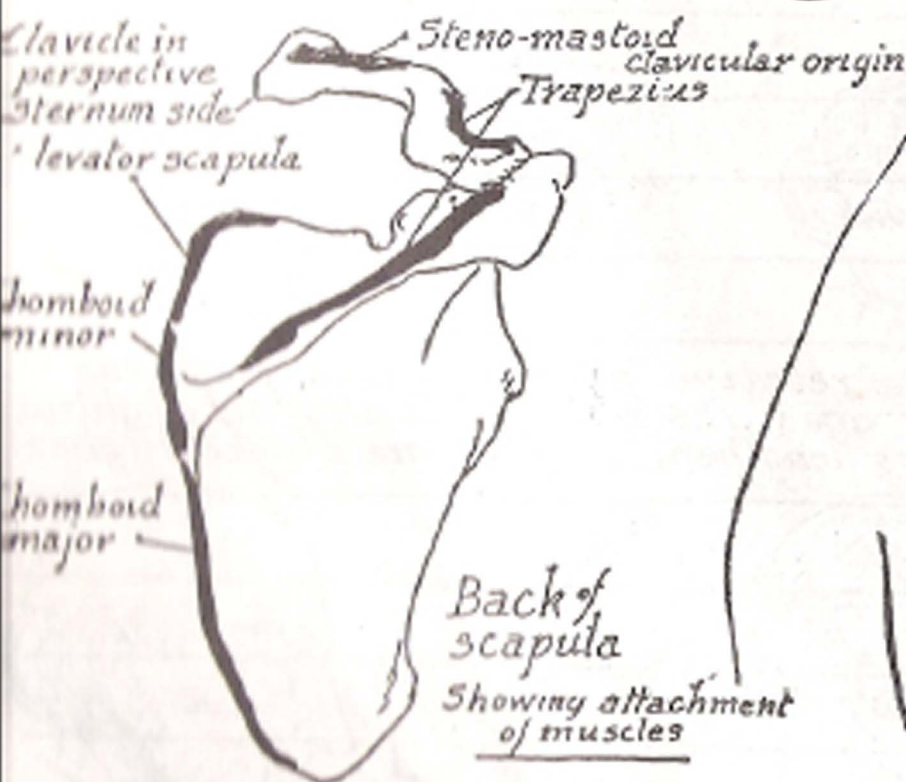
Attachment of muscles on upper surface of clavicle



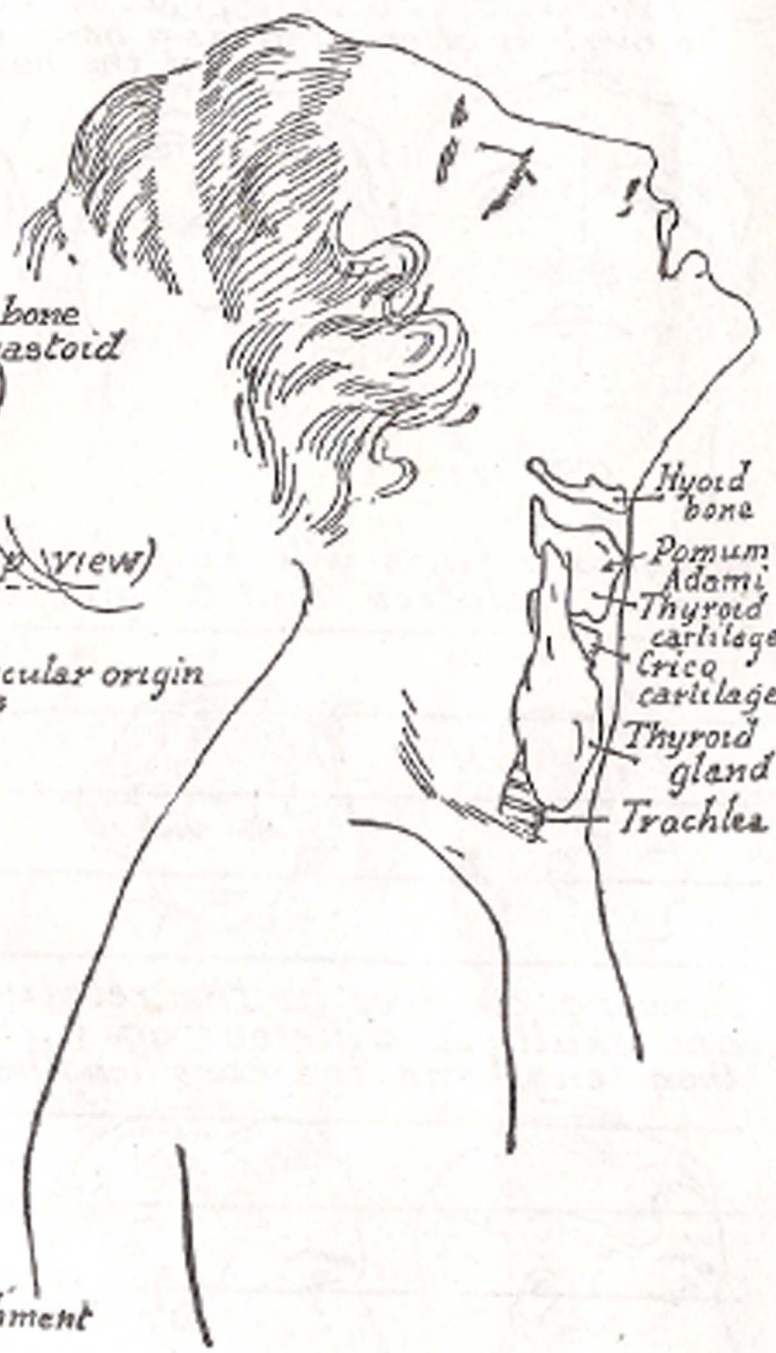
Attachment of muscles on under surface of clavicle



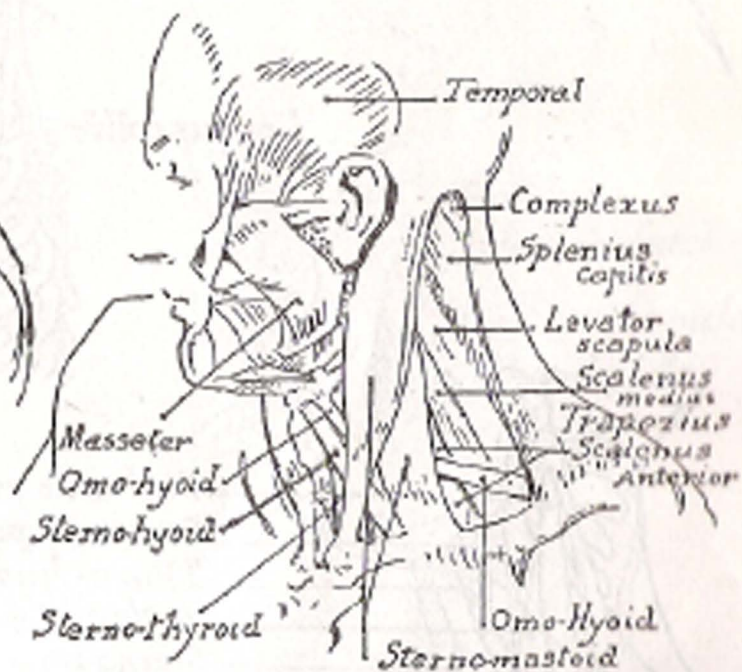
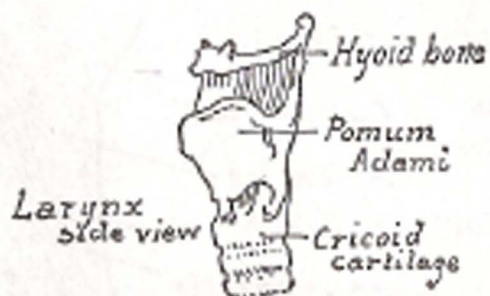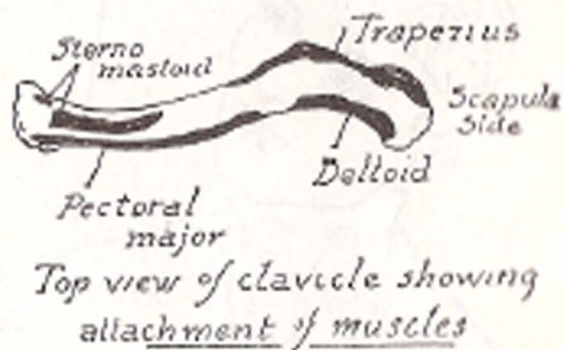
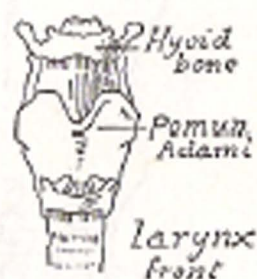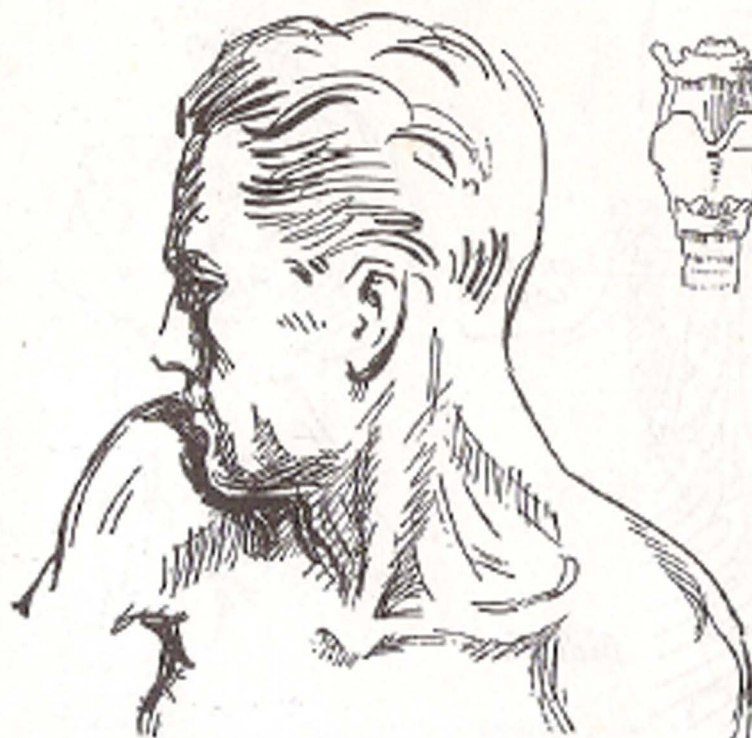
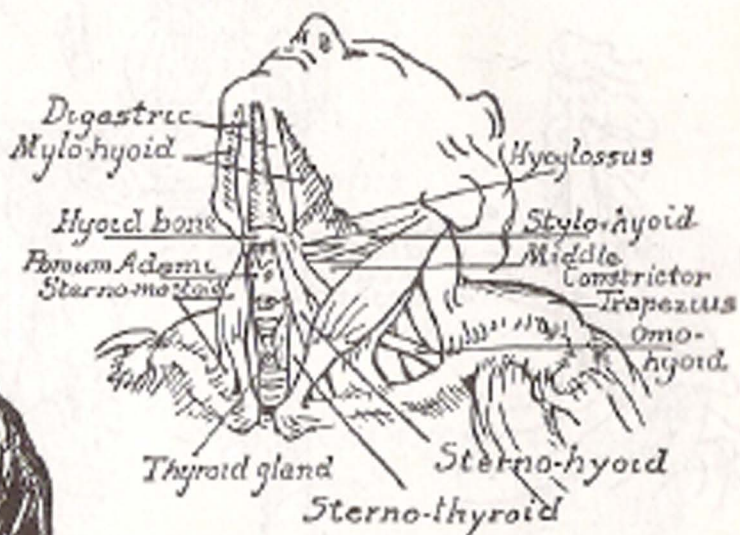
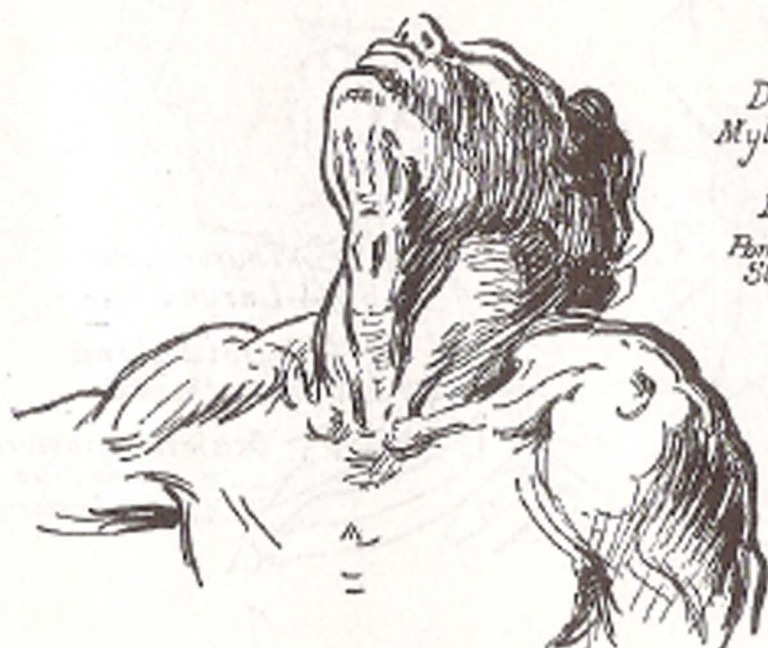
Attachments of muscles (Top view)

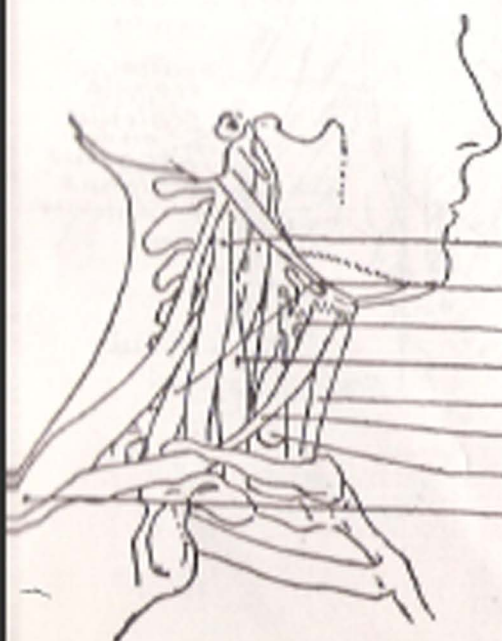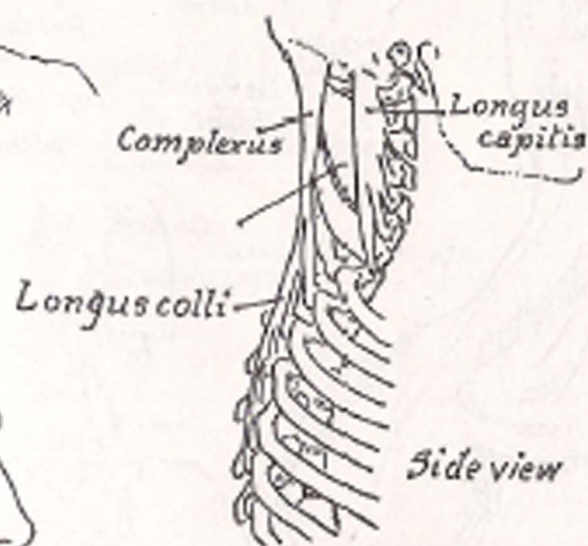
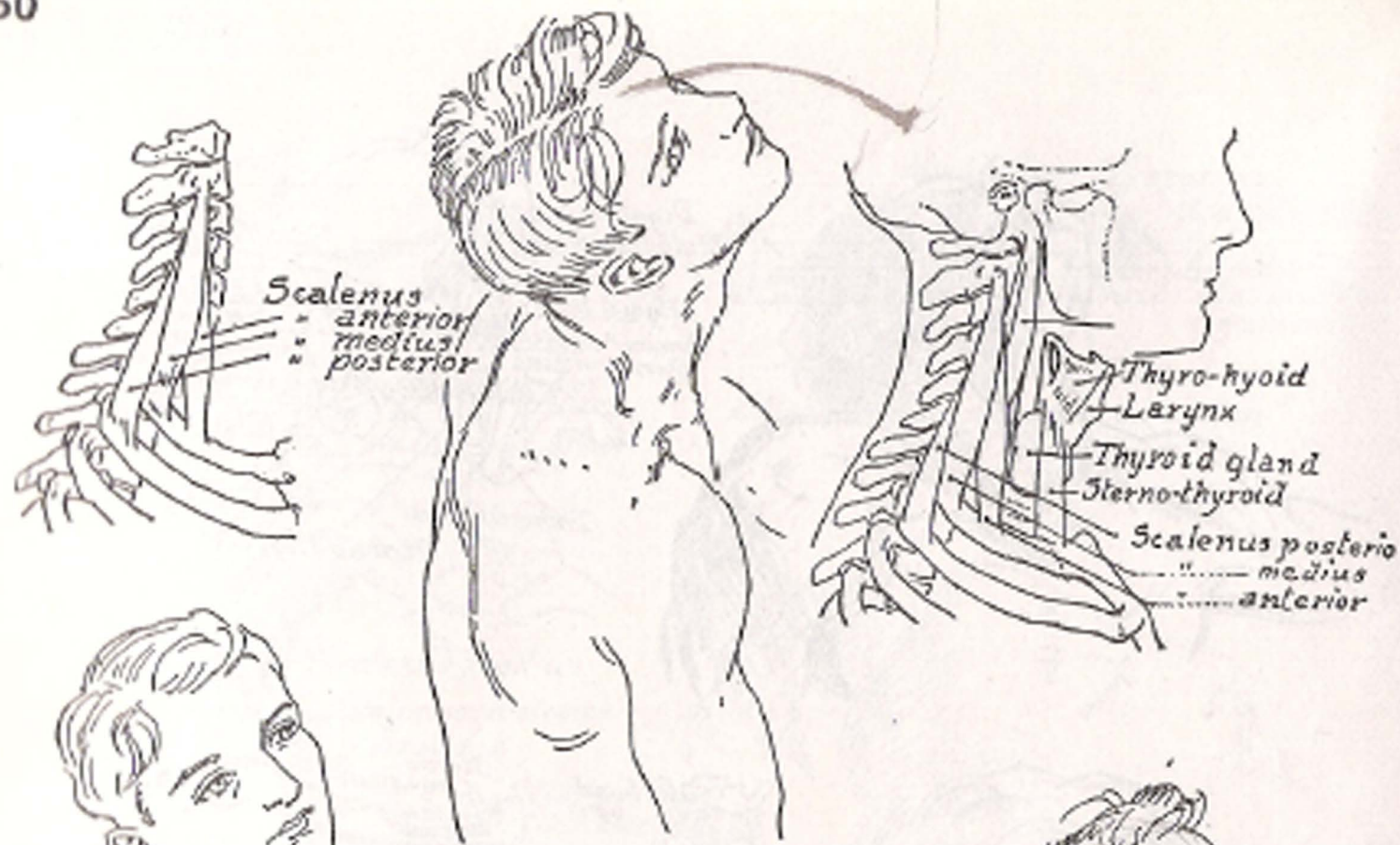


Back of scapula  
Showing attachment of muscles



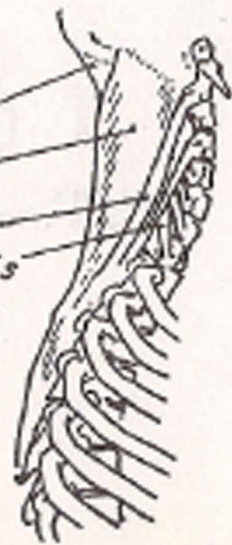Hyoid bone  
Epiglottis  
Thyroid cartilage  
Cricoid cartilage  
Thyroid gland  
Trachea

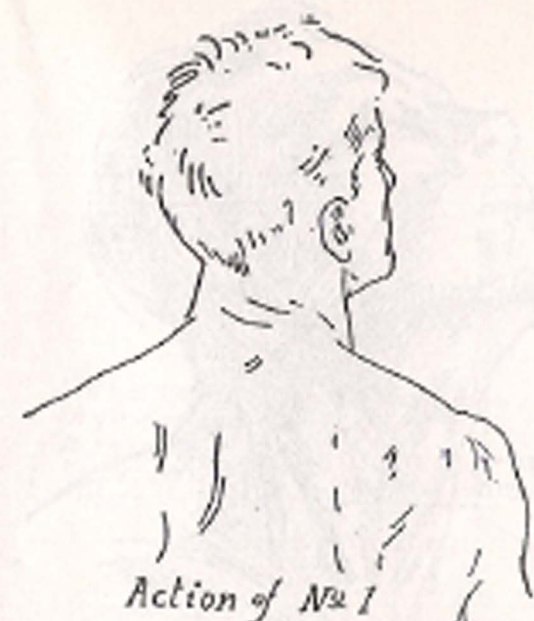



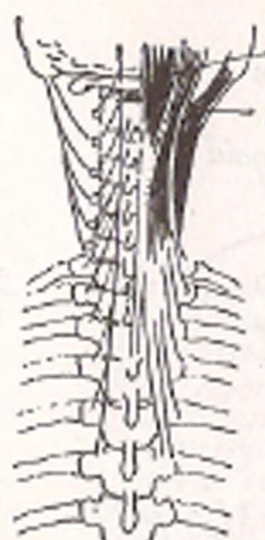Scalenus medius  
Scalenus posterior  
Thyro-hyoid  
Scalenus anterior  
Sterno-hyoid  
Omo-hyoid  
Thyroid gland  
Levator scapula

Complexus  
Splenius  
" of neck  
Longus capitis





*Small splenius*



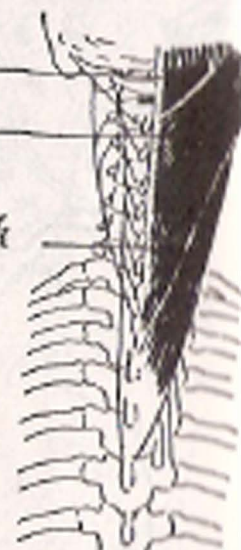
No 1

Complexus  
Small splenius

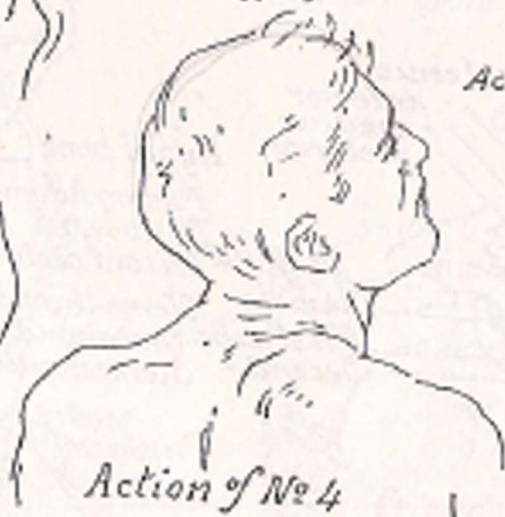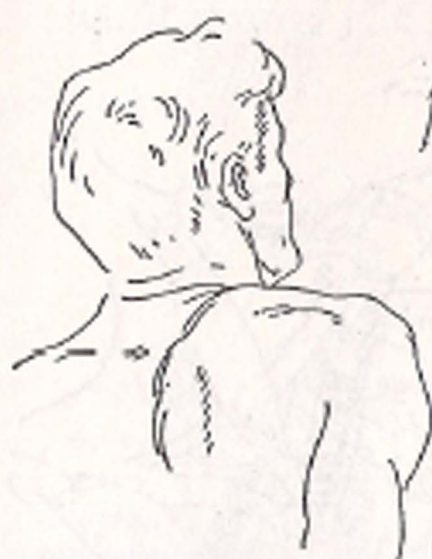Complexus  
Splenius  
Splenius of neck



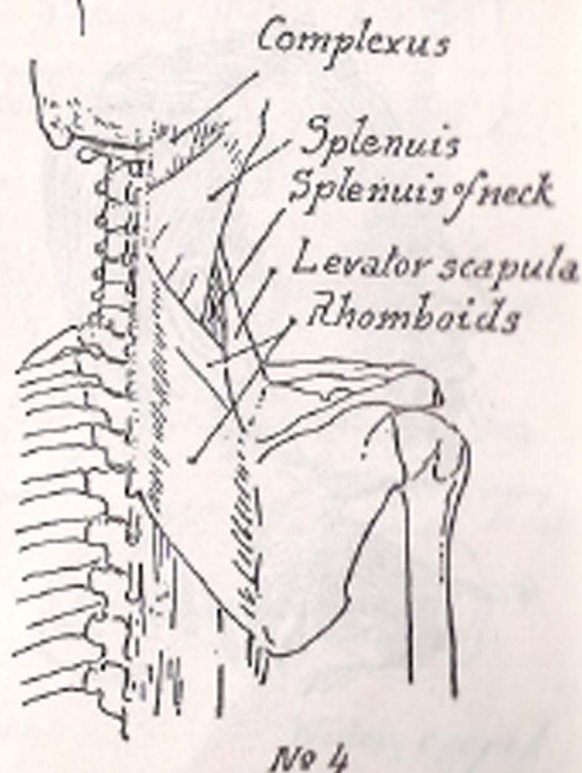
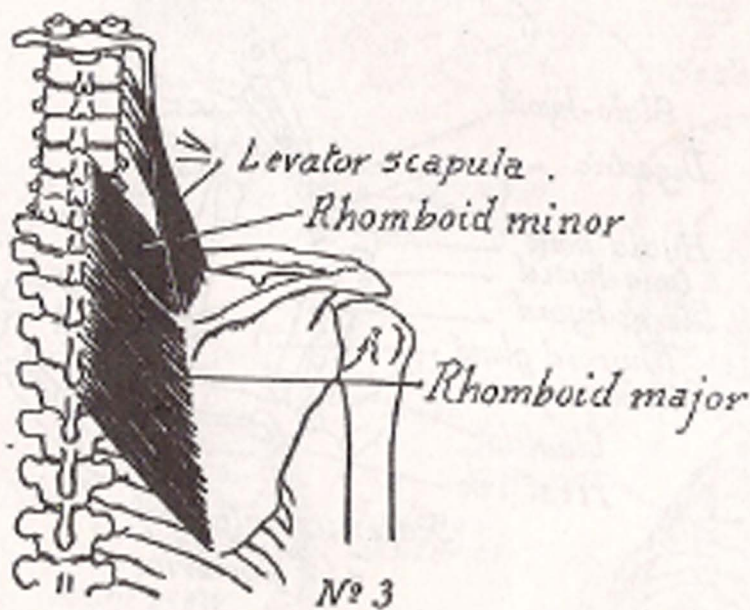
Action of No 2

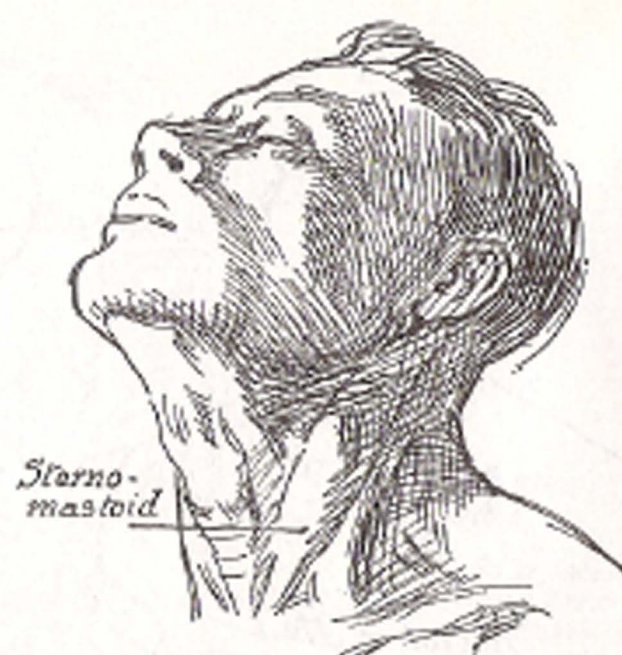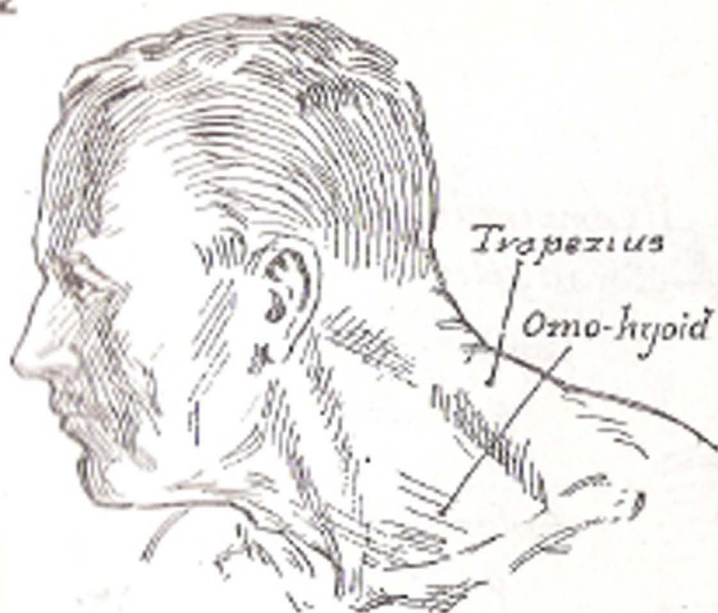


No 2

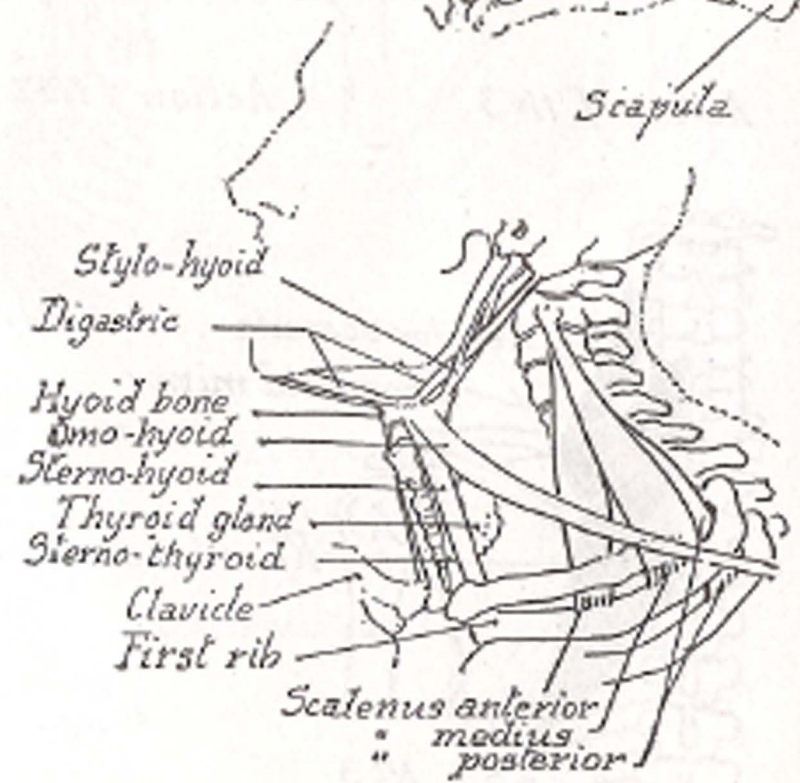
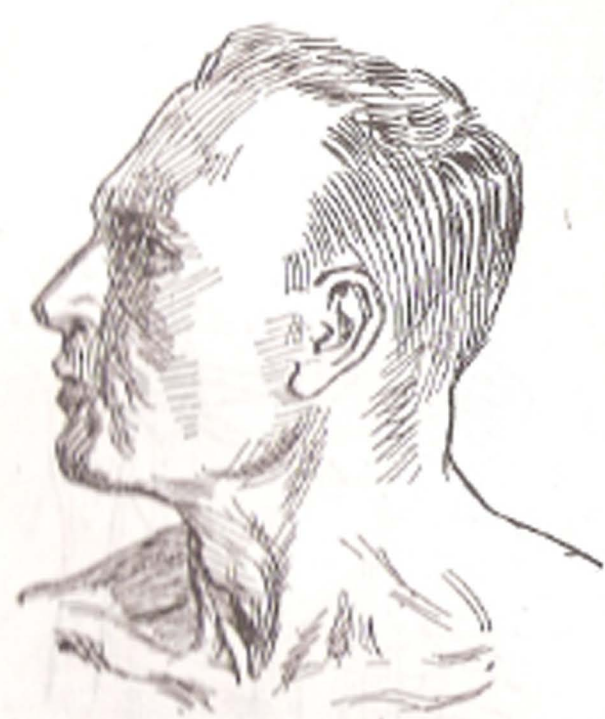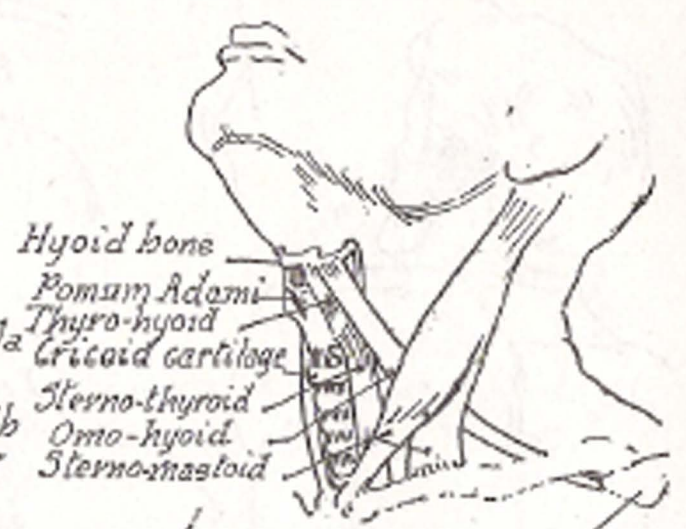
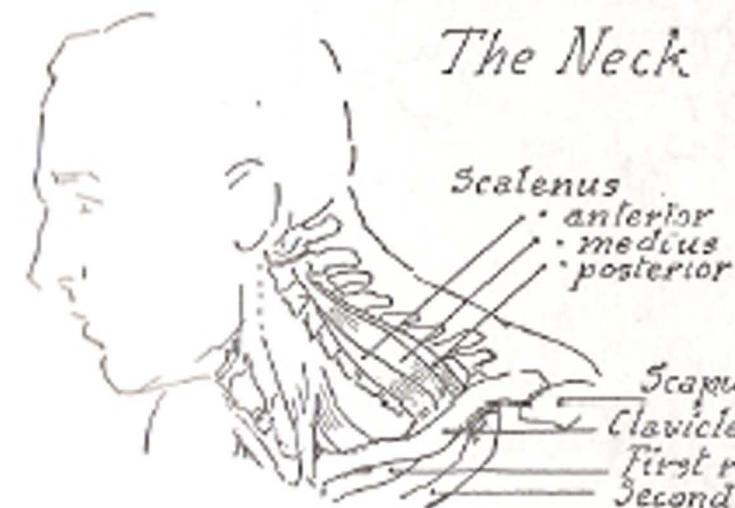


Muscles of back of neck

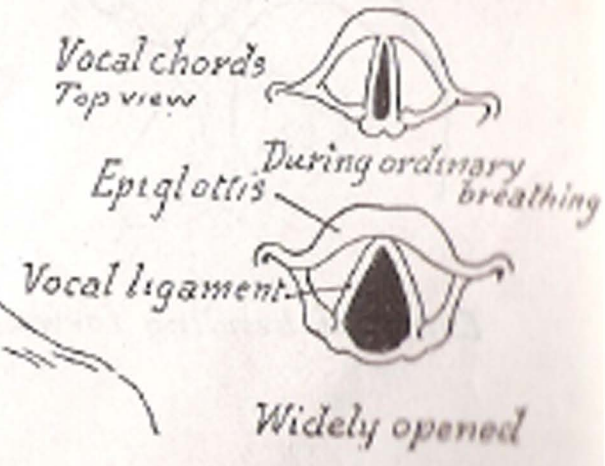
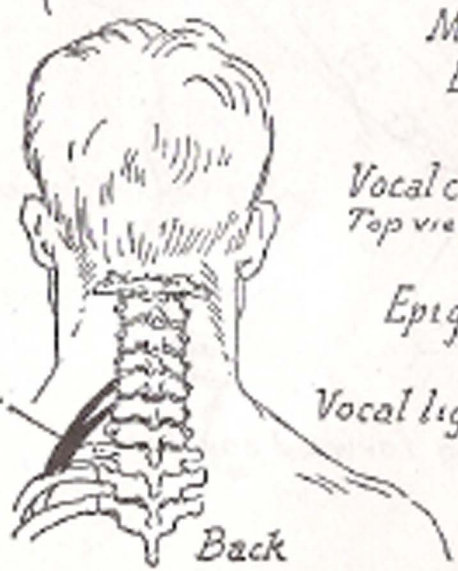
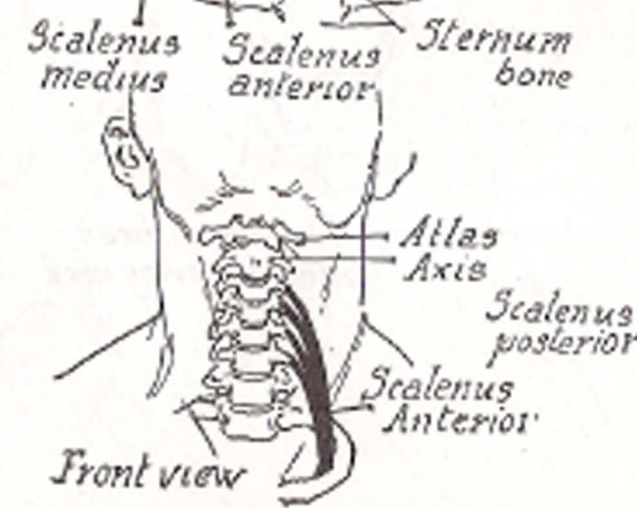
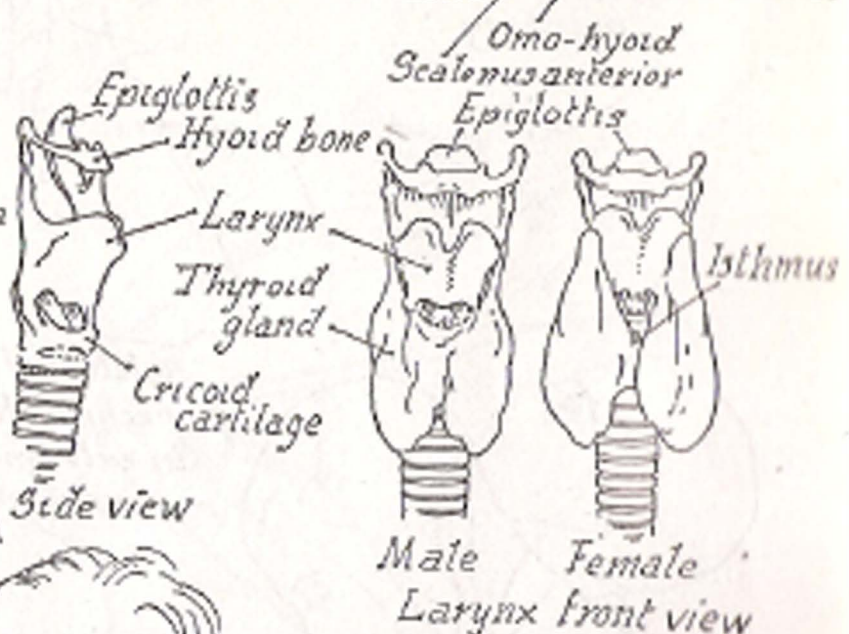
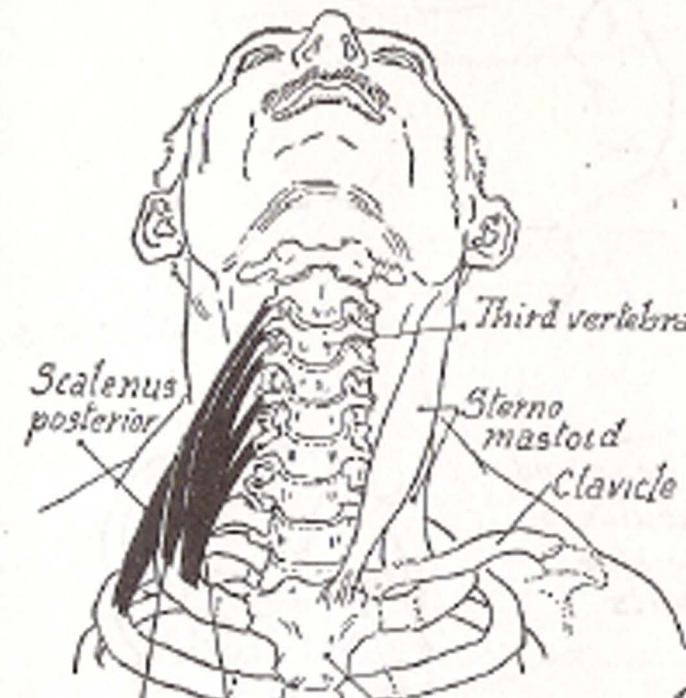
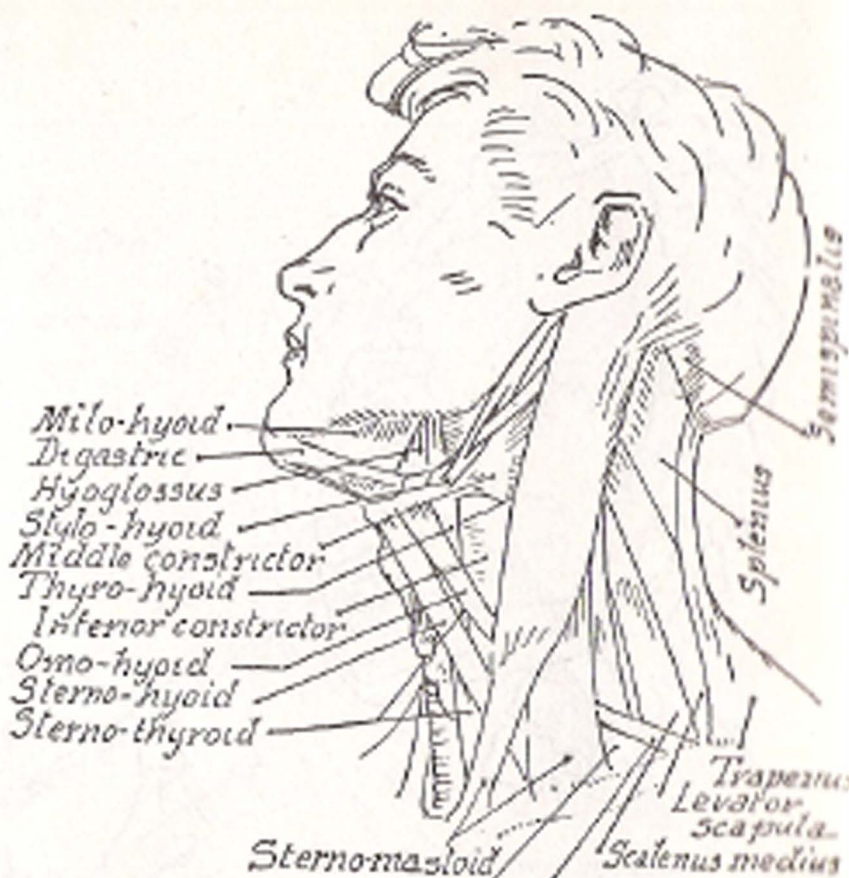
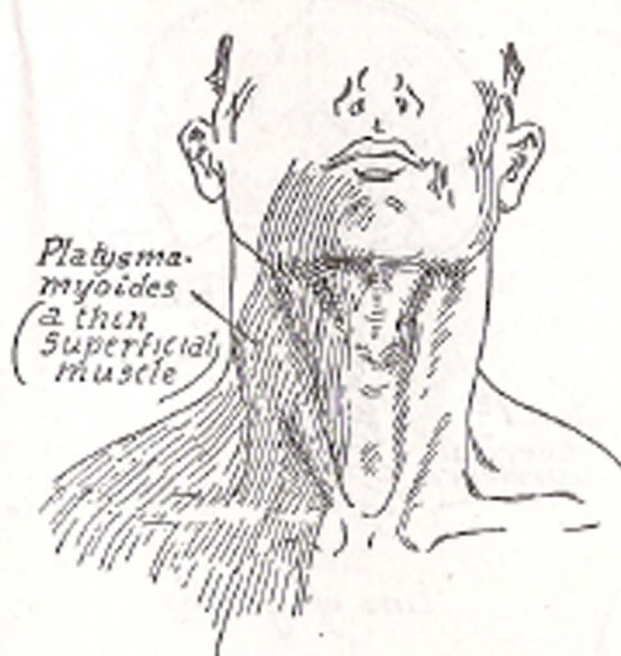


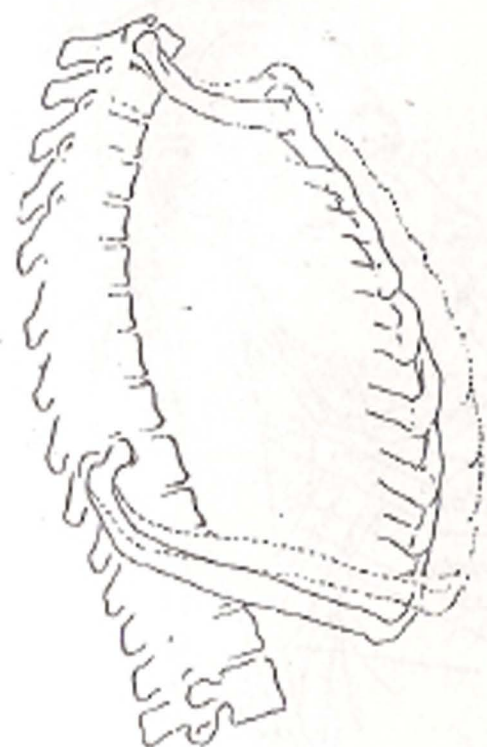


The Neck

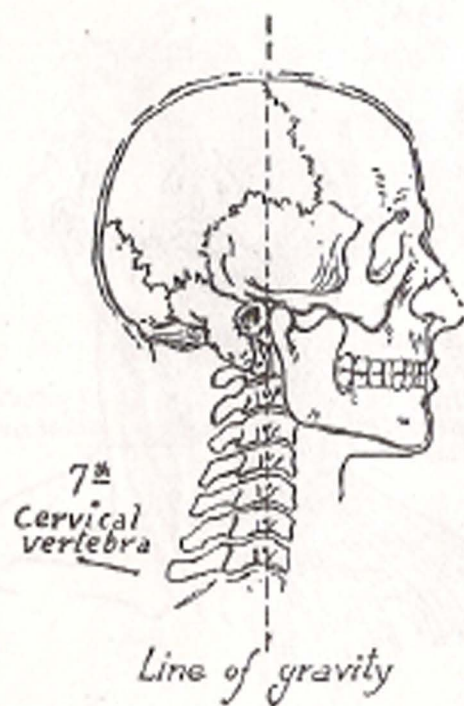






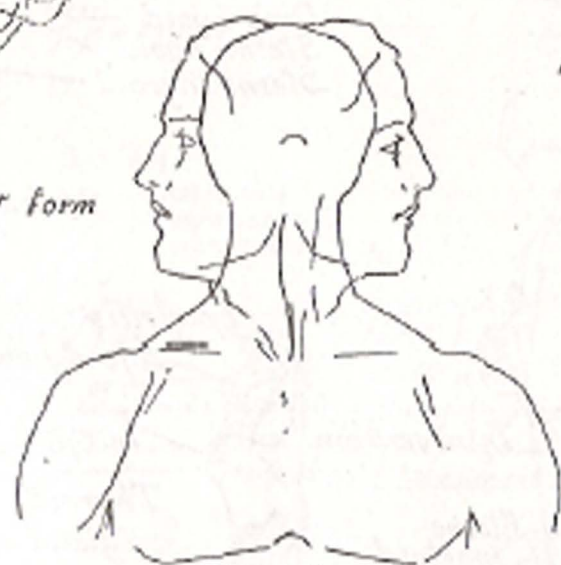


*Modification of chest form  
in breathing*

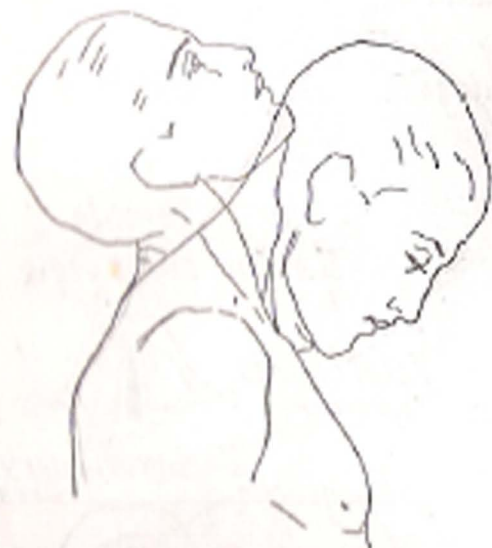

7<sup>th</sup>  
Cervical  
vertebra

*Line of gravity*



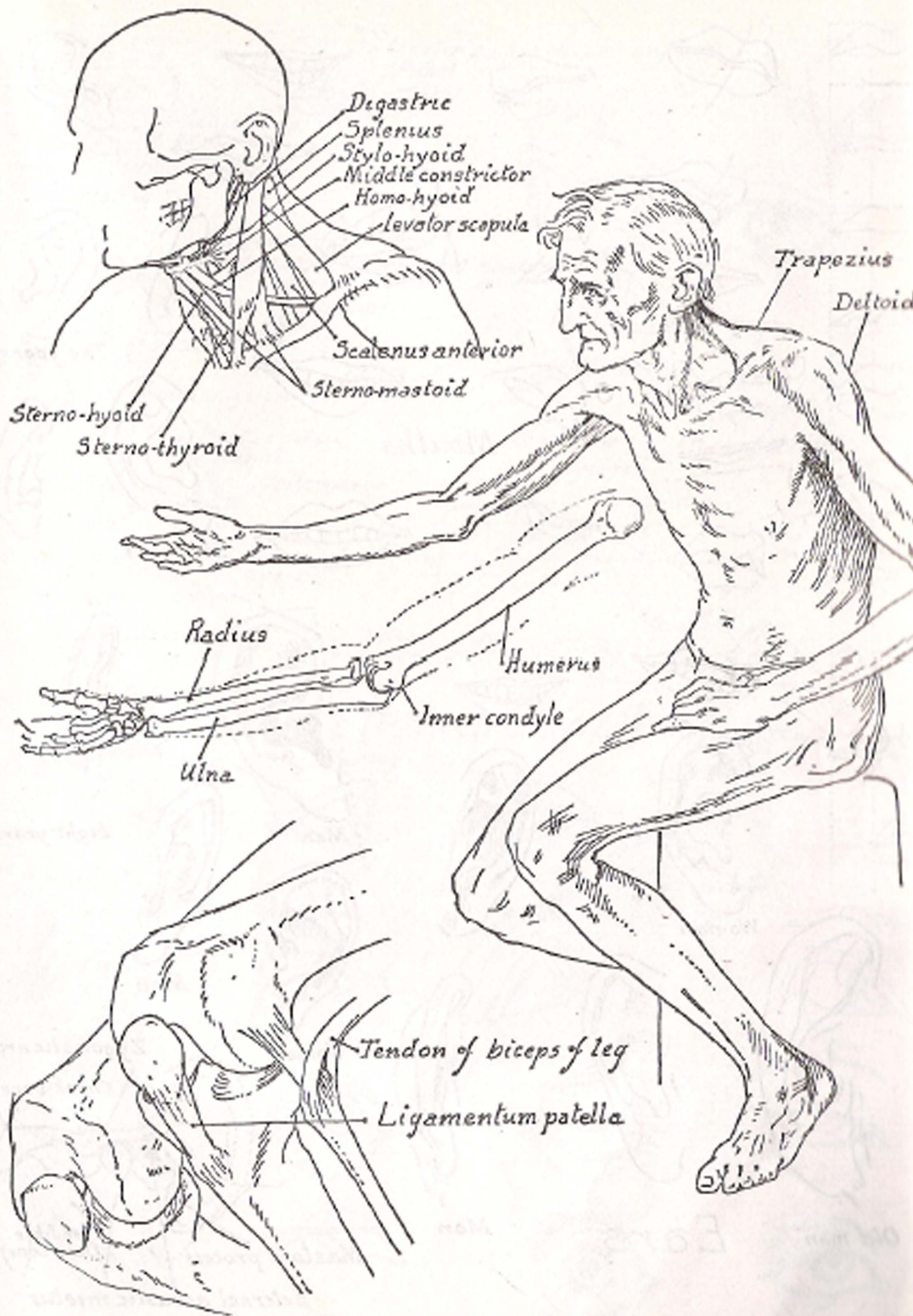
*Relation of head and  
neck to shoulders  
in extreme side  
movements*

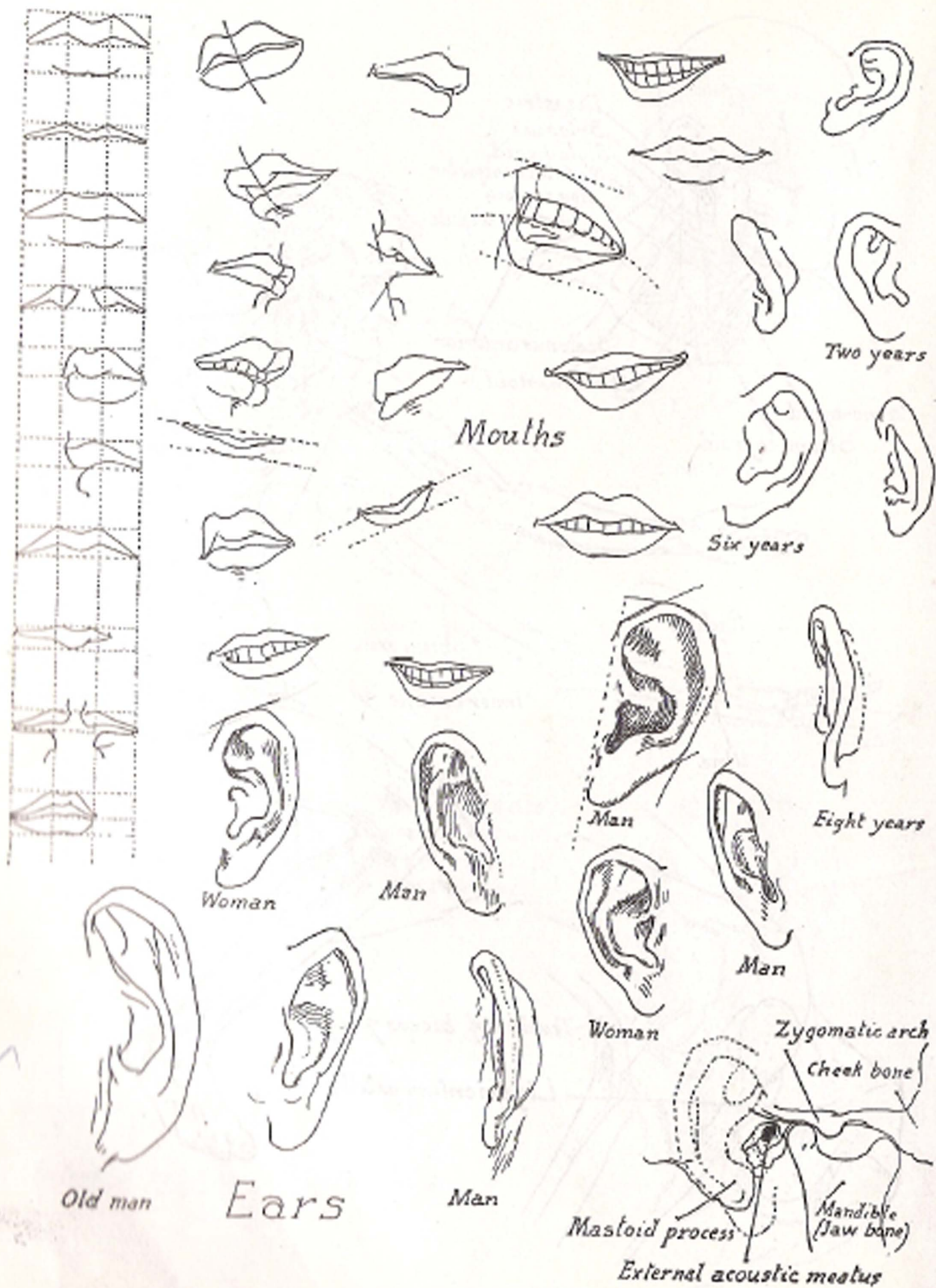



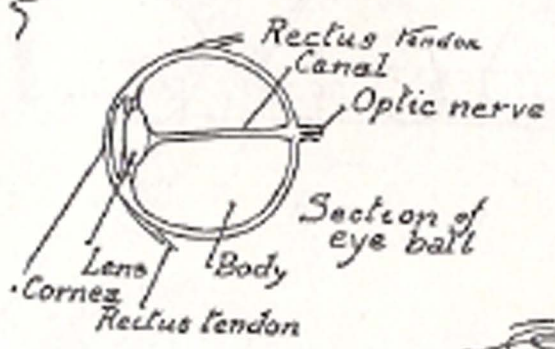
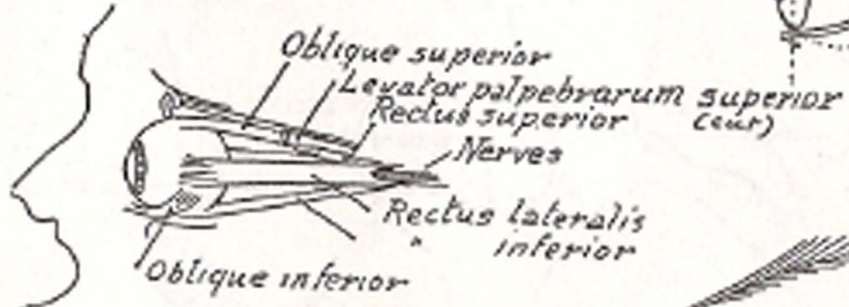
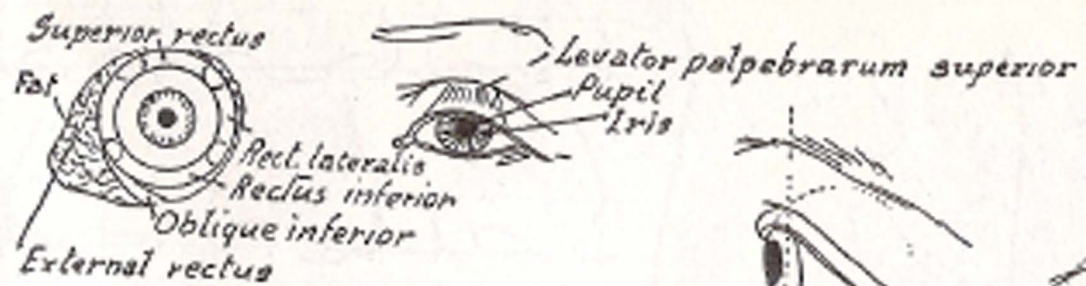
*Extent of bending forward and back*




*Flexion of head  
without moving neck*

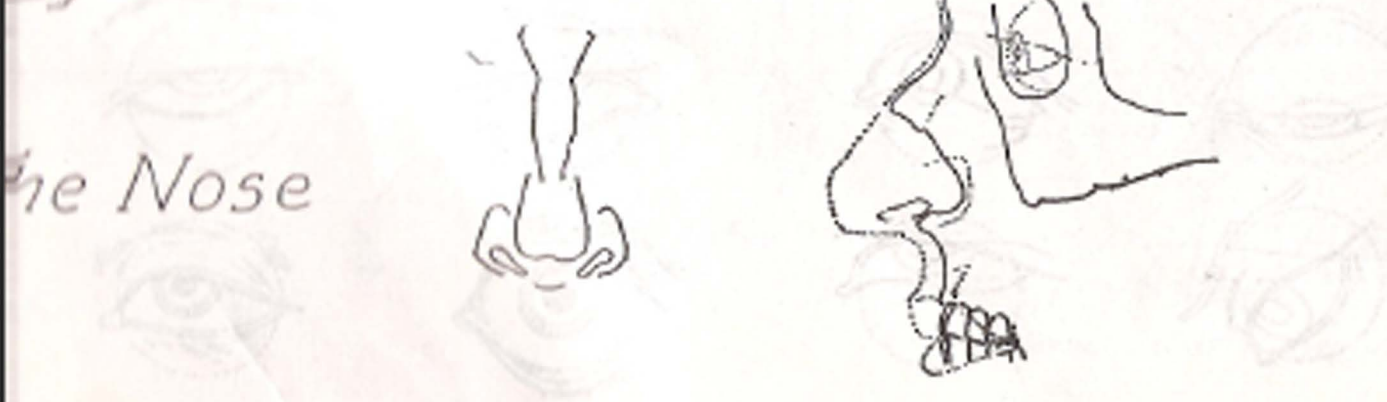
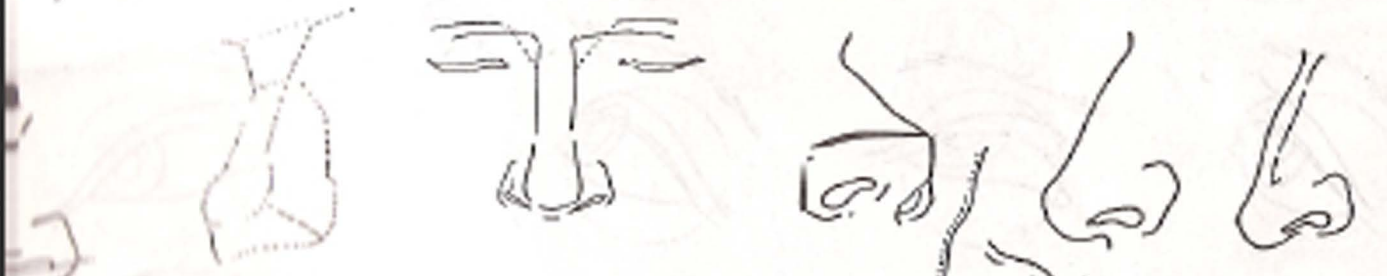
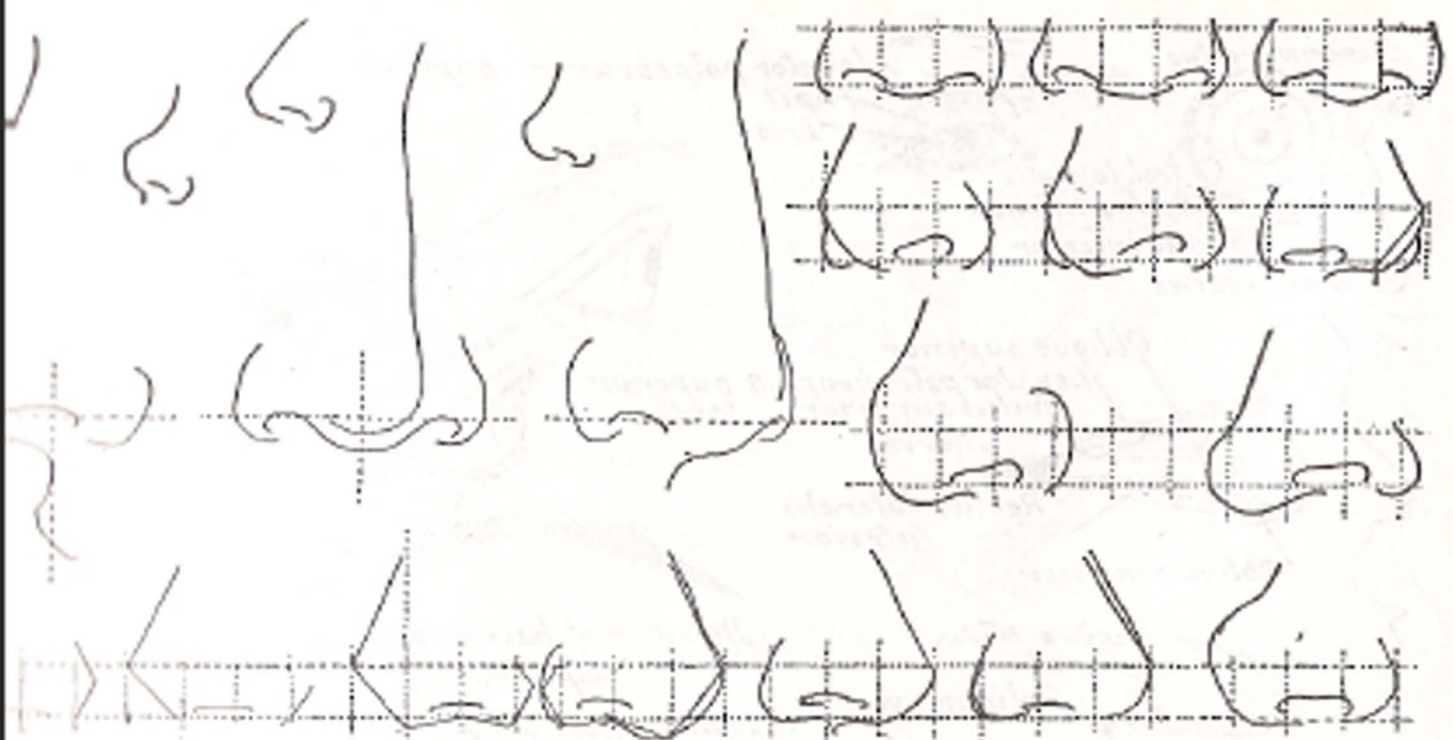






EYES (PRINCIPLES & ACTION)





The Nose



*Caucasian  
(white race)*



*Prehistoric  
type*



*Mongolian  
(yellow race)*



*Ethiopian  
(black race)*



*American Indian  
(red race)*



*Malayan  
(brown race)*



*The five races of man*



*Surprise*



*Disapproval*



*Amusement*



*Doubt*



*Pain*



*Strain*



*Anger*



*Disdain*



*Questioning*



*Reflection*



*Supplication*



*Reverie*



*Laughter*



*Skepticism*



*Happiness*



*Singing*



*Suspense*




*Laughter*

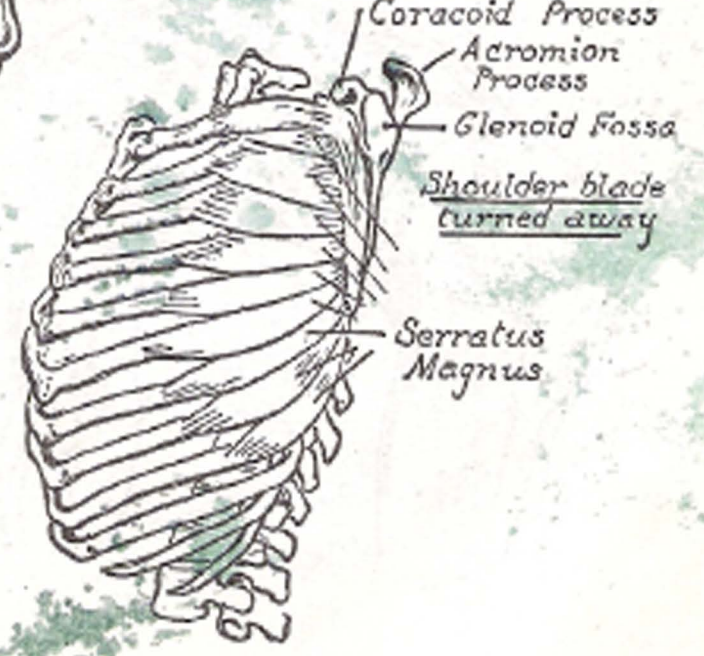
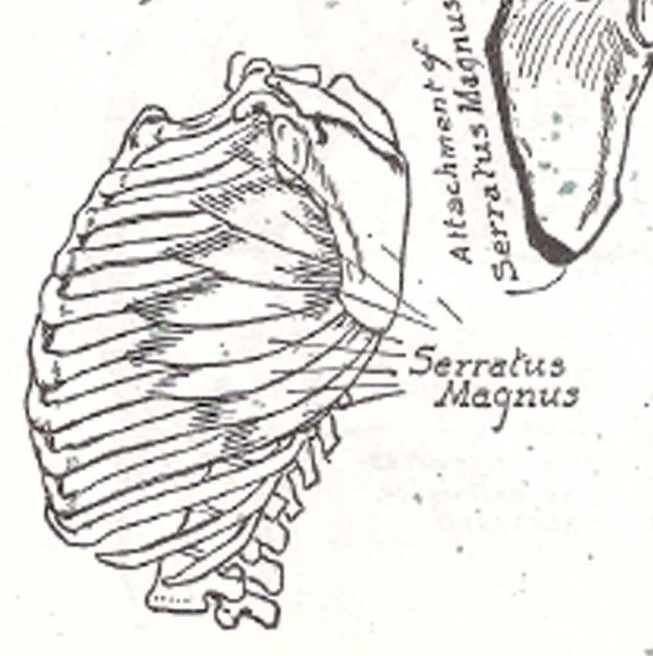
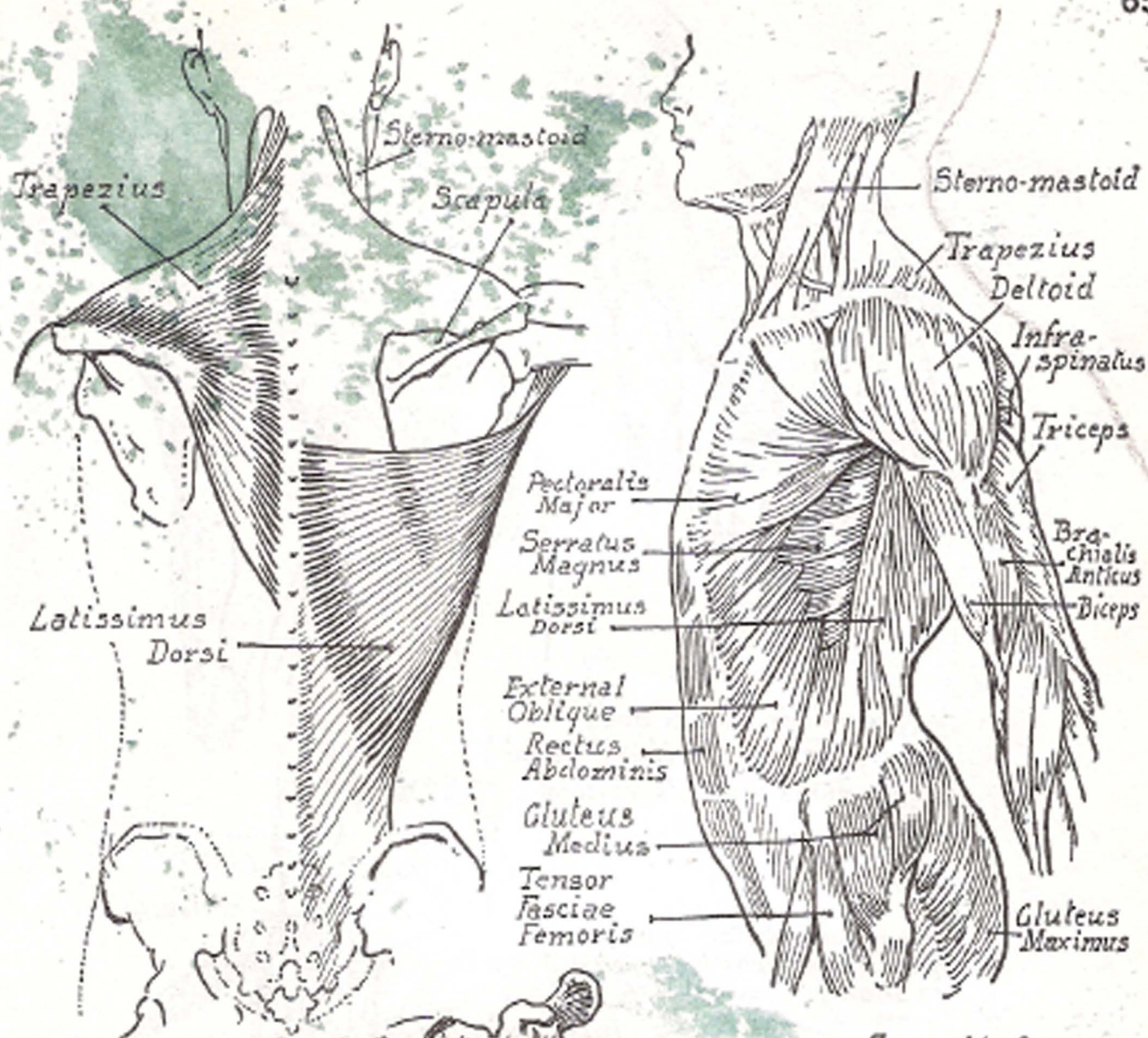





Studies of Expression




PART IV  
THE TORSO







Pelvic bone




Side inclination of body increased by shifting the pelvis from horizontal to oblique position




Group of erector spinae muscles stretched, permitting spine to show




Trapezius




Infra-spinatus



Triceps



Deltoid



Ilio-femoral ligament prevents excessive extension backward

Seventh cervical vertebra

Triceps (outer and middle head)

Deltoid

Trapezius

Teres major

Teres minor

Infra-spinatus

Rhomboideus major

Latissimus dorsi

External oblique

Gluteus maximus

Gluteus medius

Latissimus dorsi

External oblique

Serratus magnus

Rhomboideus major & minor

Infra-spinatus

Teres major

Teres minor

Deltoid

Rectus abdominis

Pectoralis major

Rectus abdominis

Gracilis

Tensor fasciae latae

Trochanter

Ilio-tibial band

Triceps

Position of scapula

Attach of muscle

Trapezius

Deltoid

Teres minor

Infra-spinatus

Teres major

Rhomboideus major

Illustration of position of scapula when arm is raised

Pectoralis major

Serratus magnus

Triceps middle head

Deltoid

Teres major

Teres minor

Infra-spinatus

Rhomboideus

Latissimus dorsi

Trapezius

Rhomboideus major & minor

Infra-spinatus

Teres major

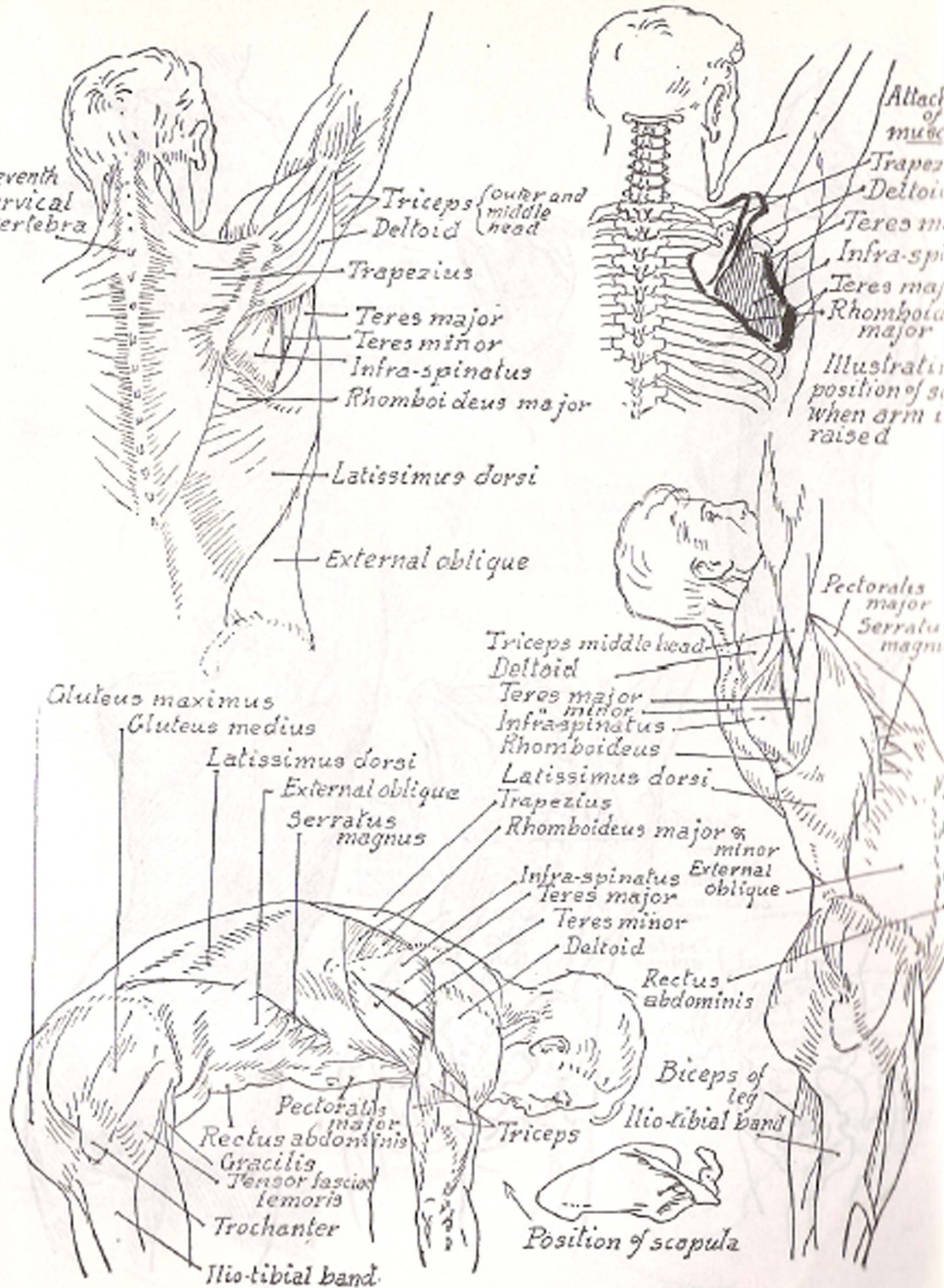
Teres minor

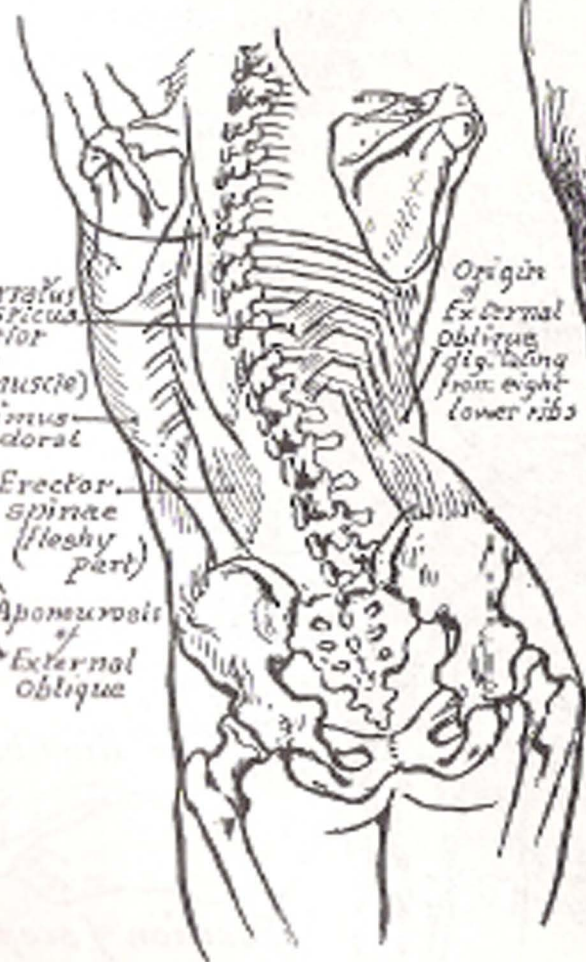
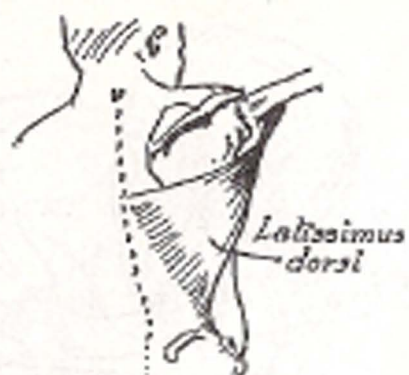
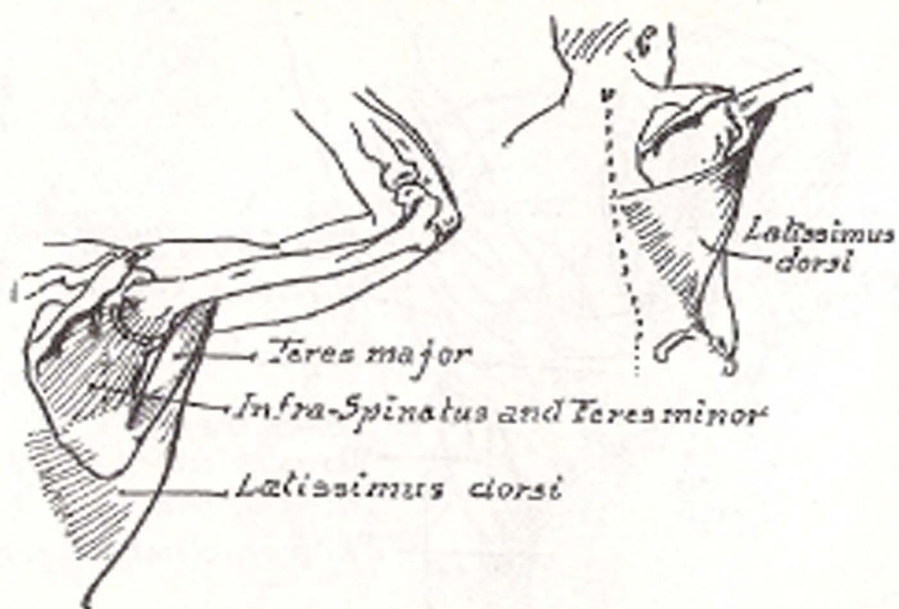
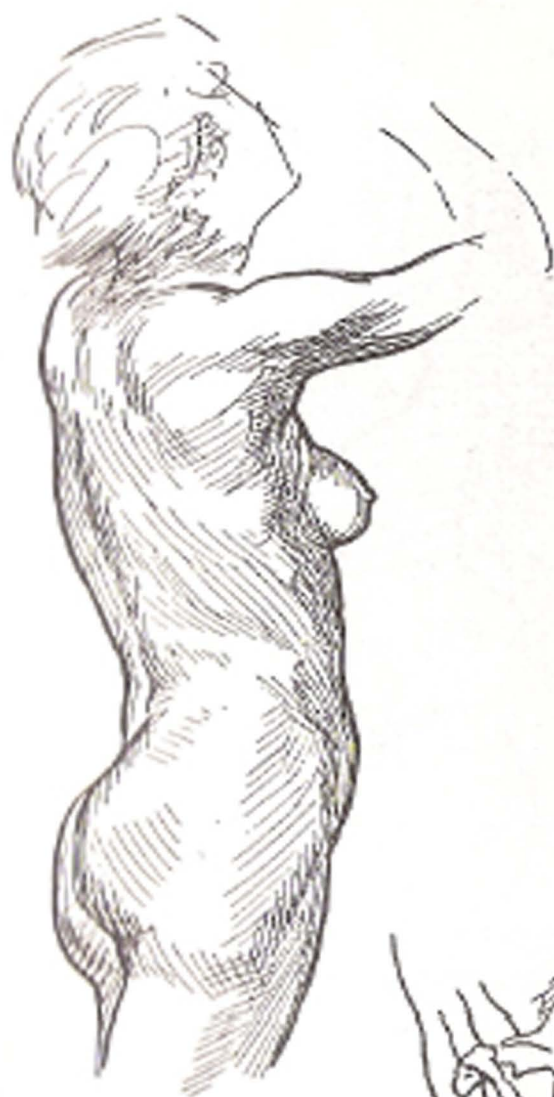
Deltoid

Rectus abdominis

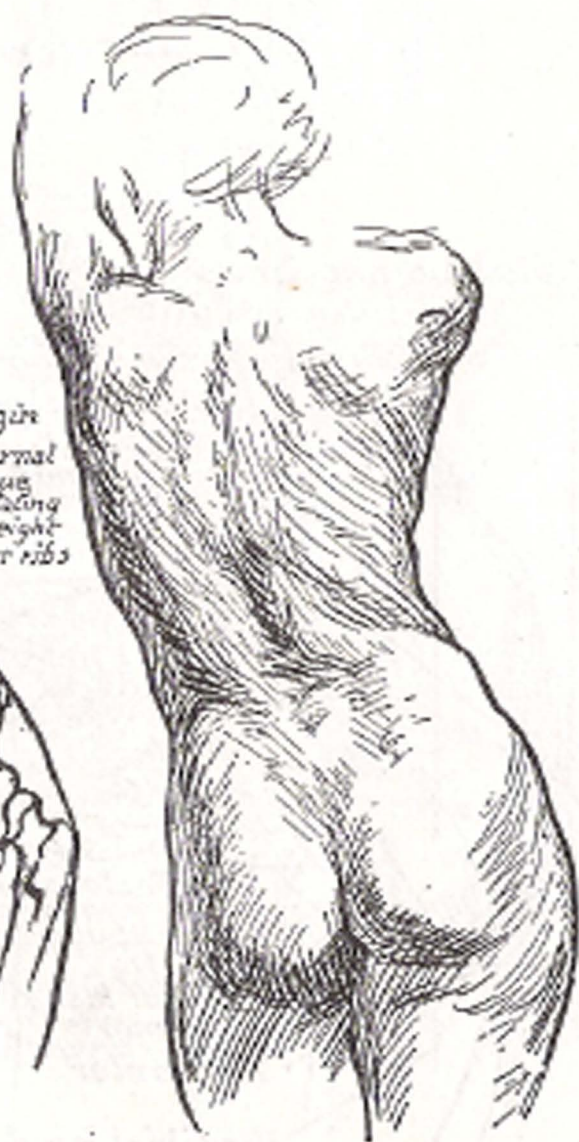
Biceps of leg

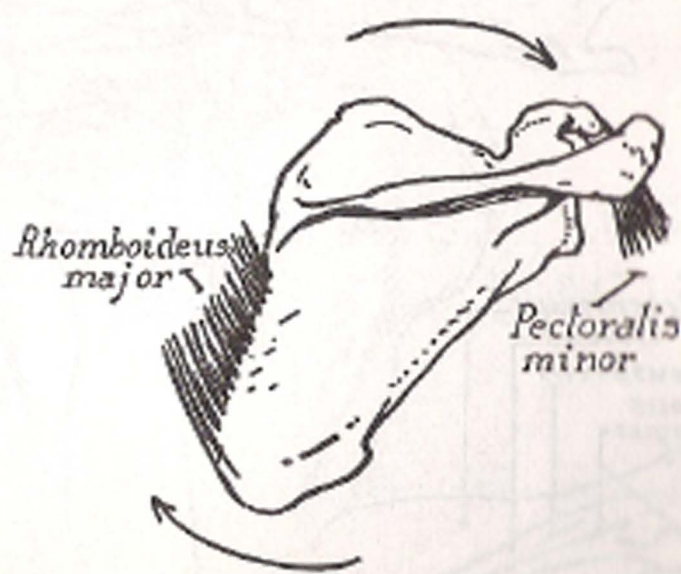
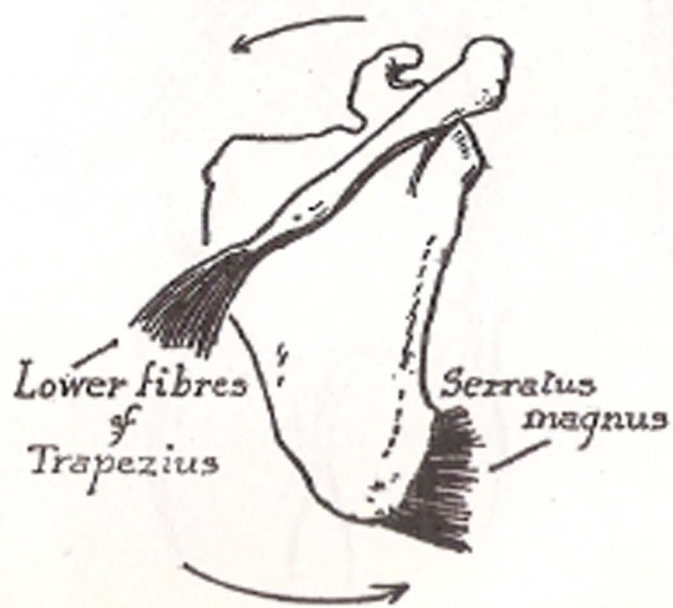
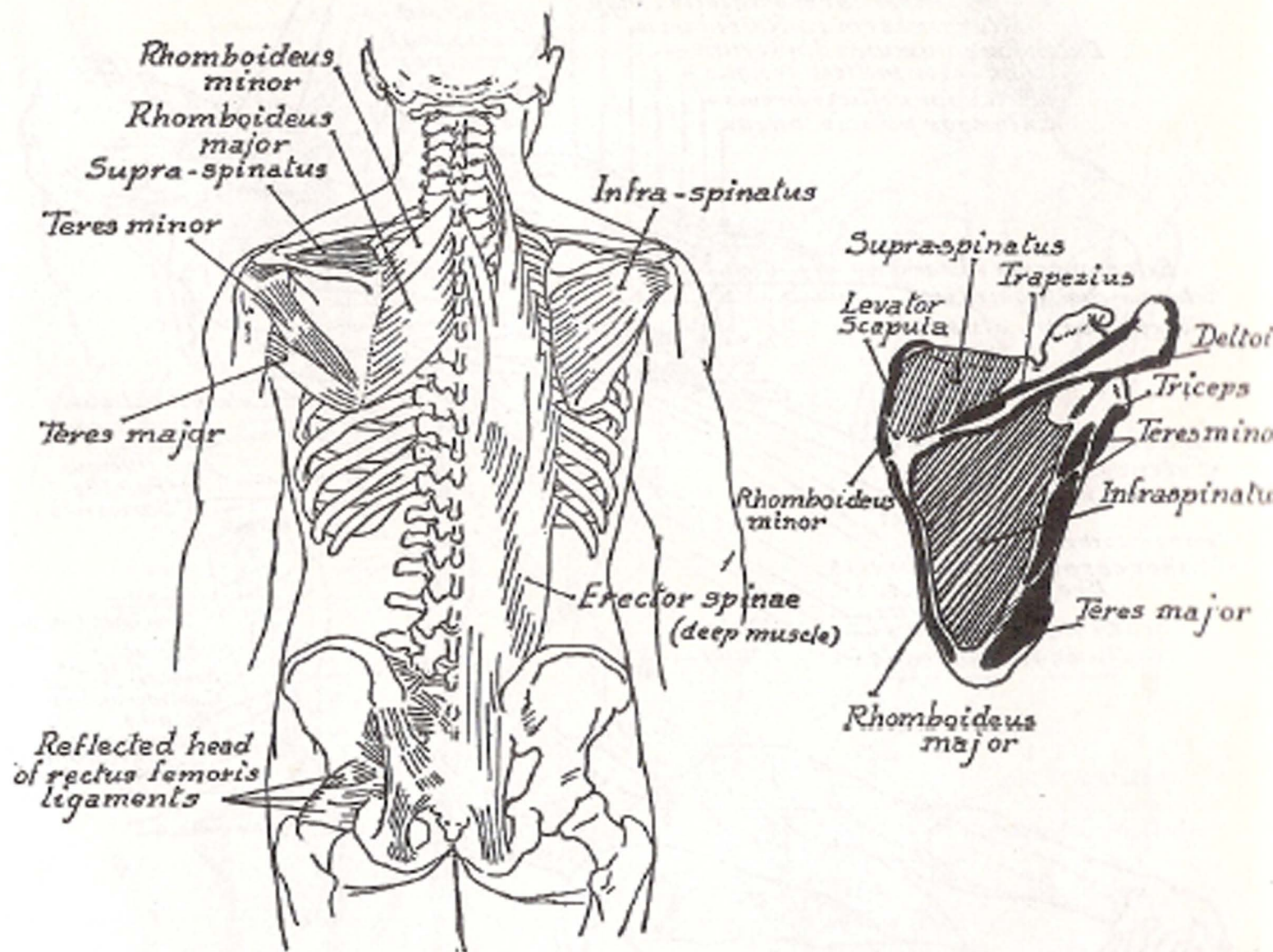
Ilio-tibial band





Origin of External Oblique dig. taking from eight lower ribs





*Supinator longus*  
*Extensor carpi radialis longus*  
*Extensor carpi radialis brevis*  
*Extensor communis digitorum*  
*Abductor pollicis longus*  
*Extensor pollicis brevis*  
*Extensor pollicis longus*

*Sterno mastoid*  
*Trapezius*  
*Deltoid*  
*Infra-spinatus*  
*Teres minor*  
*Teres major*  
*Triceps*

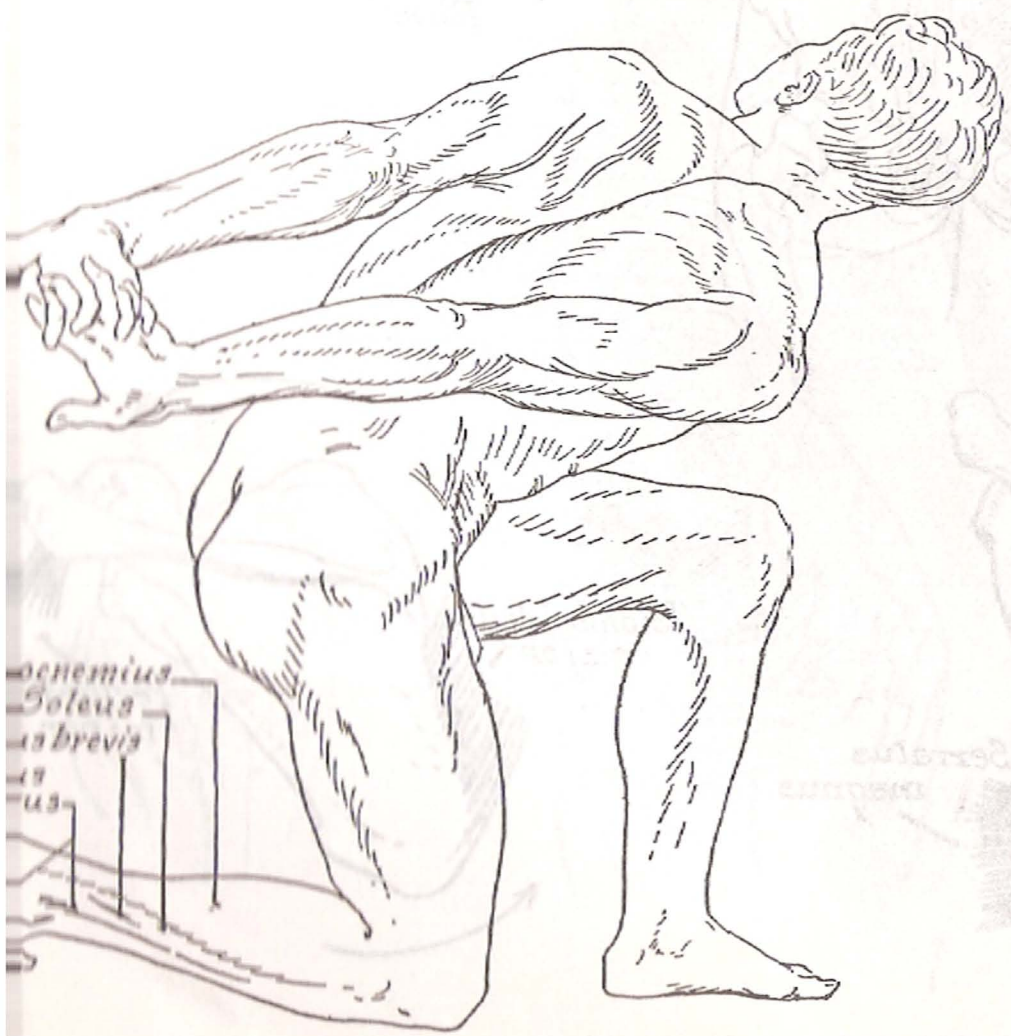
*Extensor carpi ulnaris*  
*Extensor digiti quinti*  
*Flexor carpi ulnaris*

*Extensor pollicis longus*  
*Extensor pollicis brevis*  
*Abductor pollicis longus*  
*Anconeus*  
*Extensor communis digiti*  
*Extensor carpi radialis brevis*  
*Brachialis anticus*  
*Biceps*  
*Gluteus medius*  
*Gluteus maximus*

*Tensor femoris*

*External oblique*  
*Rectus femoris*  
*Vastus internus*  
*Patella*  
*Sartorius*

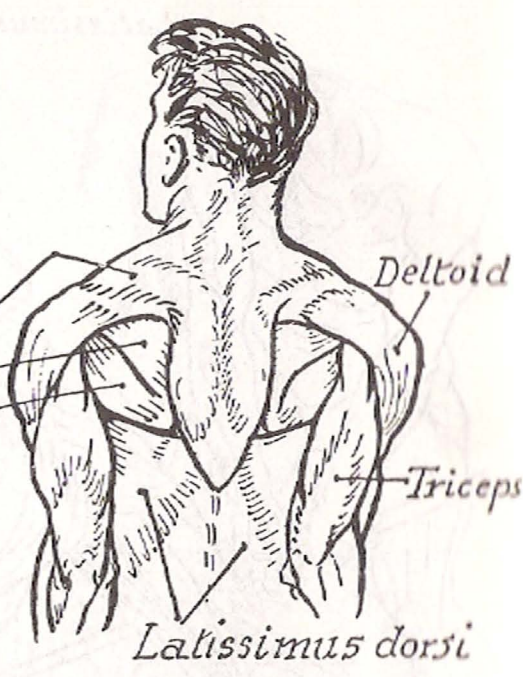
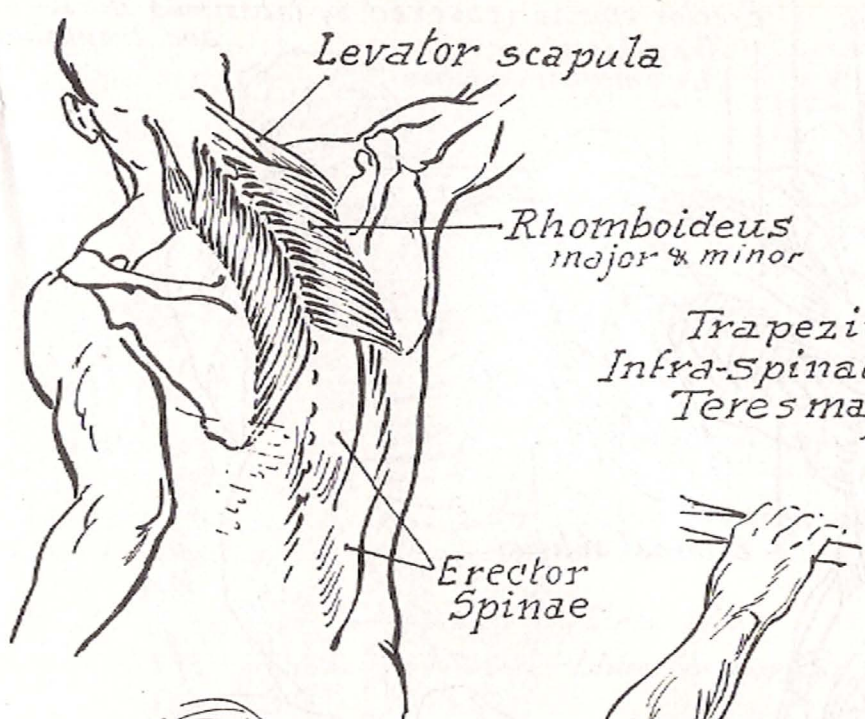
*Gracilis*  
*Semi-membranosus*  
*Adductor magnus*  
*Semi-tendinosus*  
*Gastrocnemius*  
*Soleus*  
*Flexor longus digitorum*  
*Tibialis posticus*  
*Tibialis anticus*



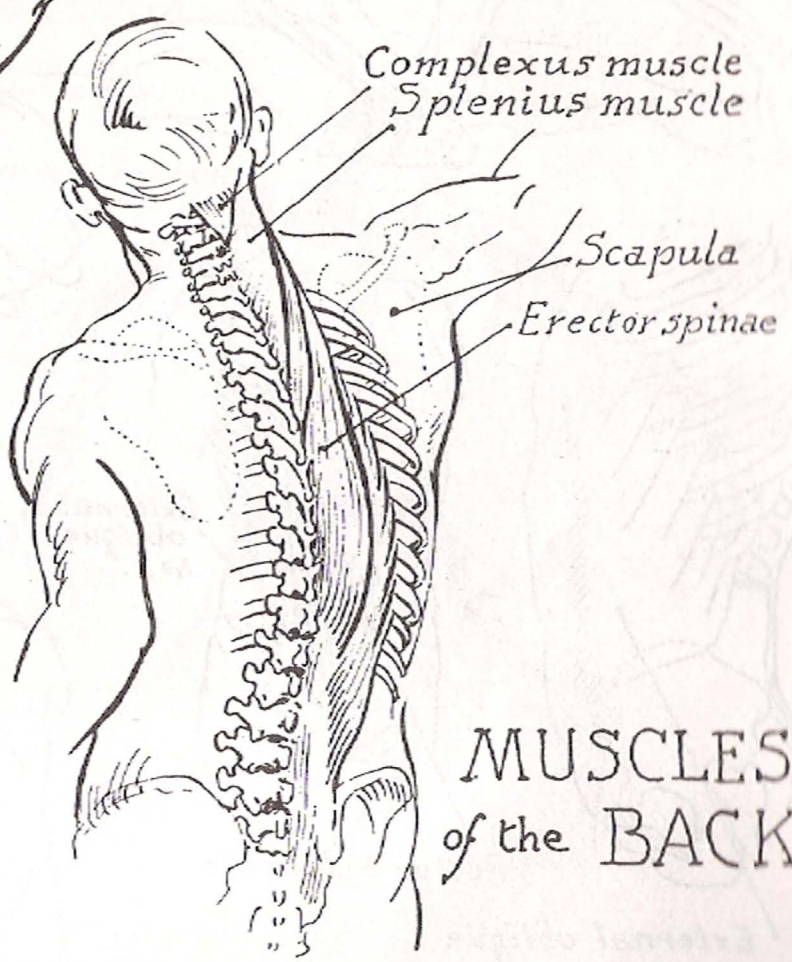
*Gastrocnemius*  
*Soleus*  
*Tibialis brevis*  
*Tibialis anticus*







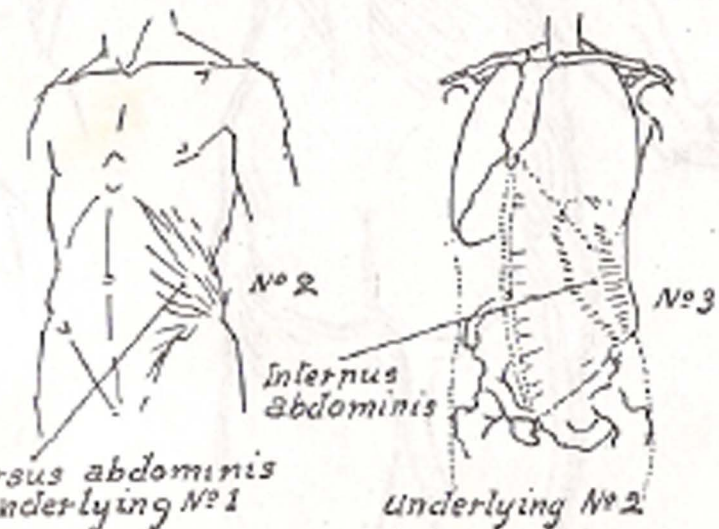
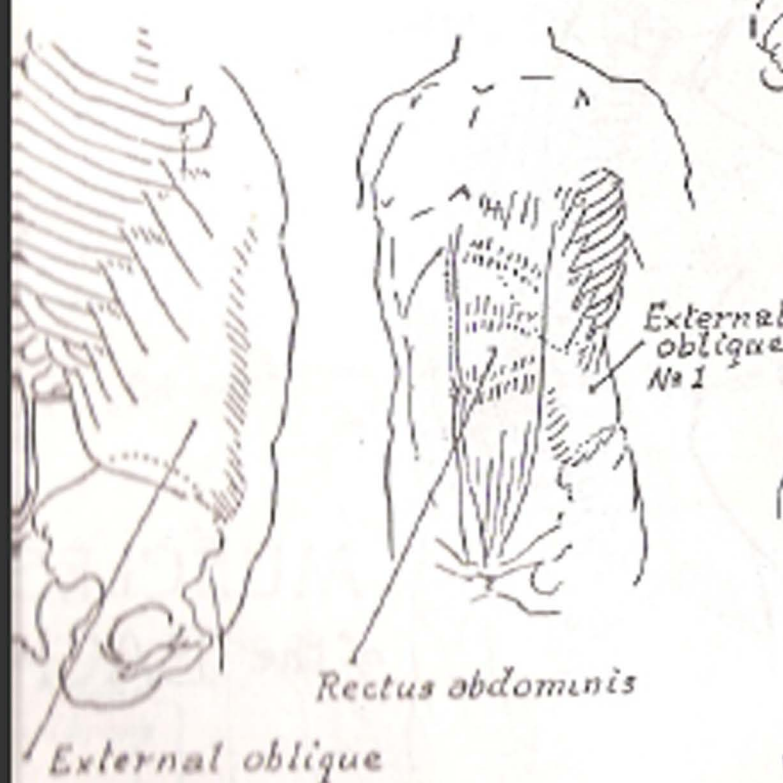
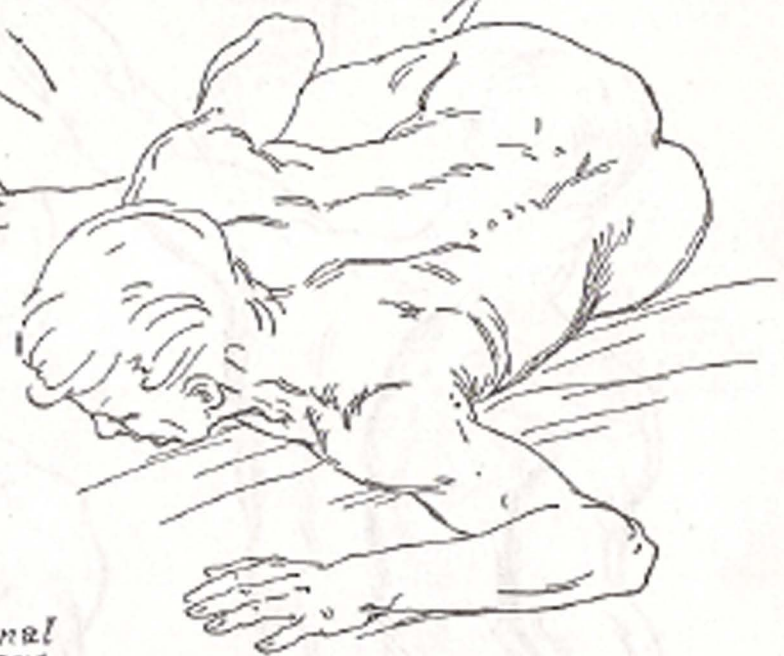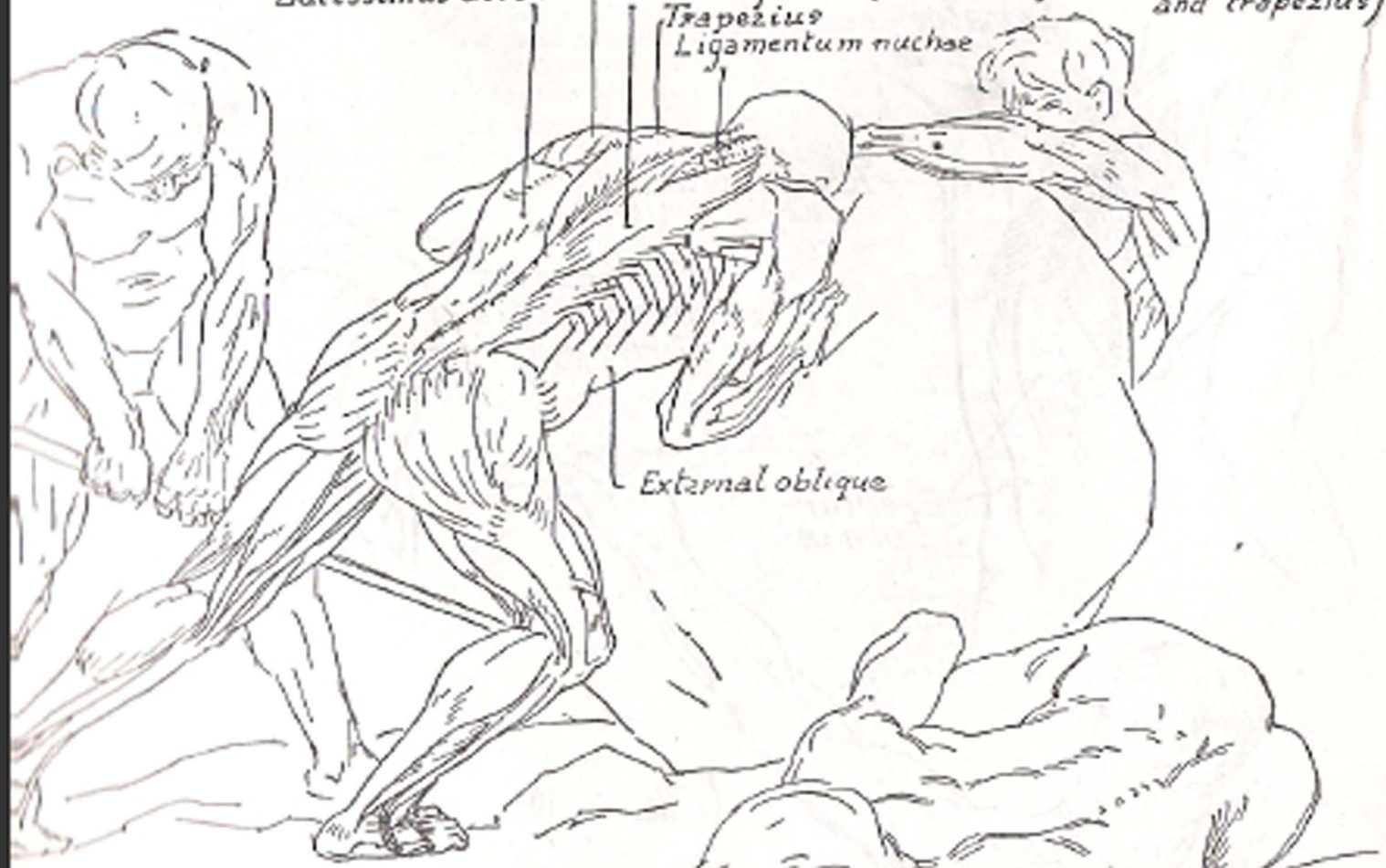
*Latissimus dorsi*



# MUSCLES of the BACK

*Victor Tenard*

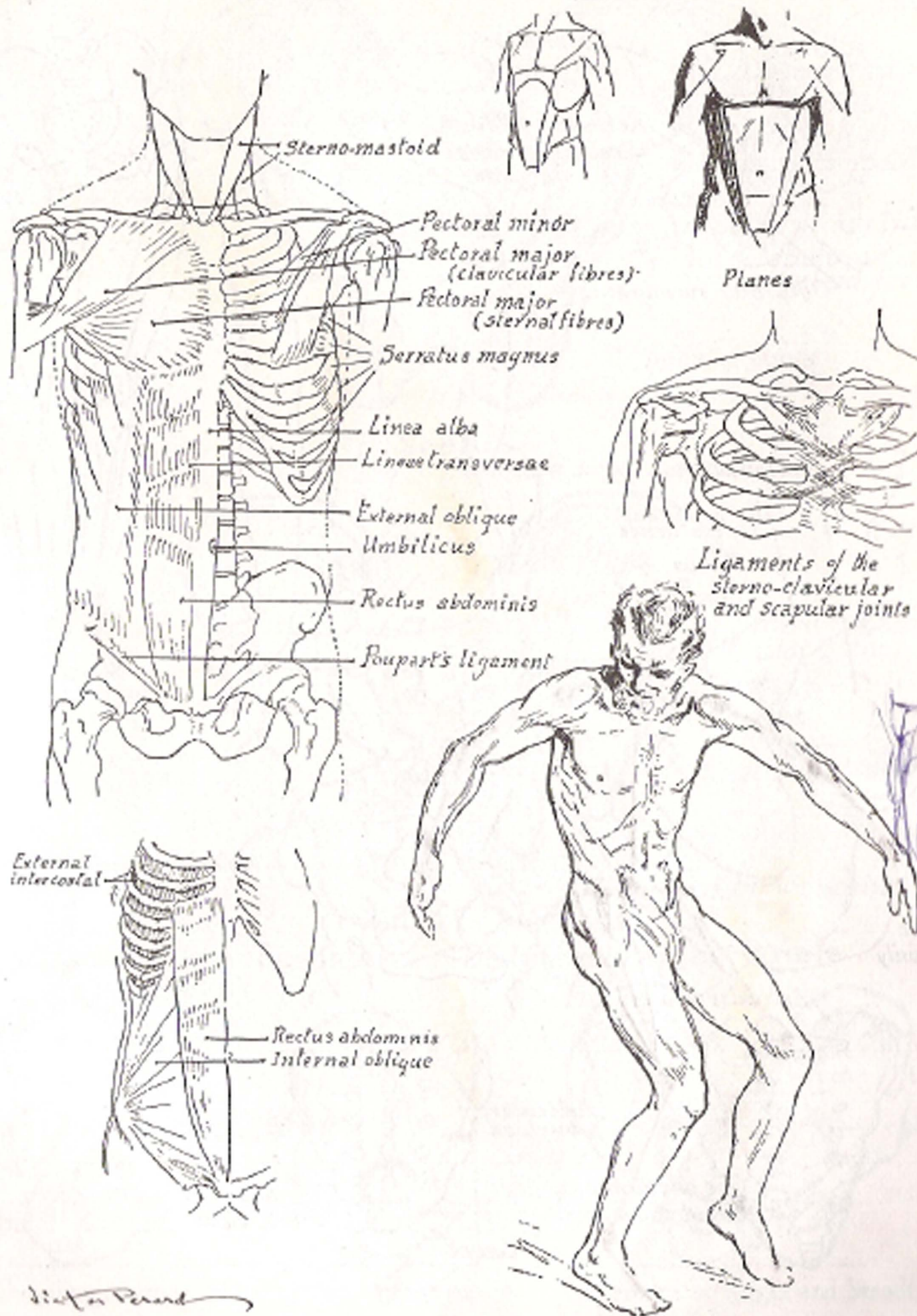
*Infra-spinatus*  
*Latissimus dorsi*  
*Erector spinae (covered by latissimus dorsi and trapezius)*  
*Trapezius*  
*Ligamentum nuchae*

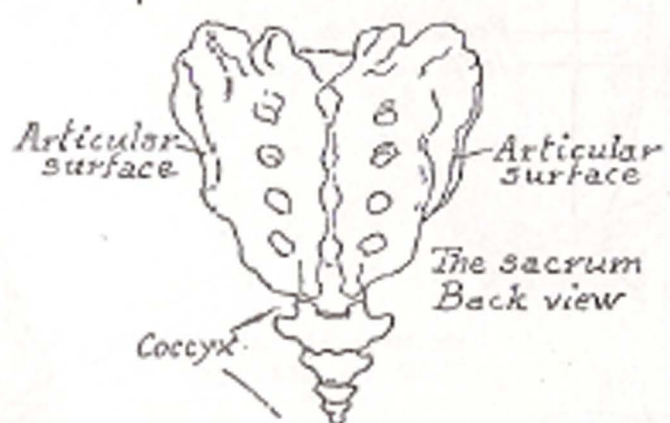
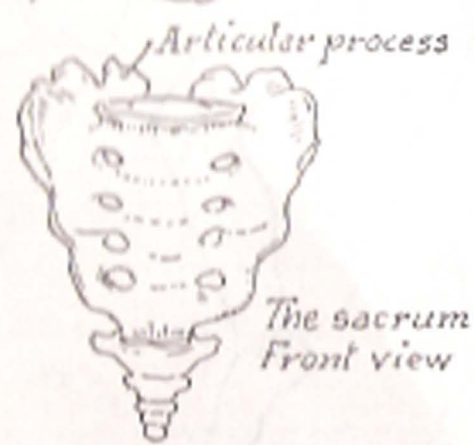
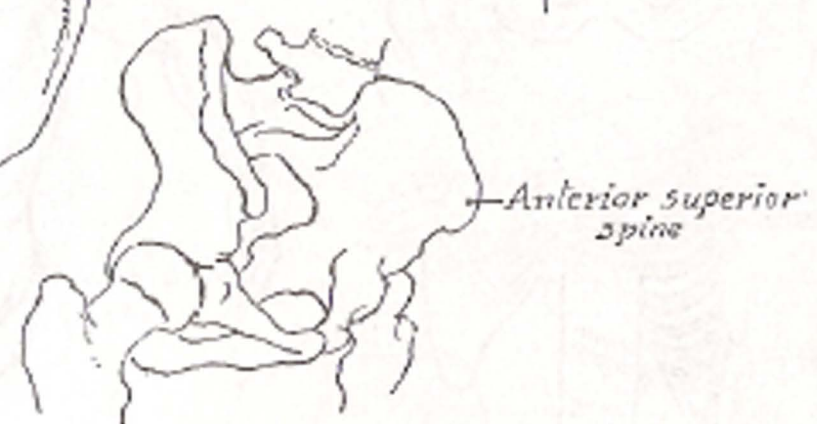
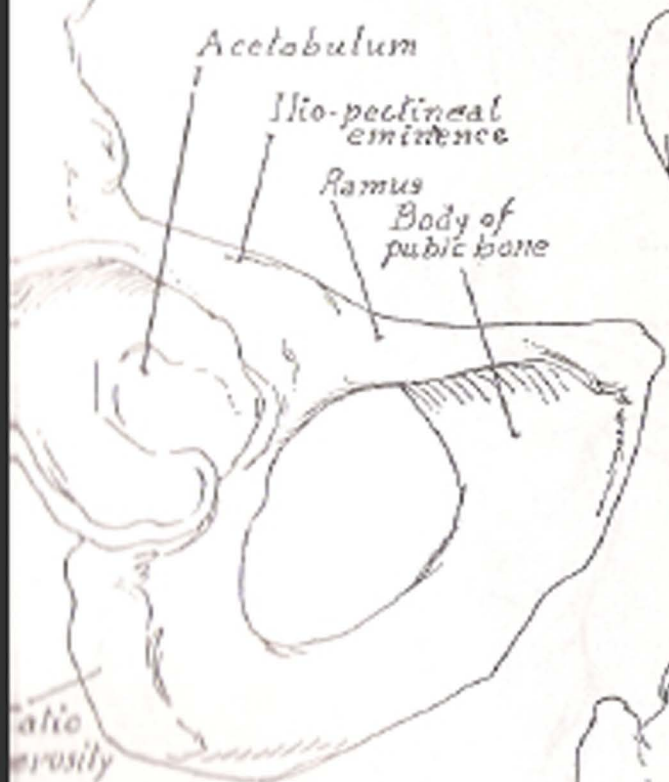
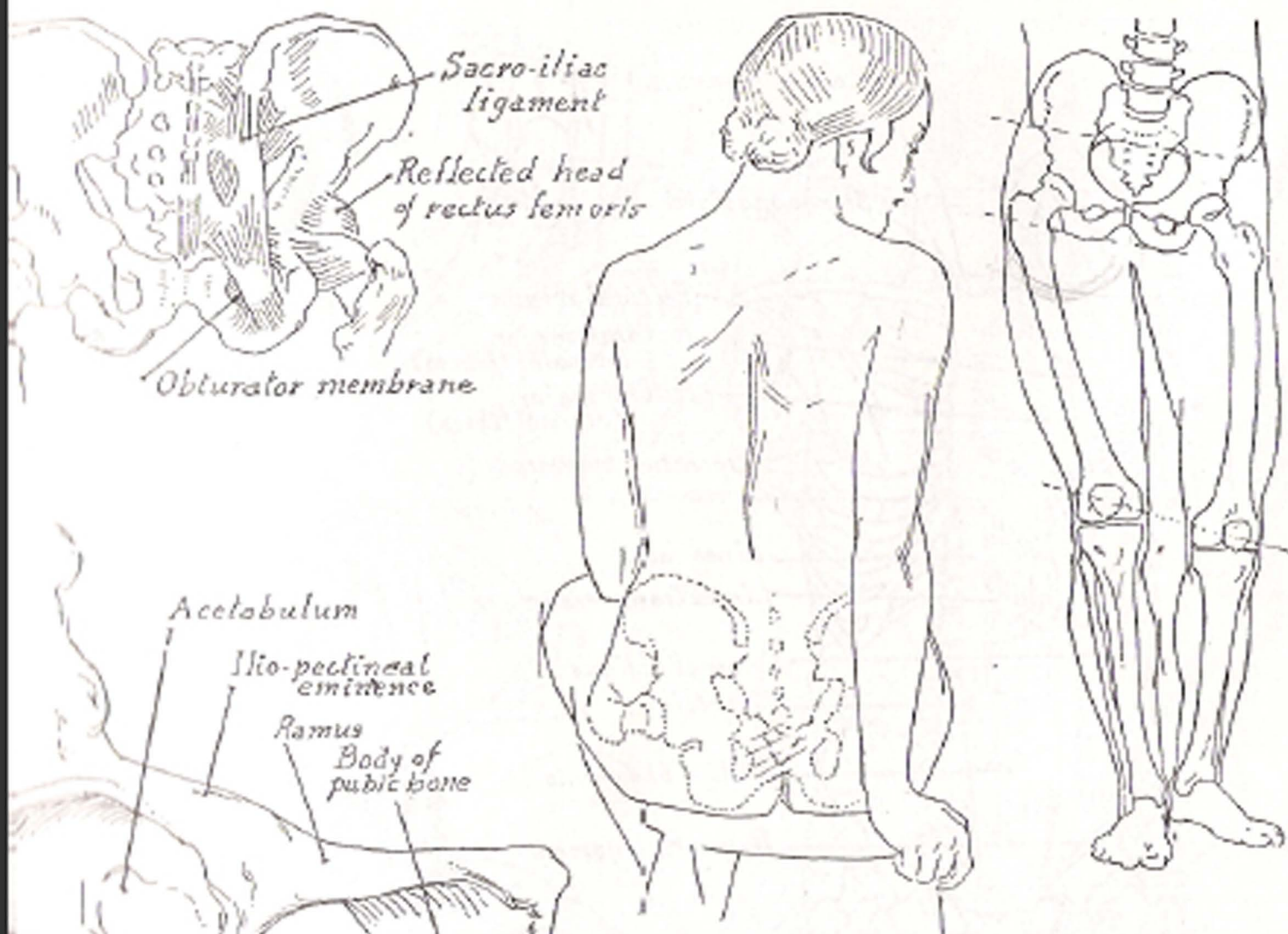


*External oblique*

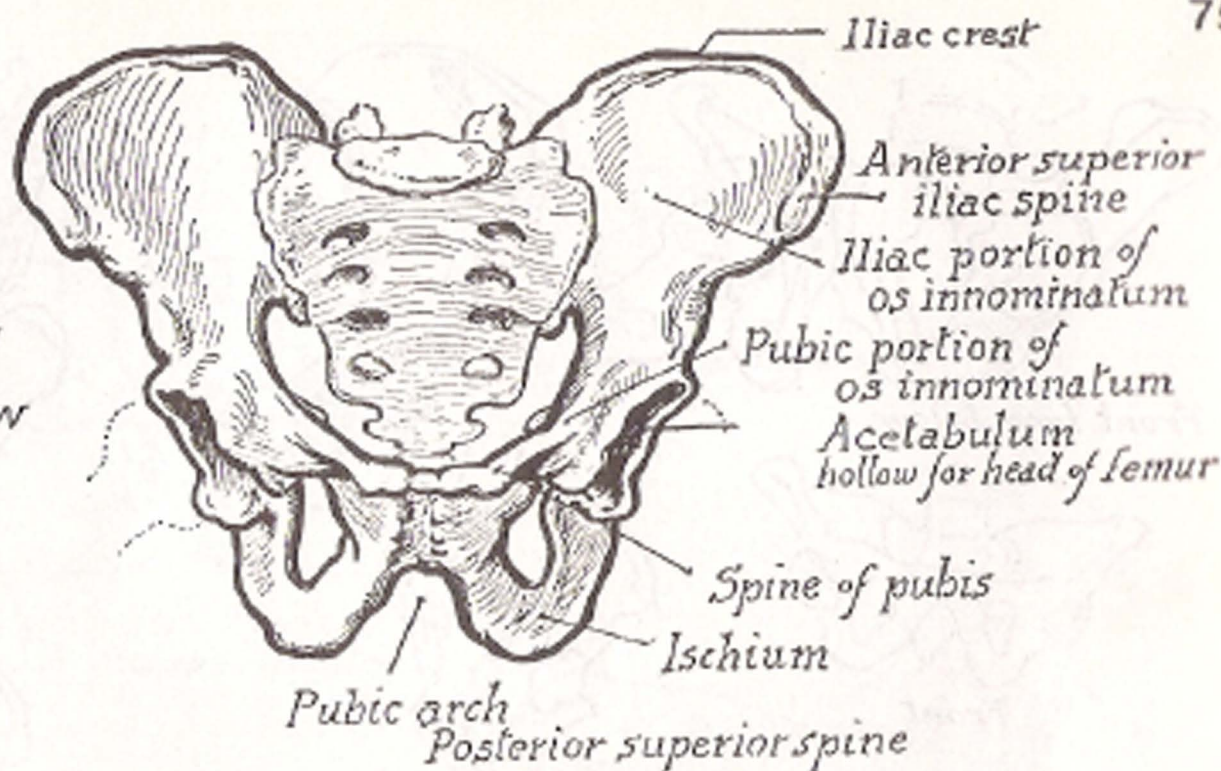
*Transversus abdominis underlying No 1*

*underlying No 2*

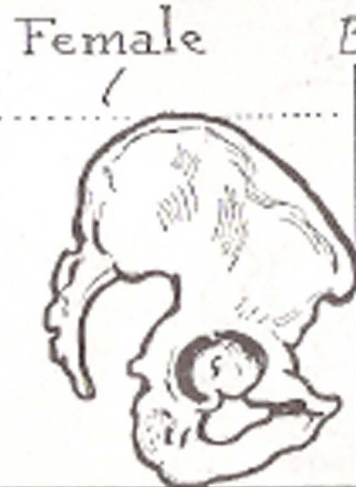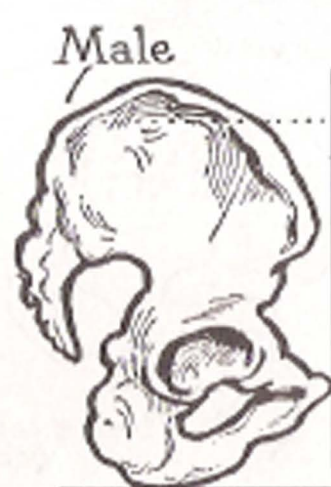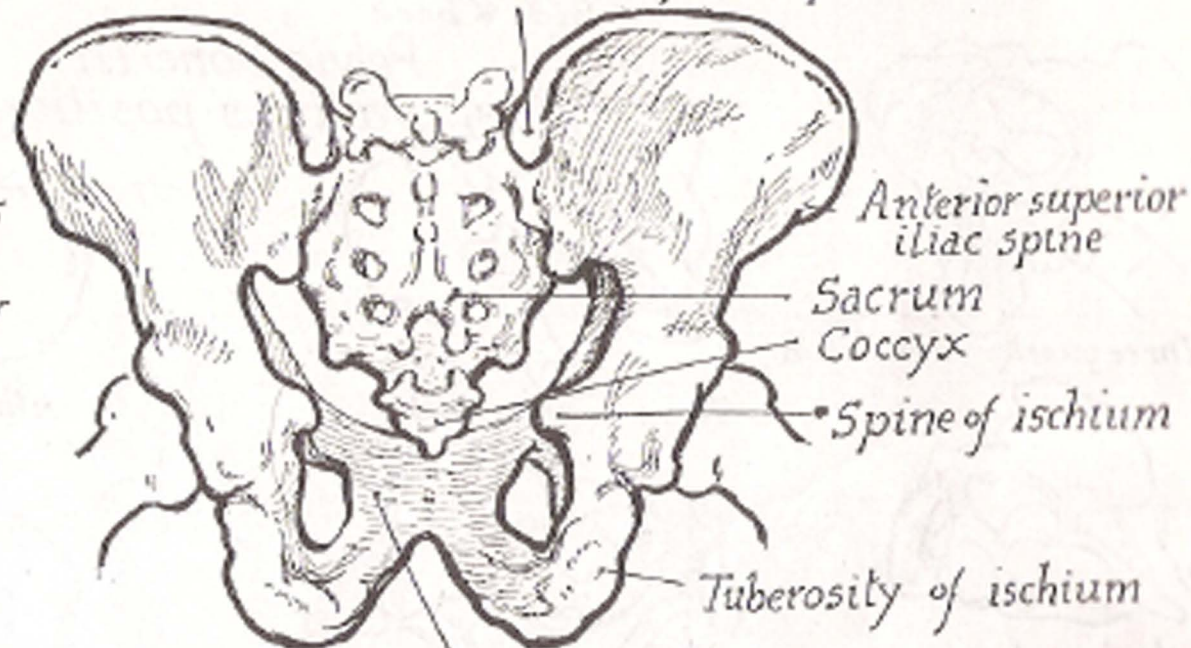




*Male Pelvis*  
*Front view*

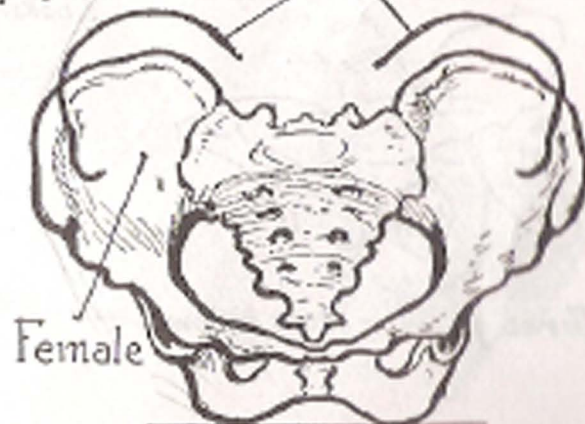

*Male Pelvis*  
*Back View*




Showing female bone tilted forward

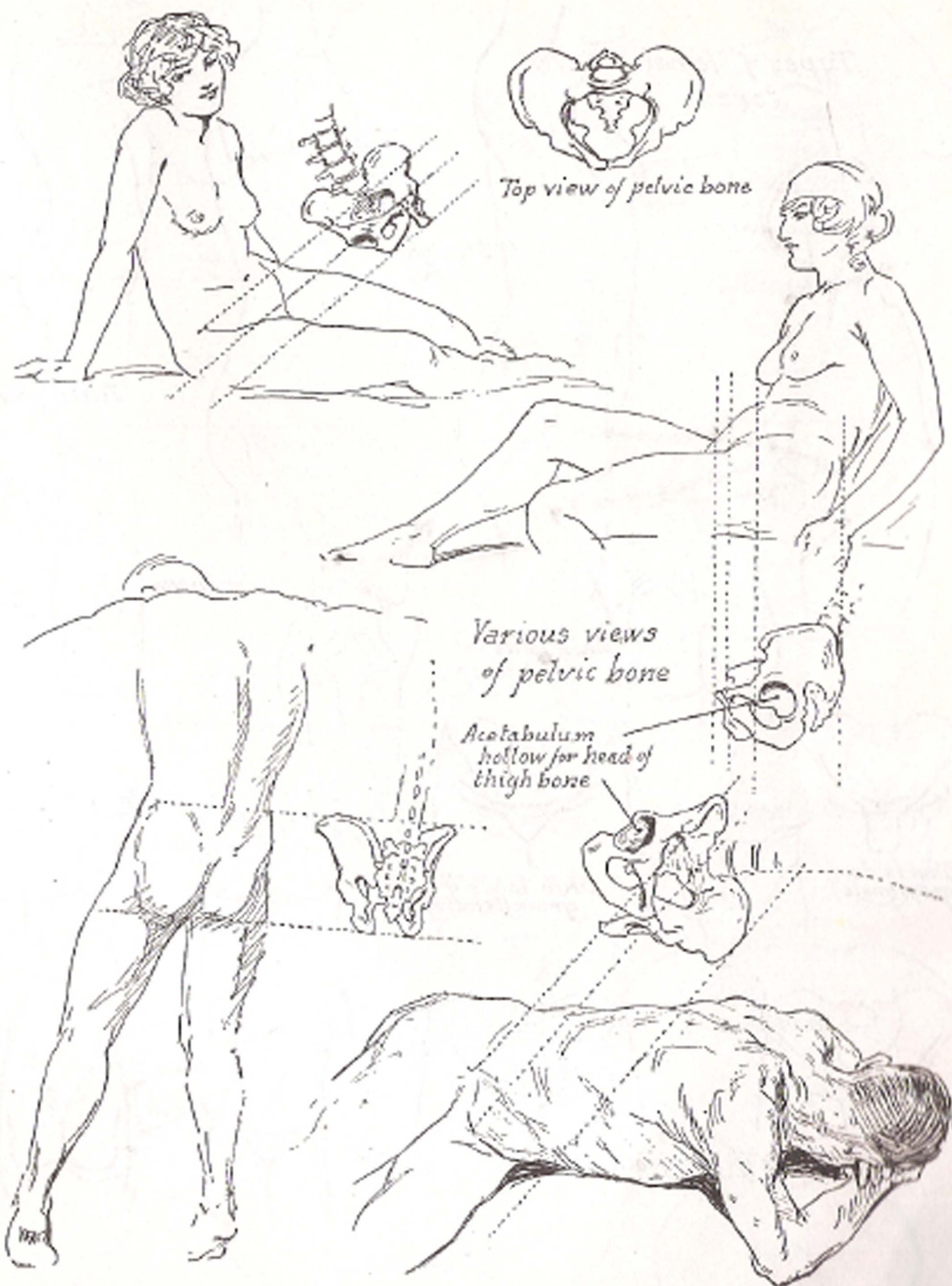
Body of pubic bone Male



Difference of height and breadth

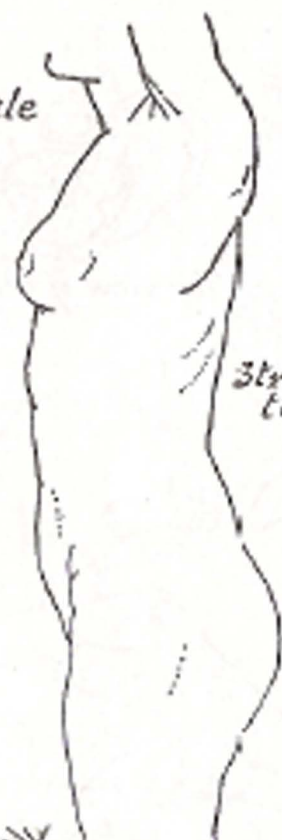
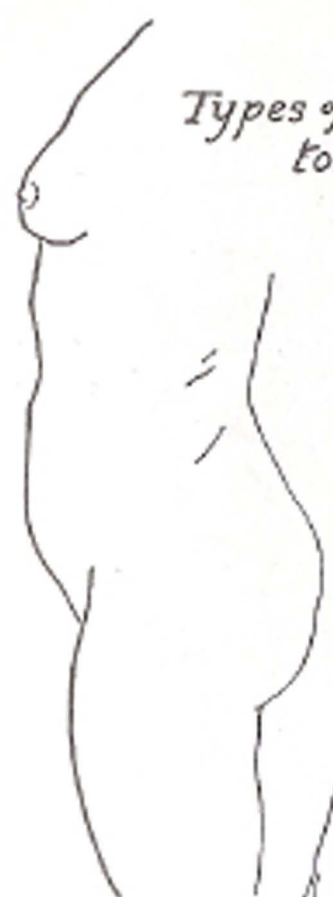
Digitized by www.srujanika@gmail.com  
 Digitized by www.srujanika@gmail.com

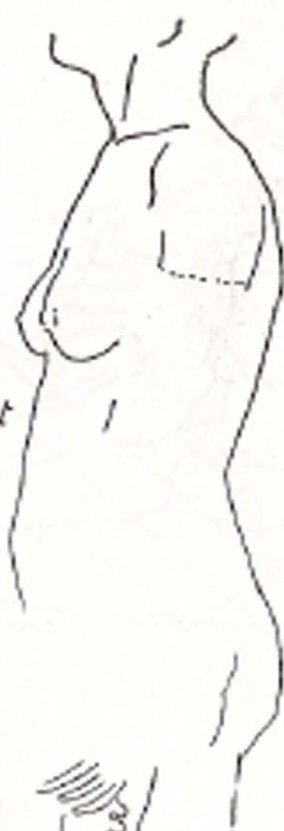

Victor Pavard

## Types of female torso



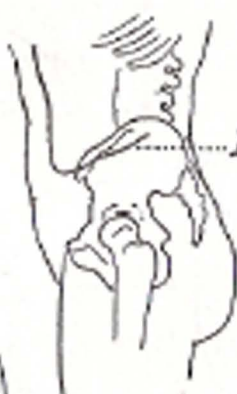Straight torso



Tilted pelvis



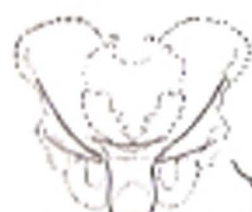Skin folds in bent torso



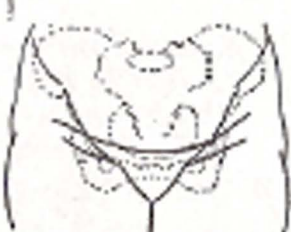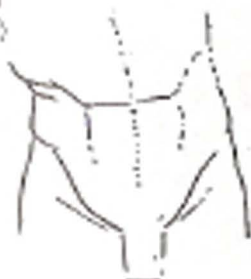Iliac furrow



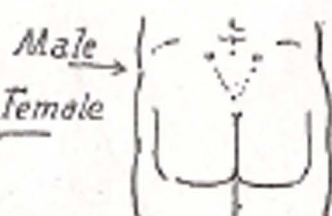
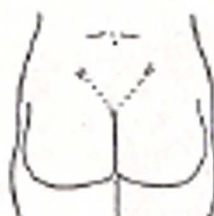Resting on one leg



Skin folds of groin (male)

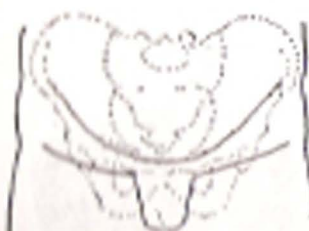


Skin folds of groin (female)

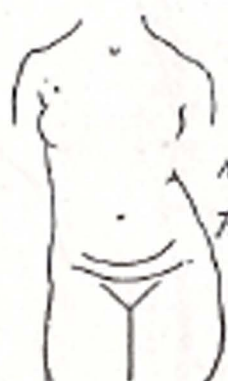

Male

Female



Male - folds of the groin - female

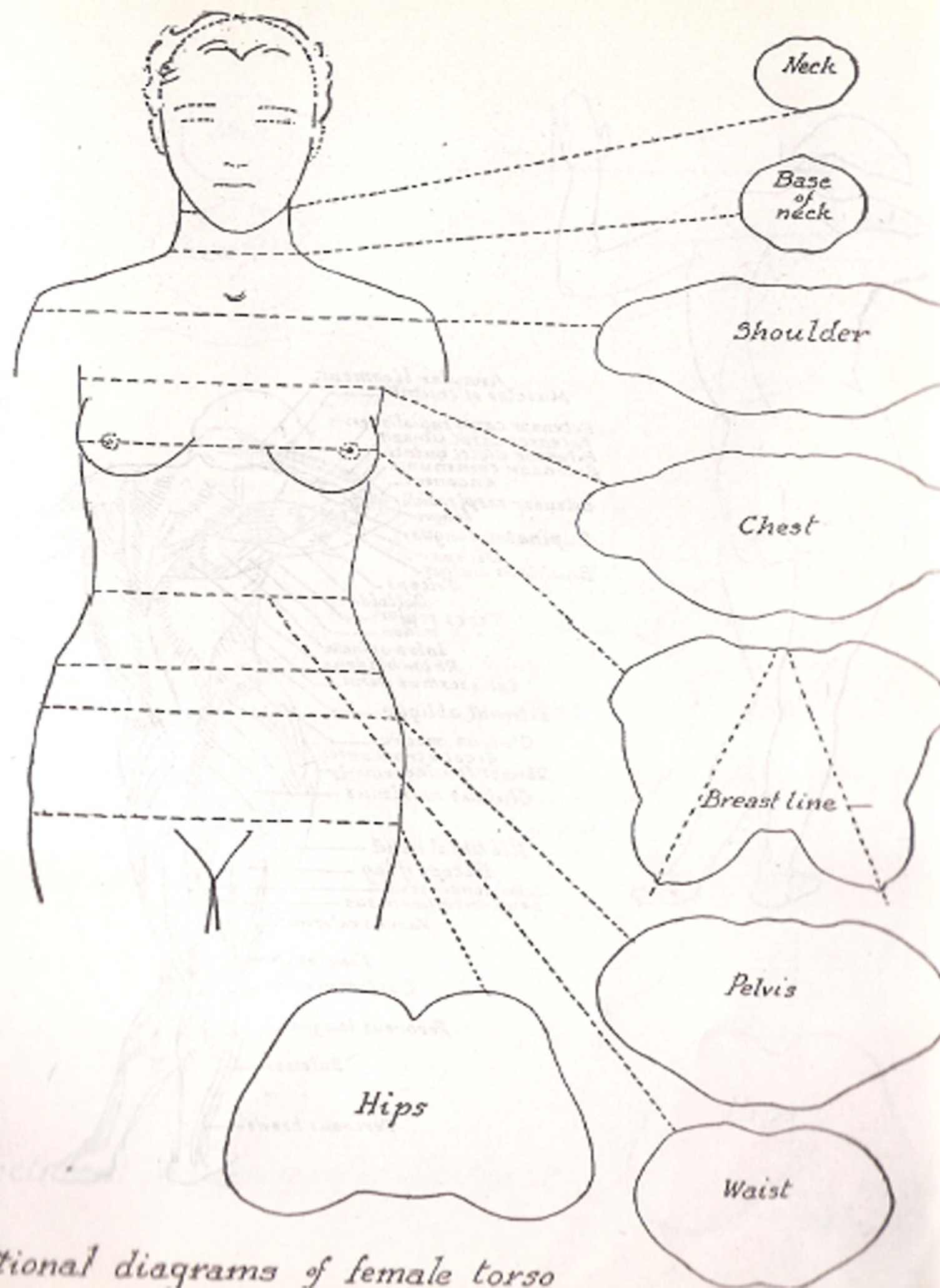


Male

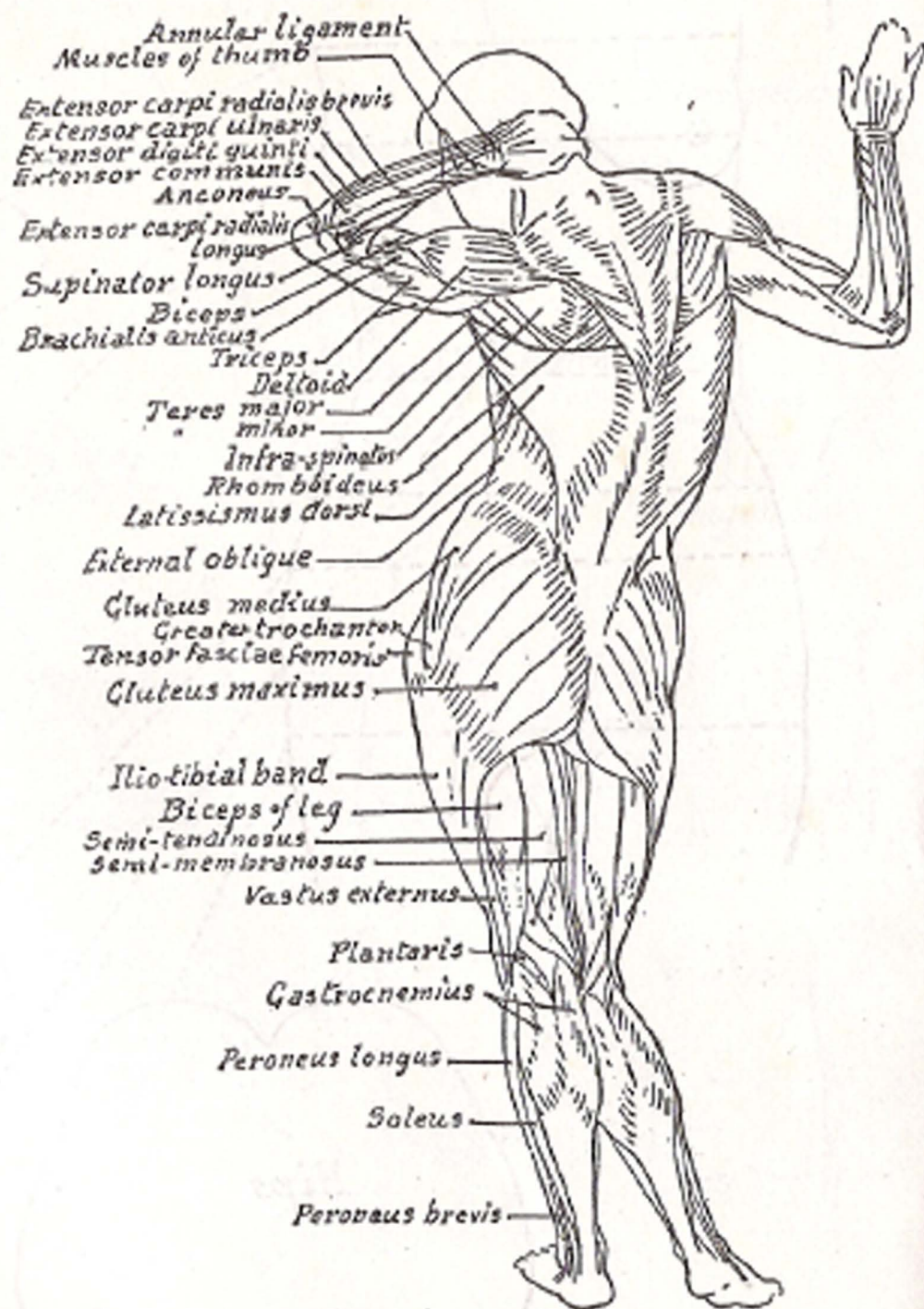
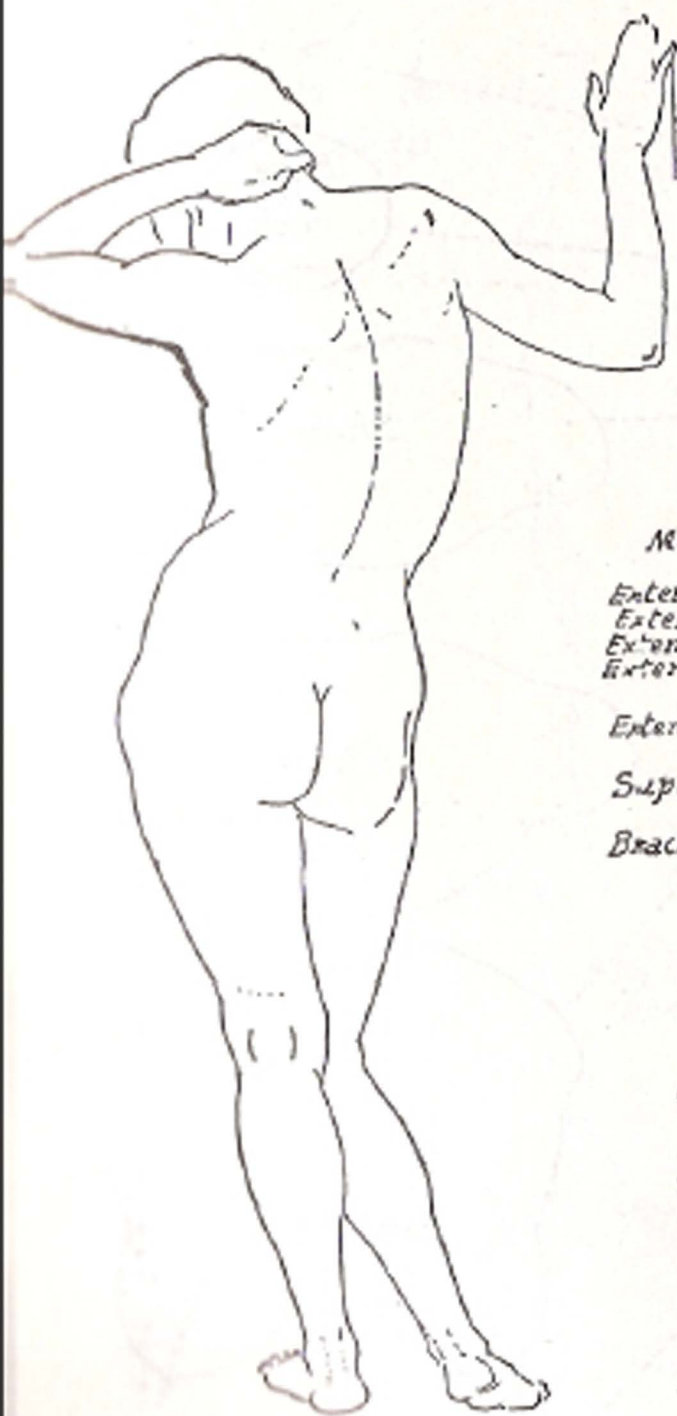
Female

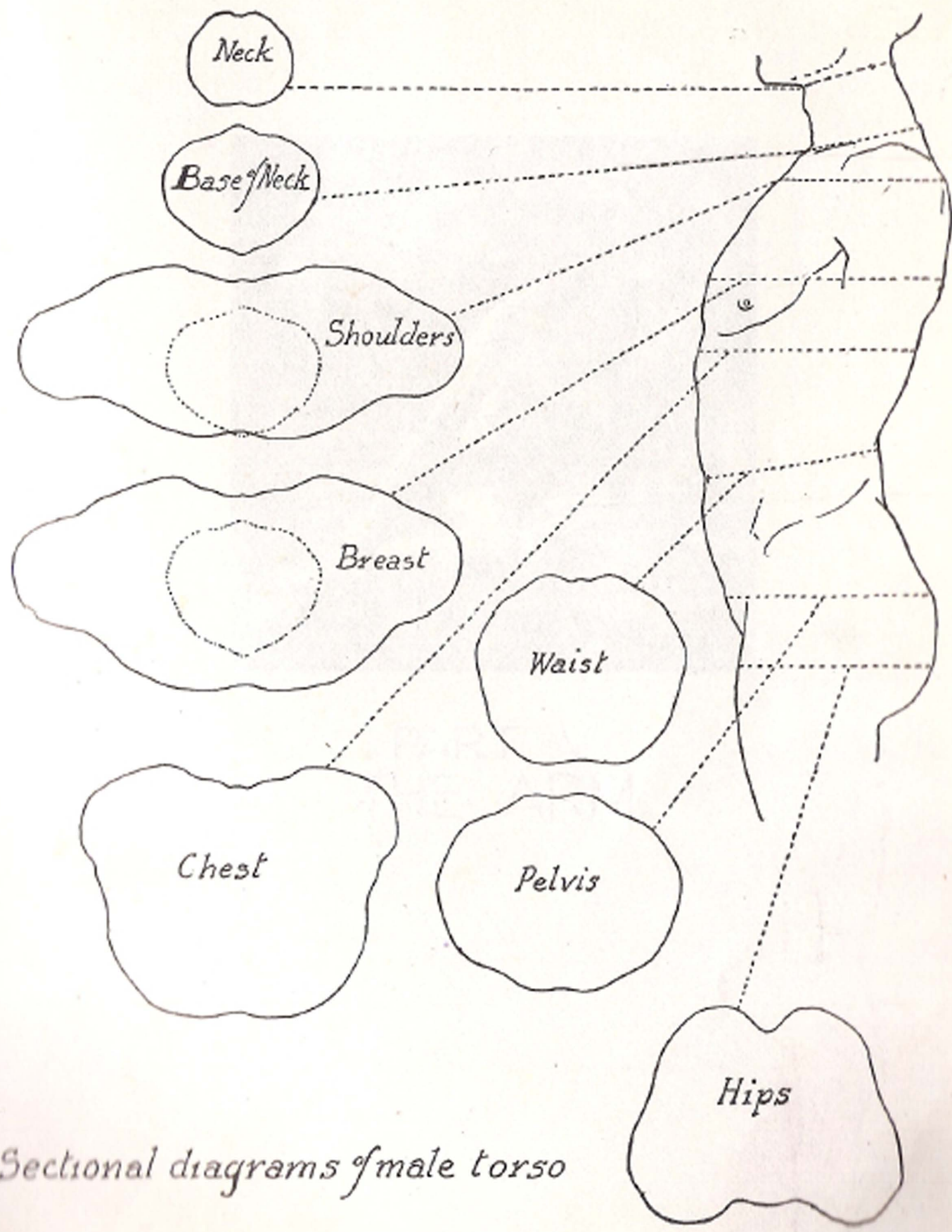






*Sectional diagrams of female torso*

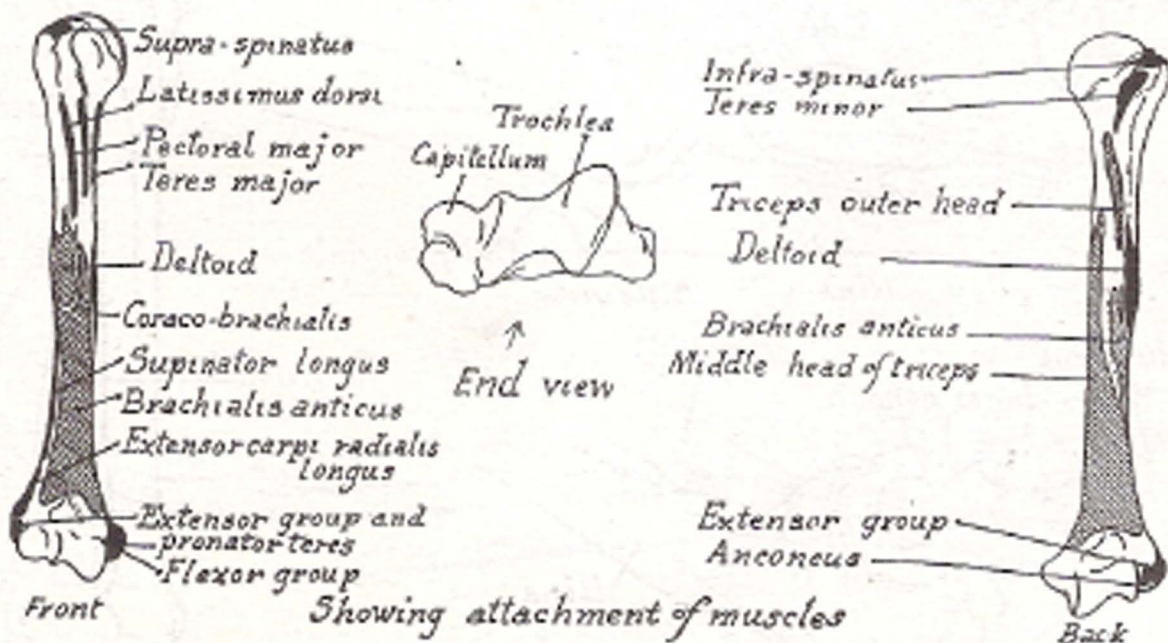
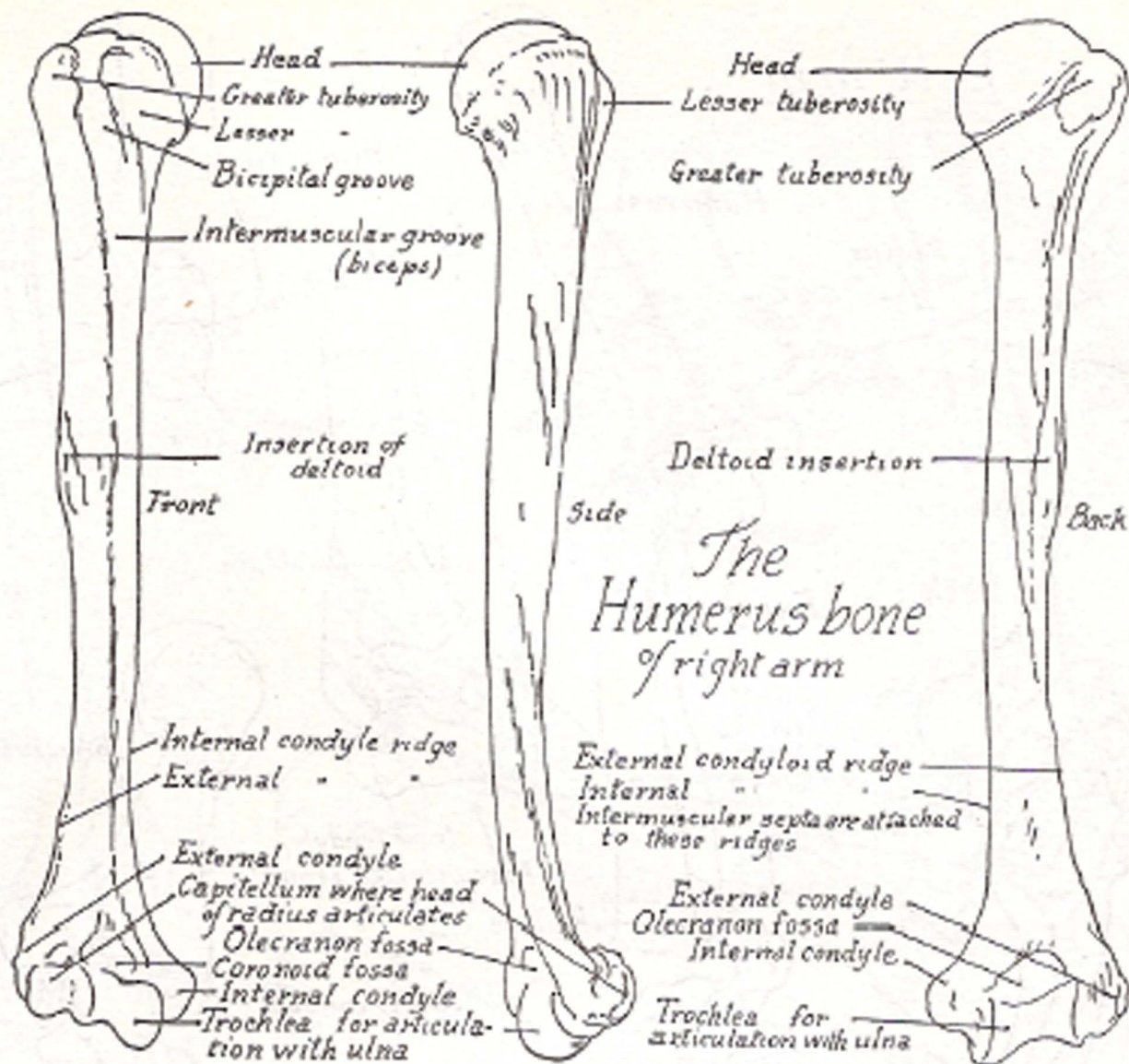


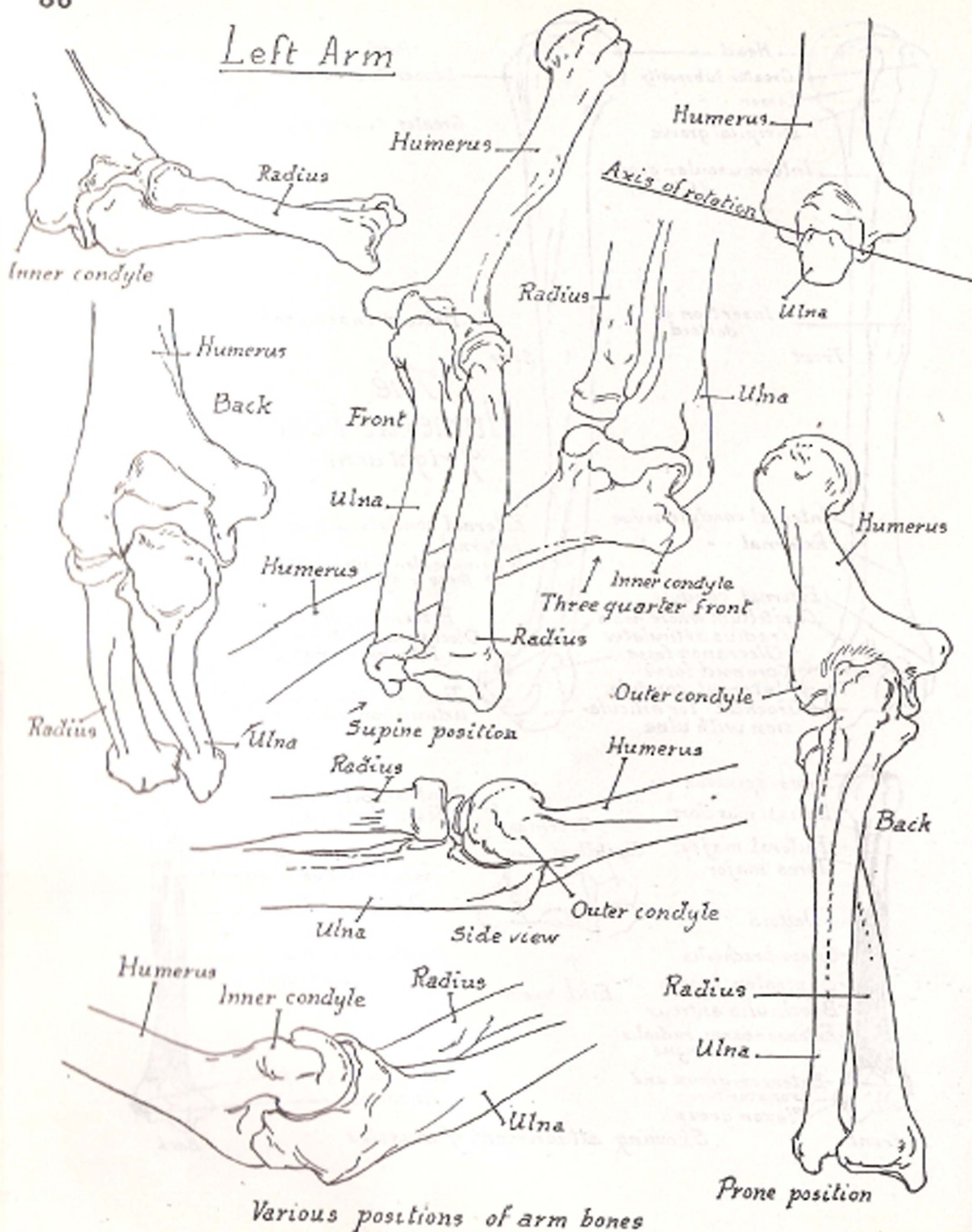


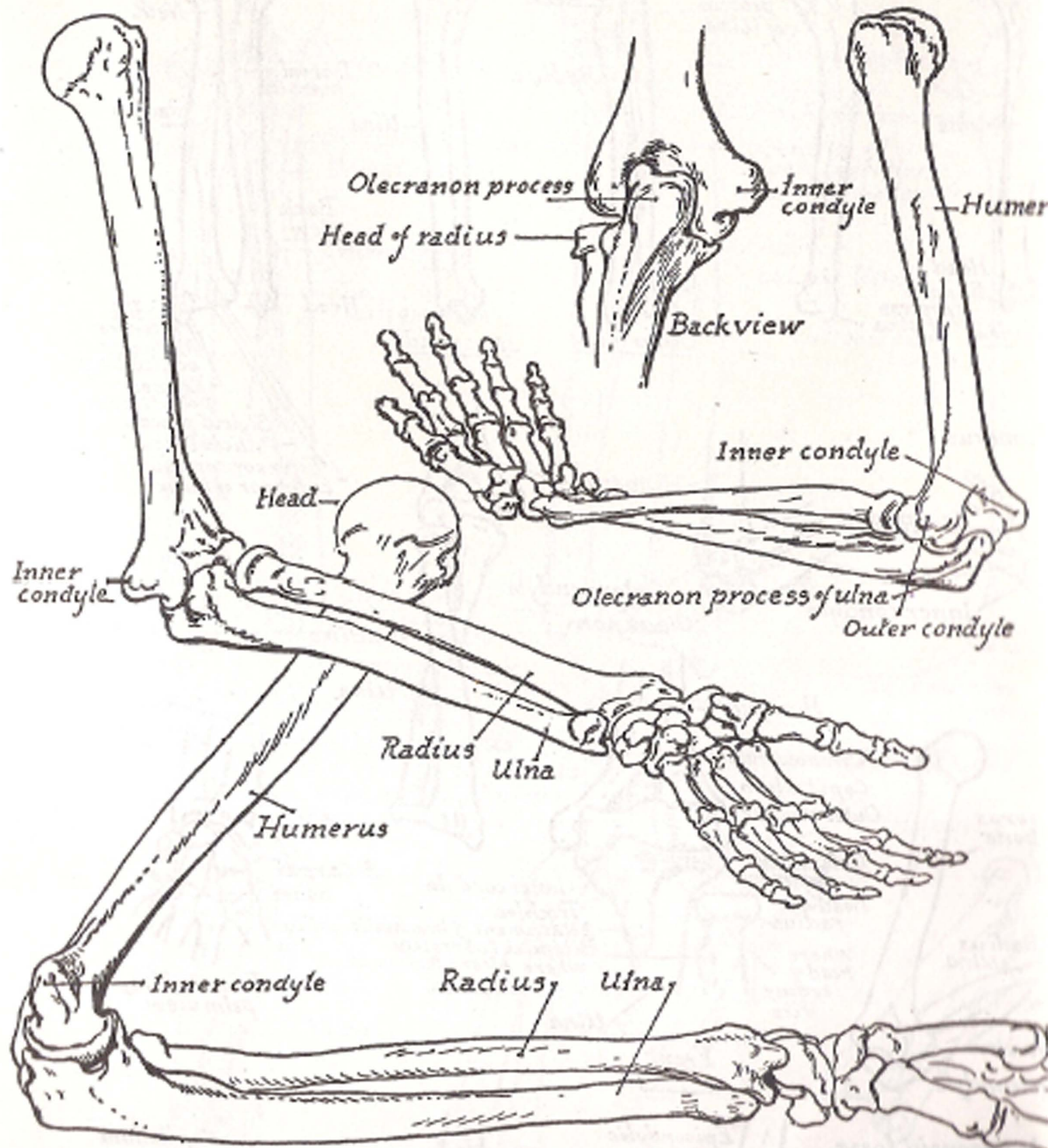
*Sectional diagrams of male torso*



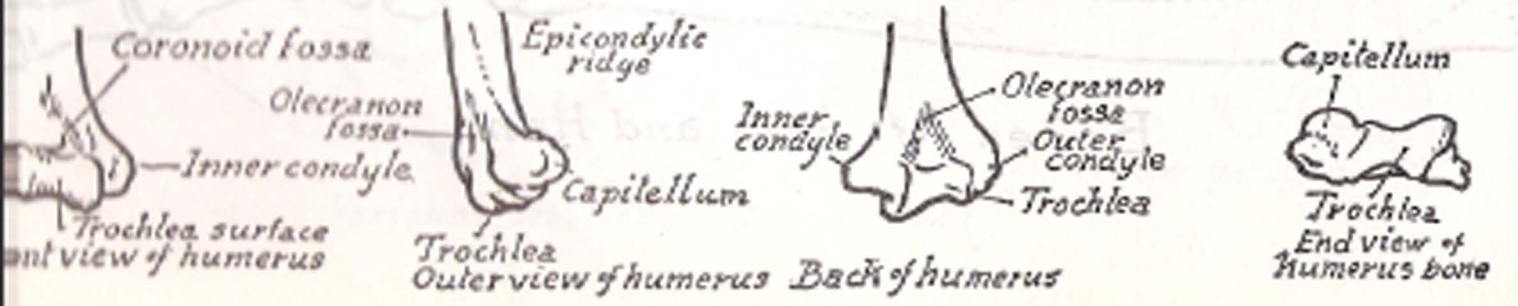
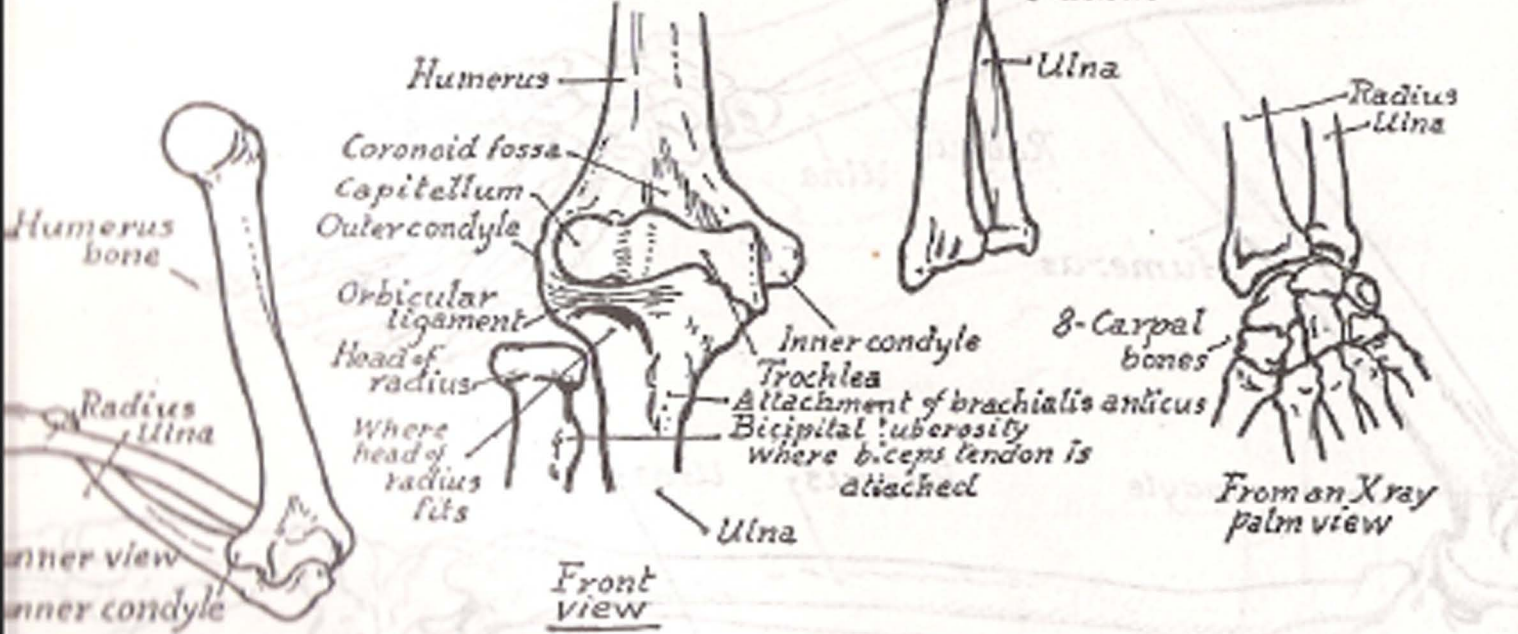
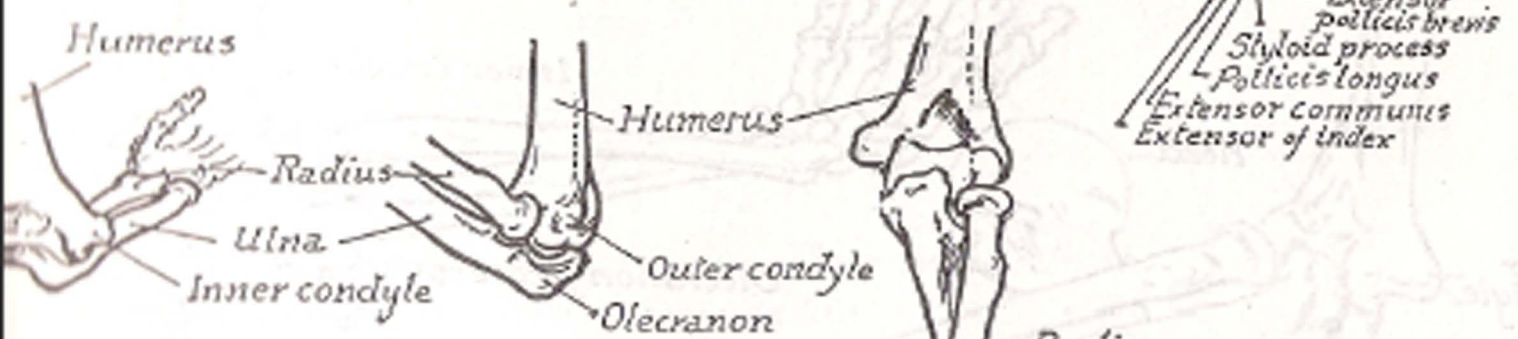
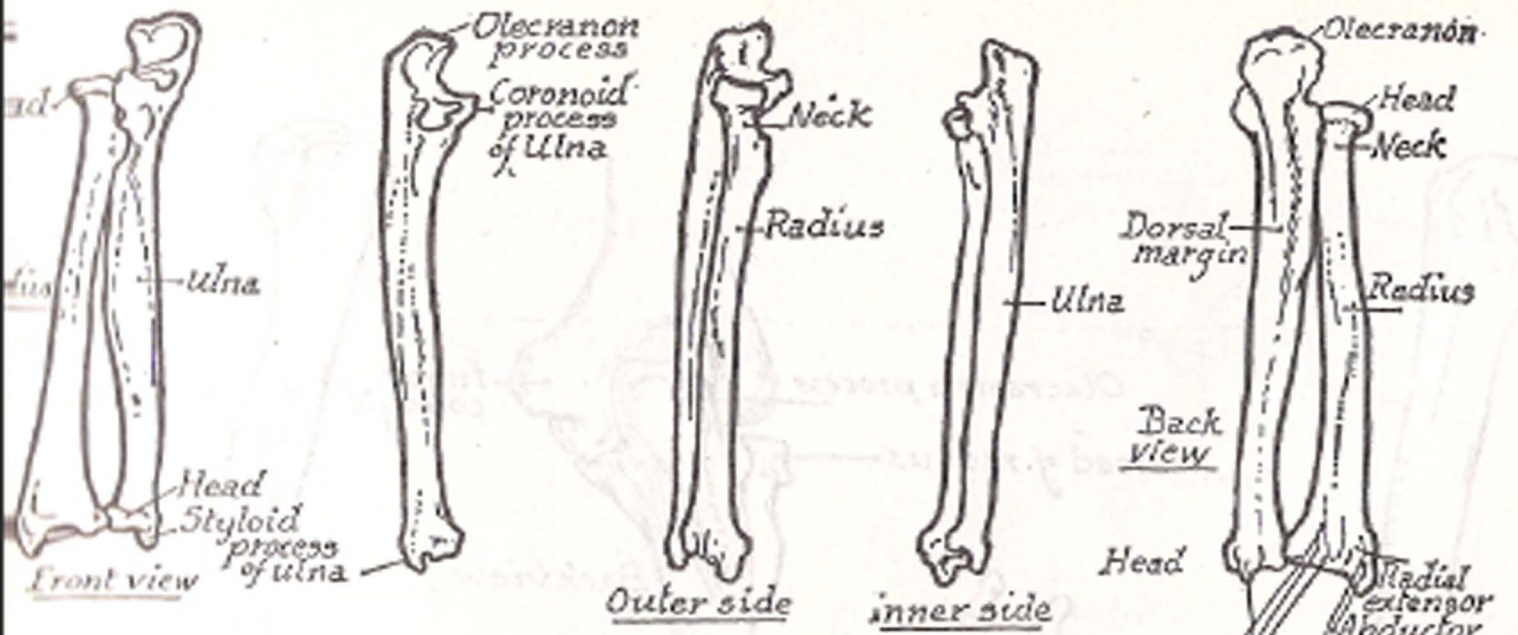
PART V  
THE ARM



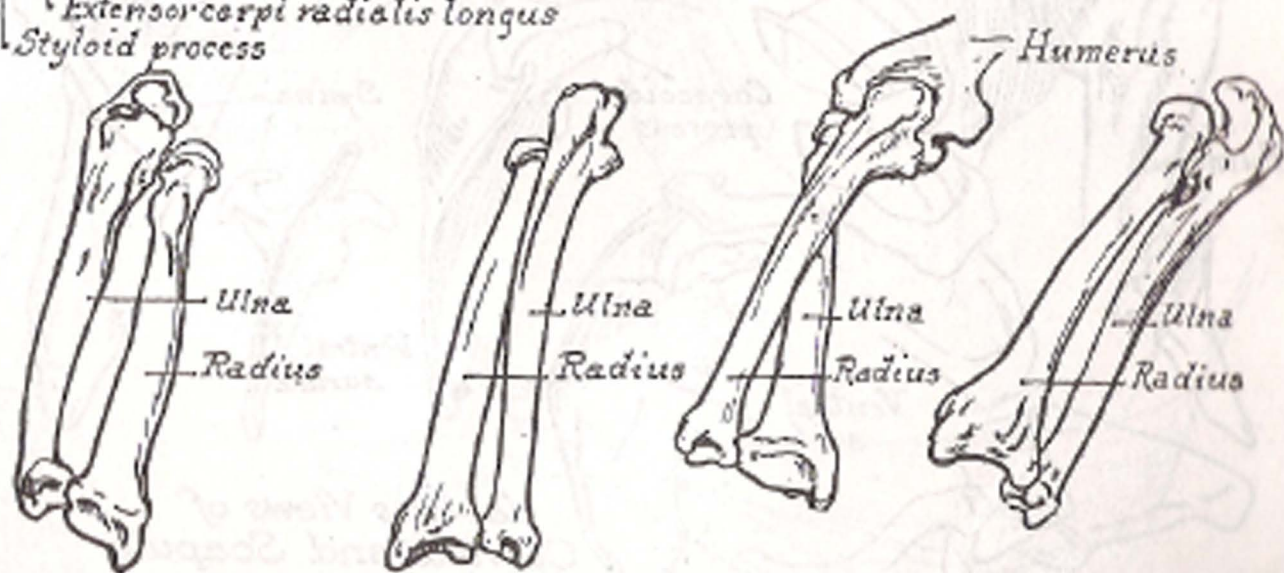
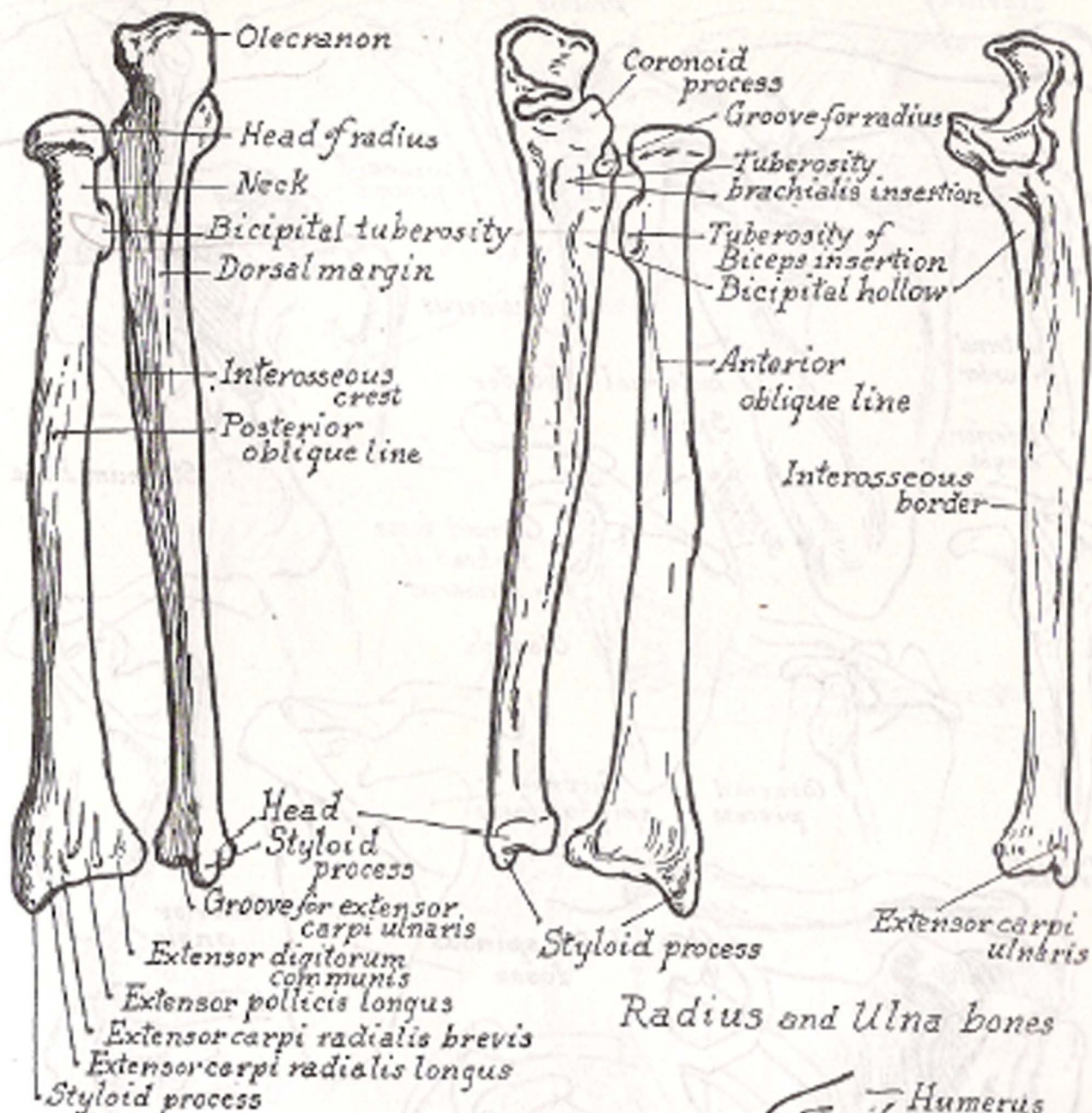
Left Arm



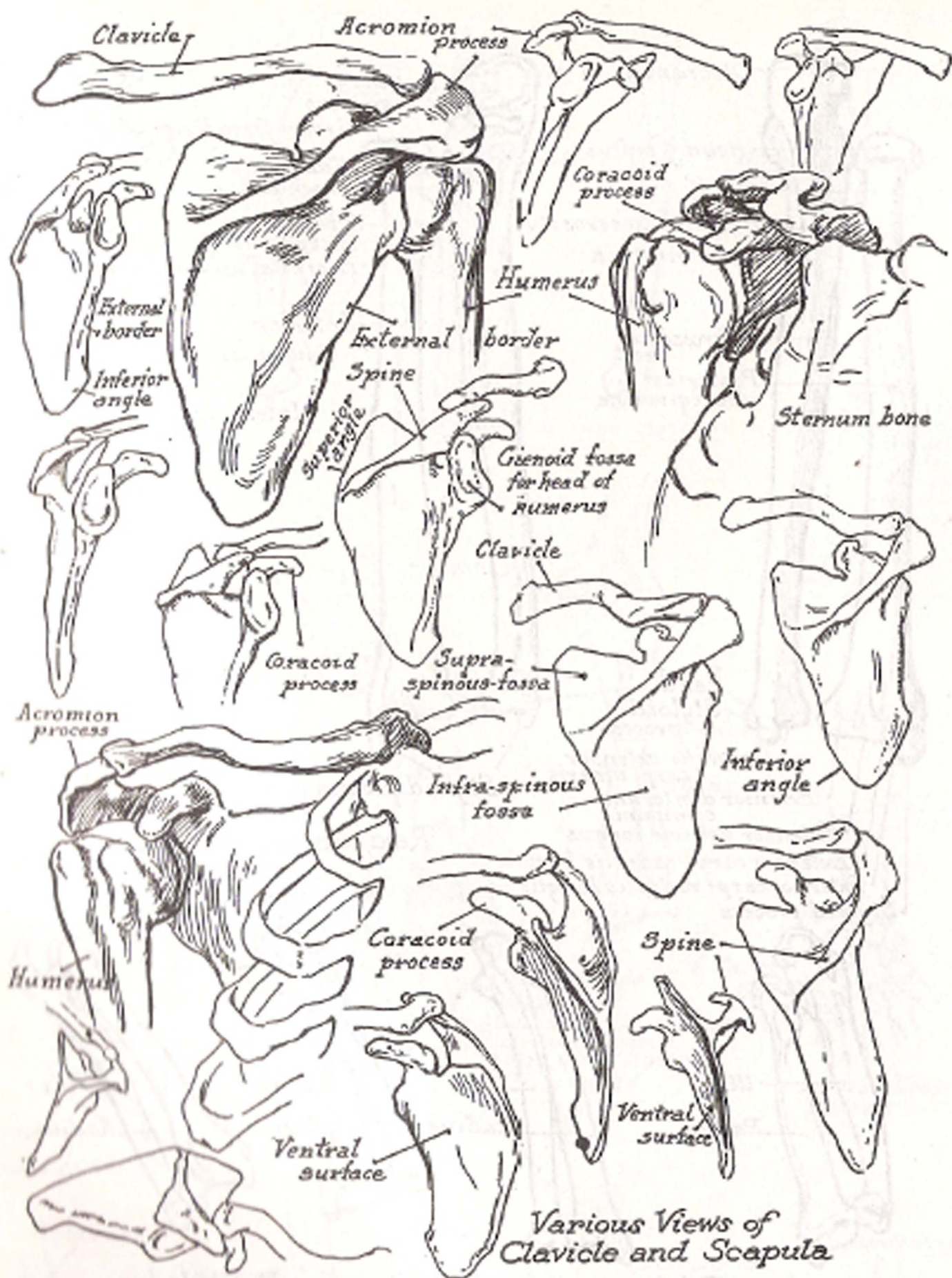
Bones of Arm and Hand



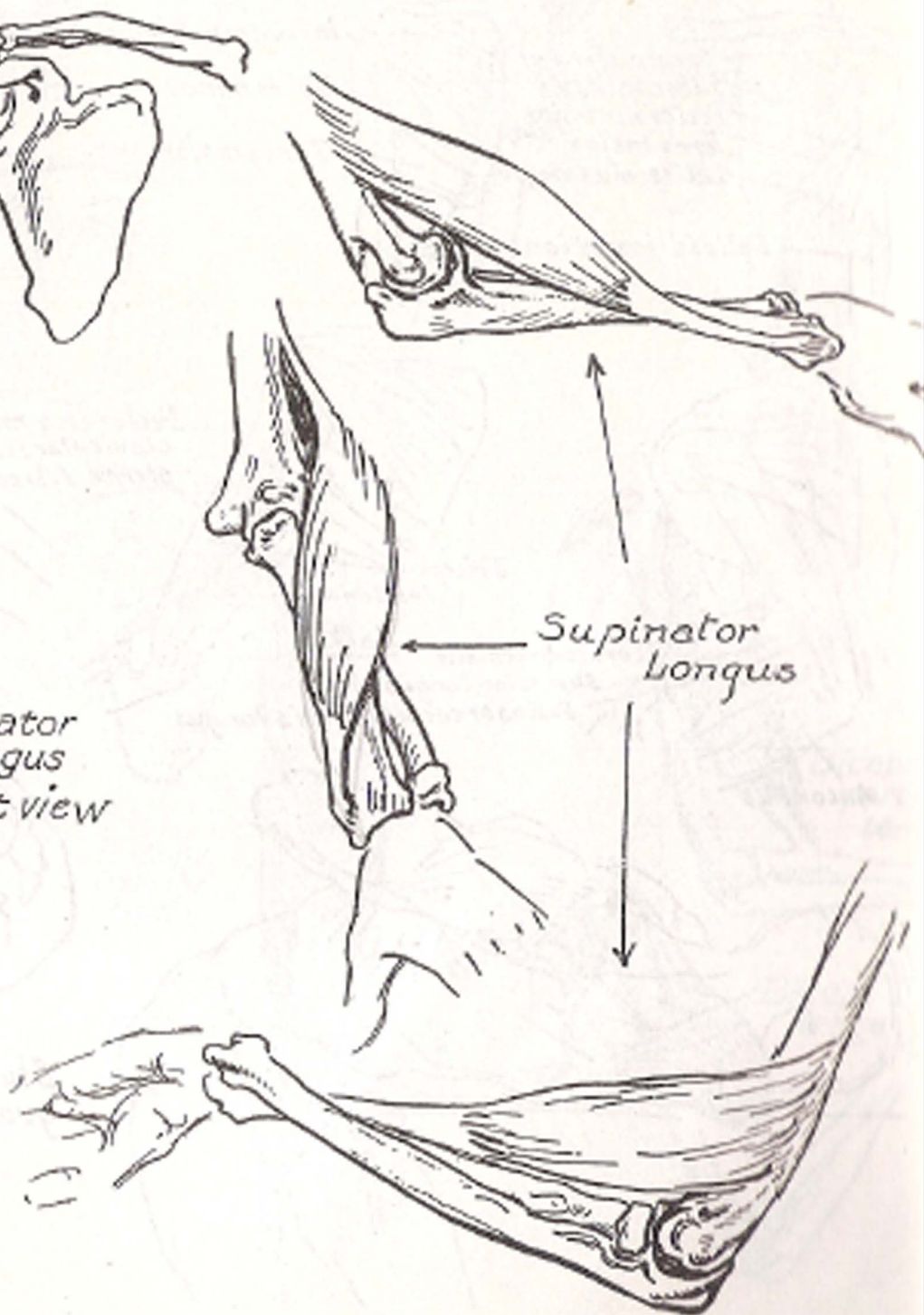
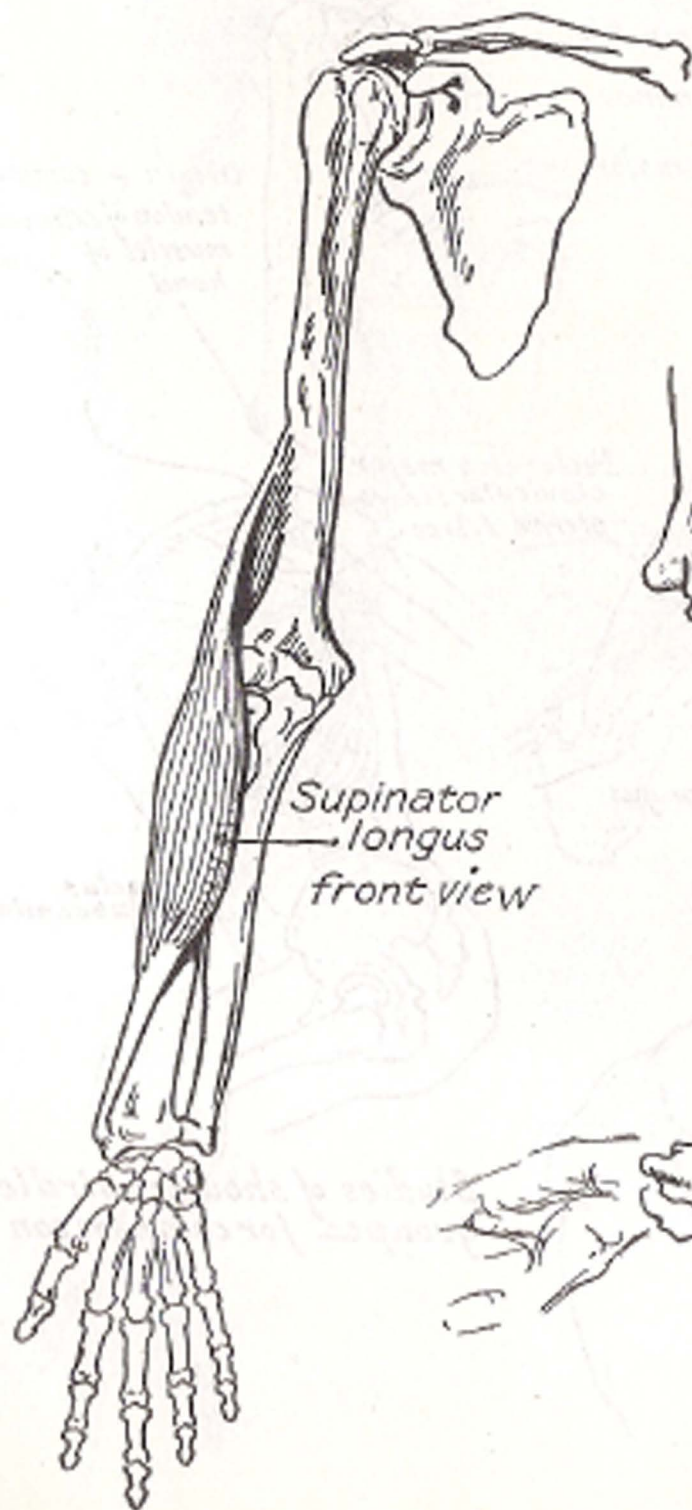
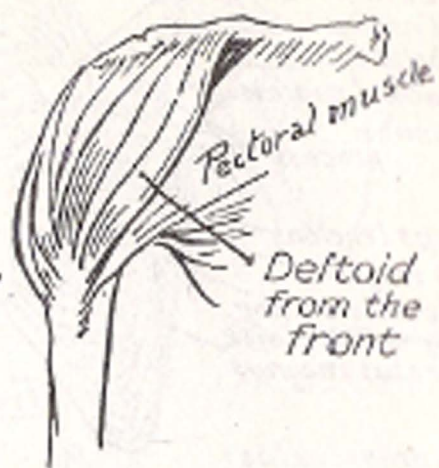
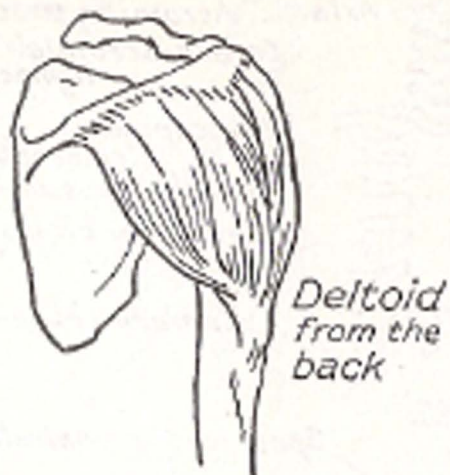
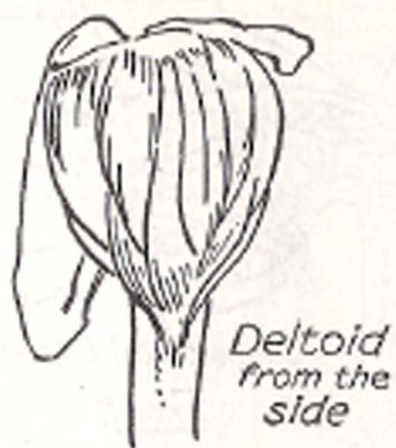


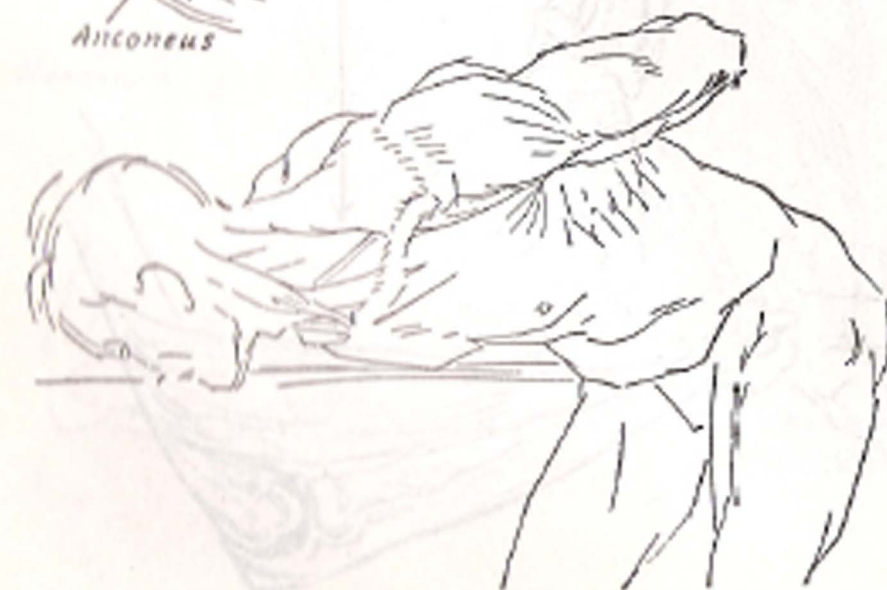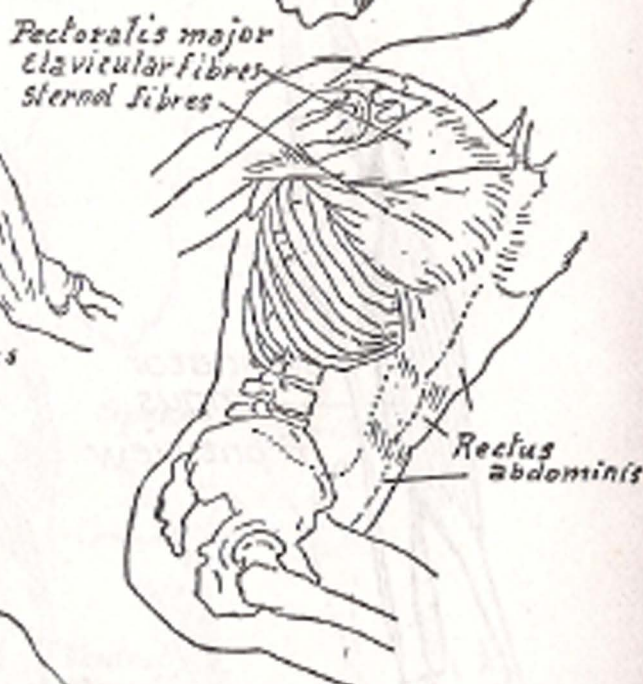
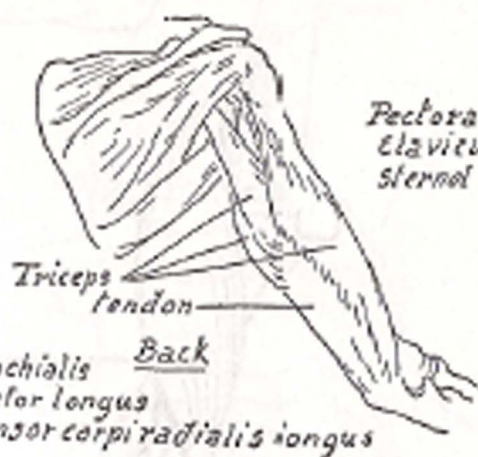
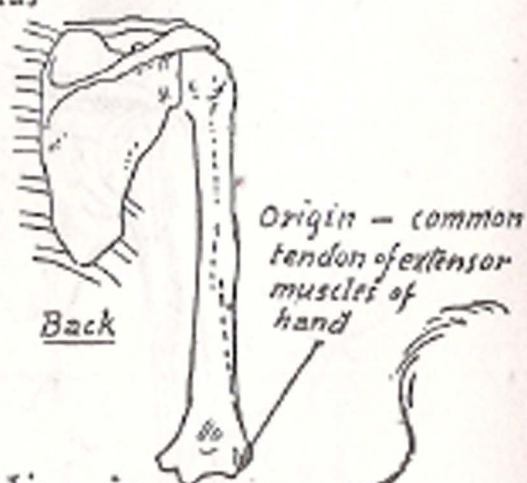
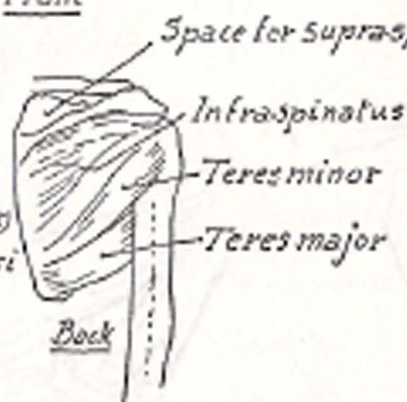
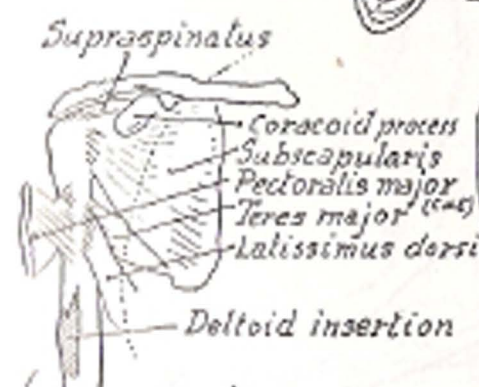
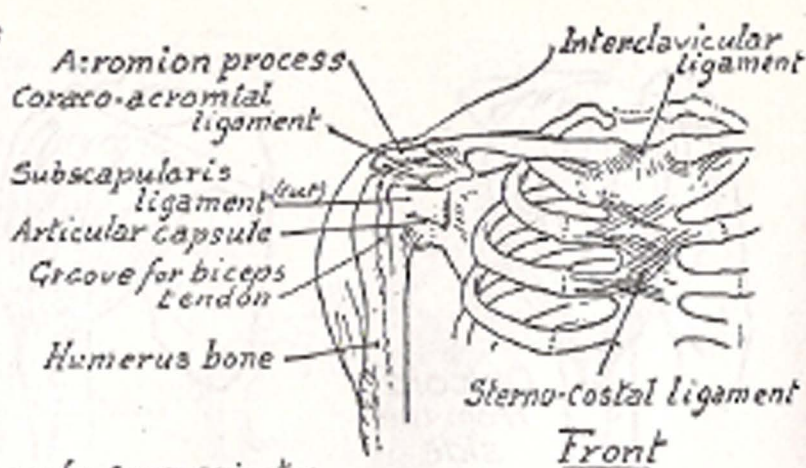
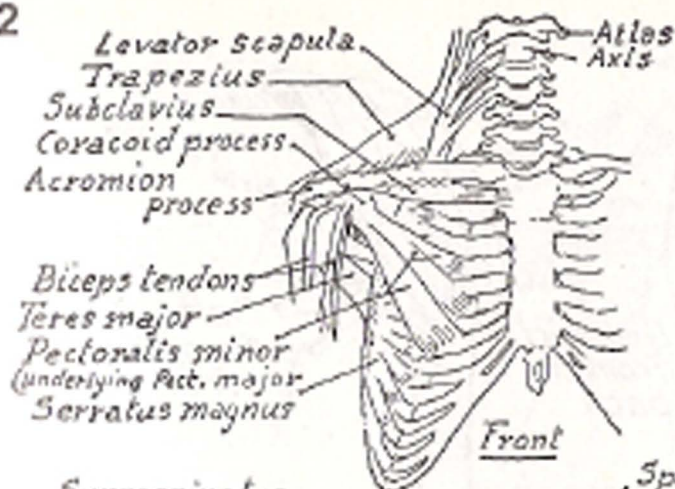


Relations and foreshortenings of radius and ulna

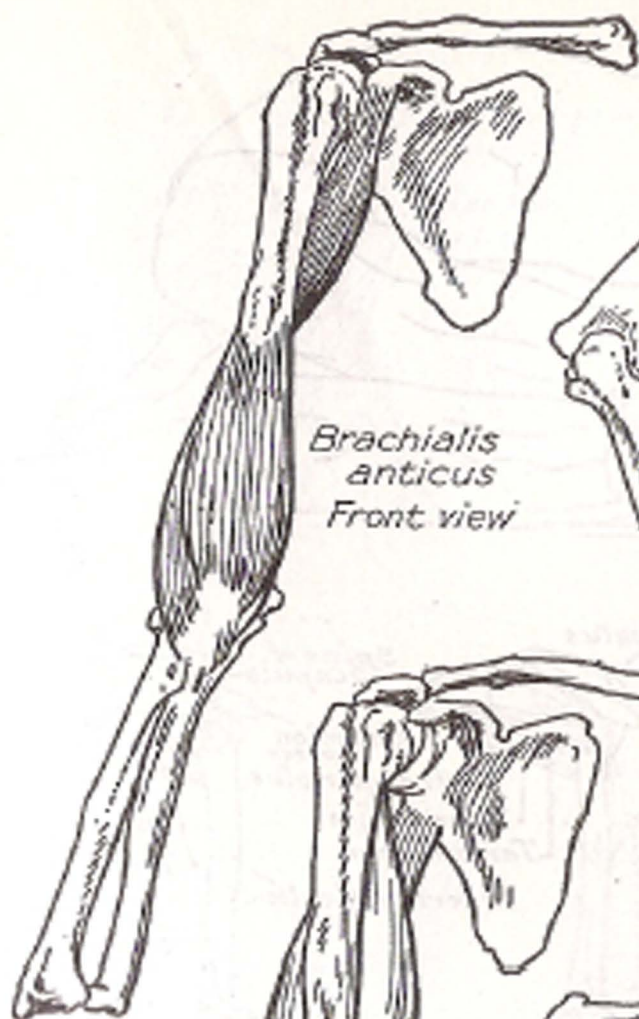


Various Views of  
Clavicle and Scapula

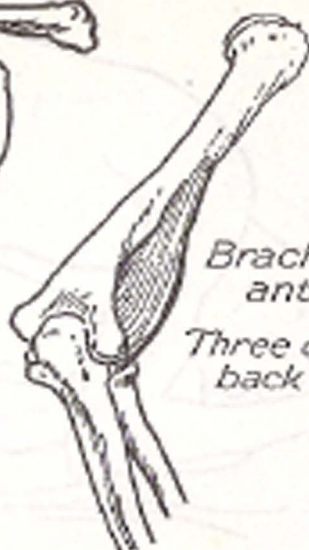




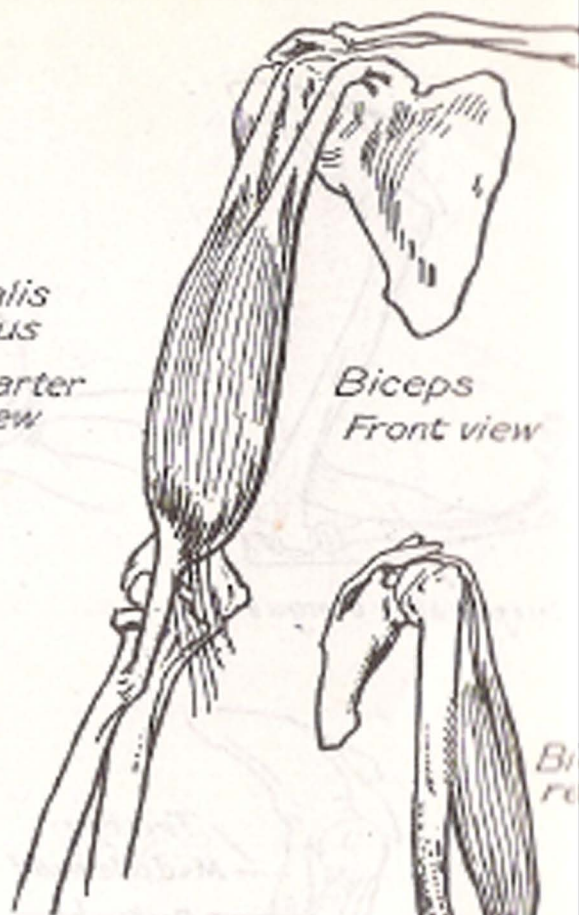
Studies of shoulder girdle, grouped for comparison



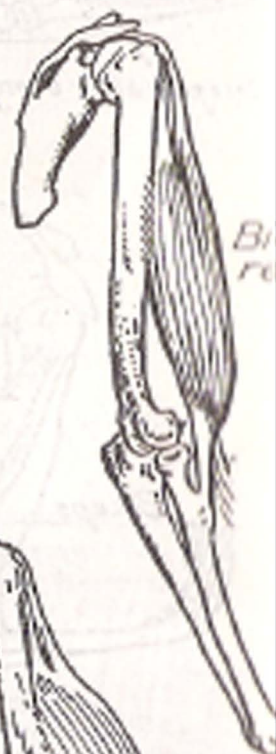*Brachialis  
anticus  
Front view*



*Brachialis  
anticus  
Three quarter  
back view*

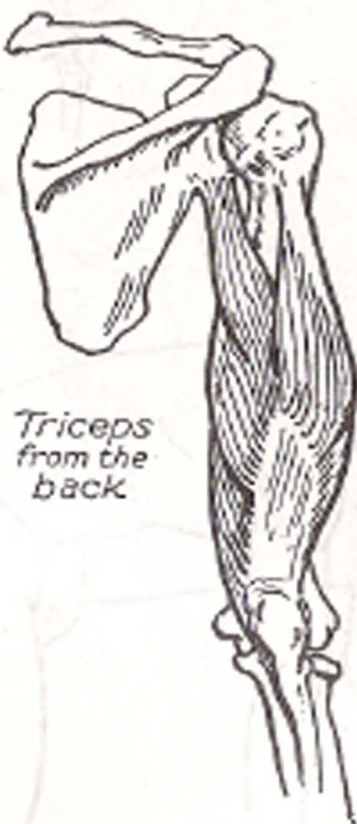
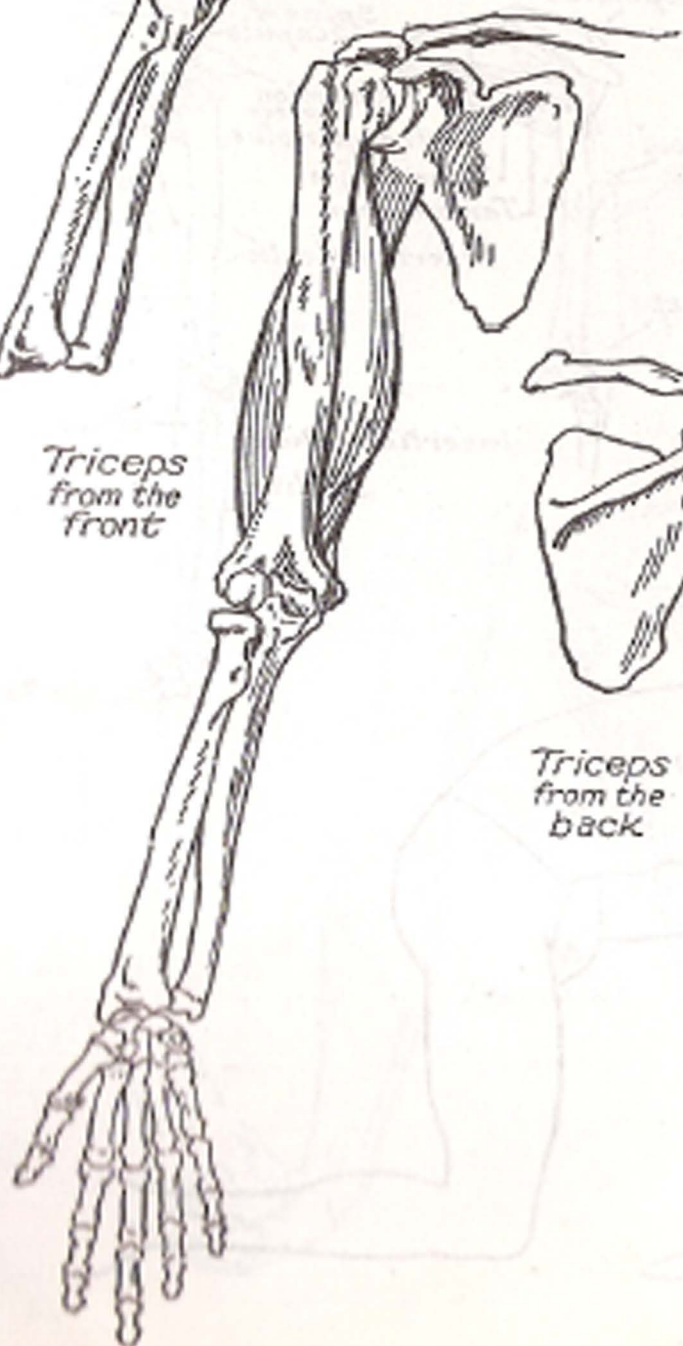


*Biceps  
Front view*

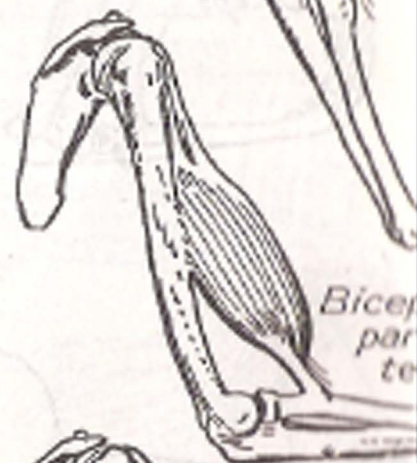


*Bi  
re*

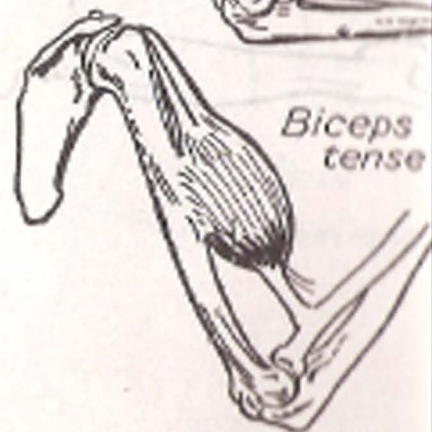
*Triceps  
from the  
front*



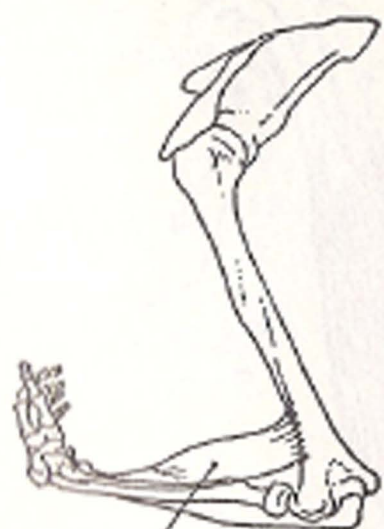*Triceps  
from the  
back*



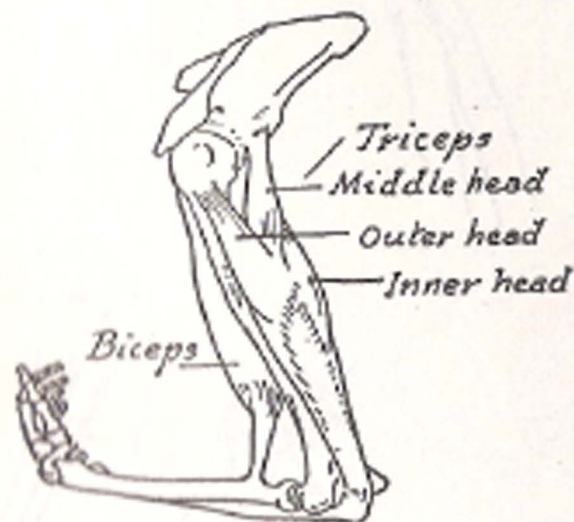
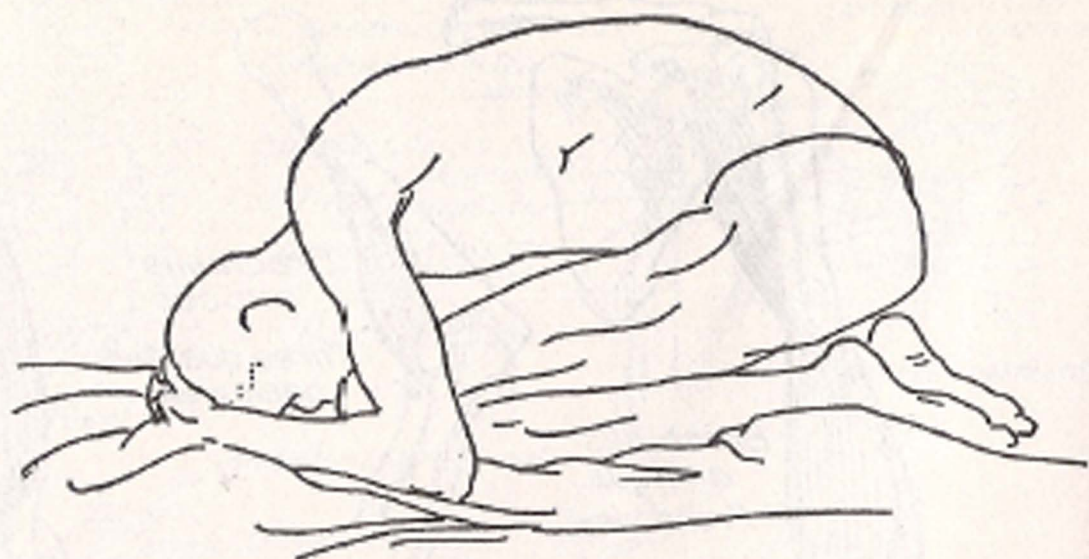
*Biceps  
par  
te*



*Biceps  
tense*

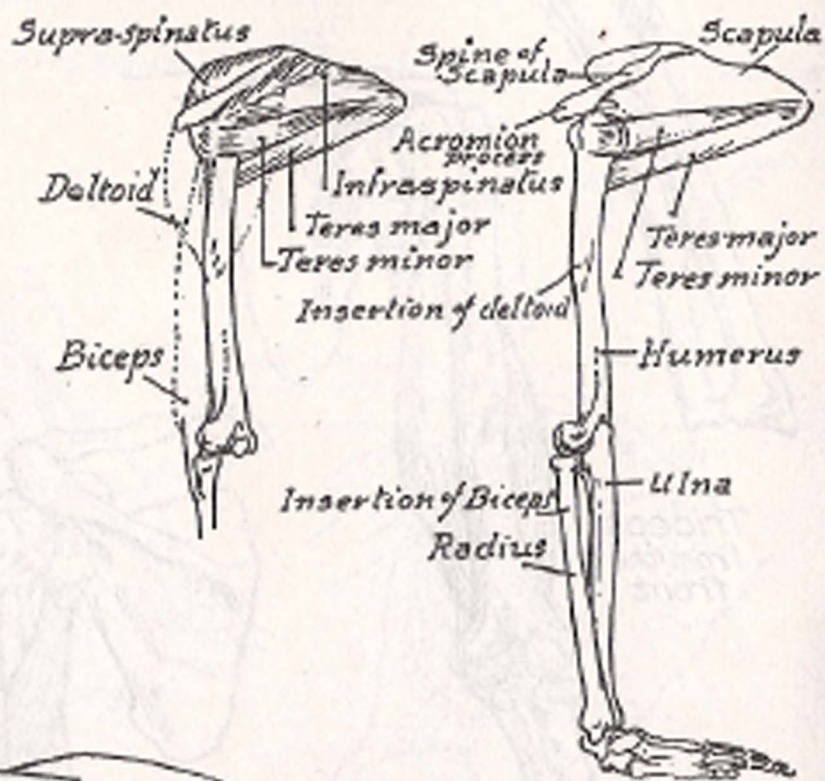


*Supinator longus*

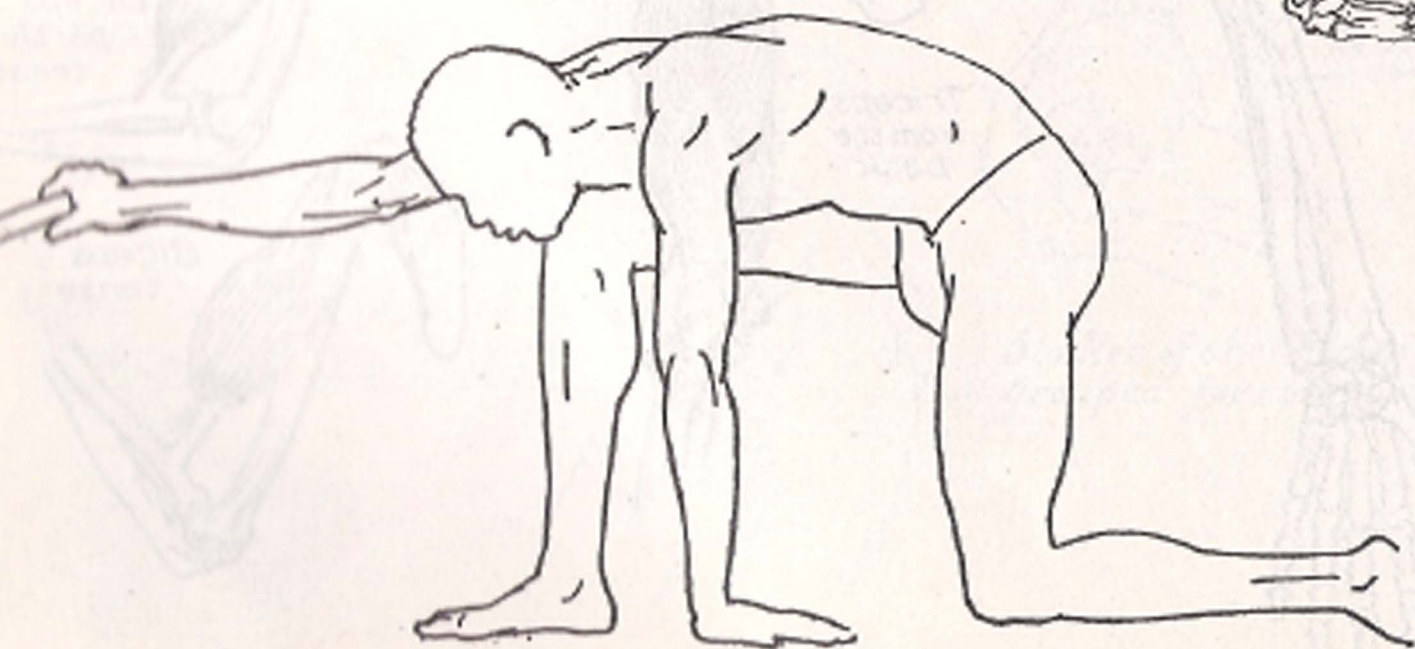


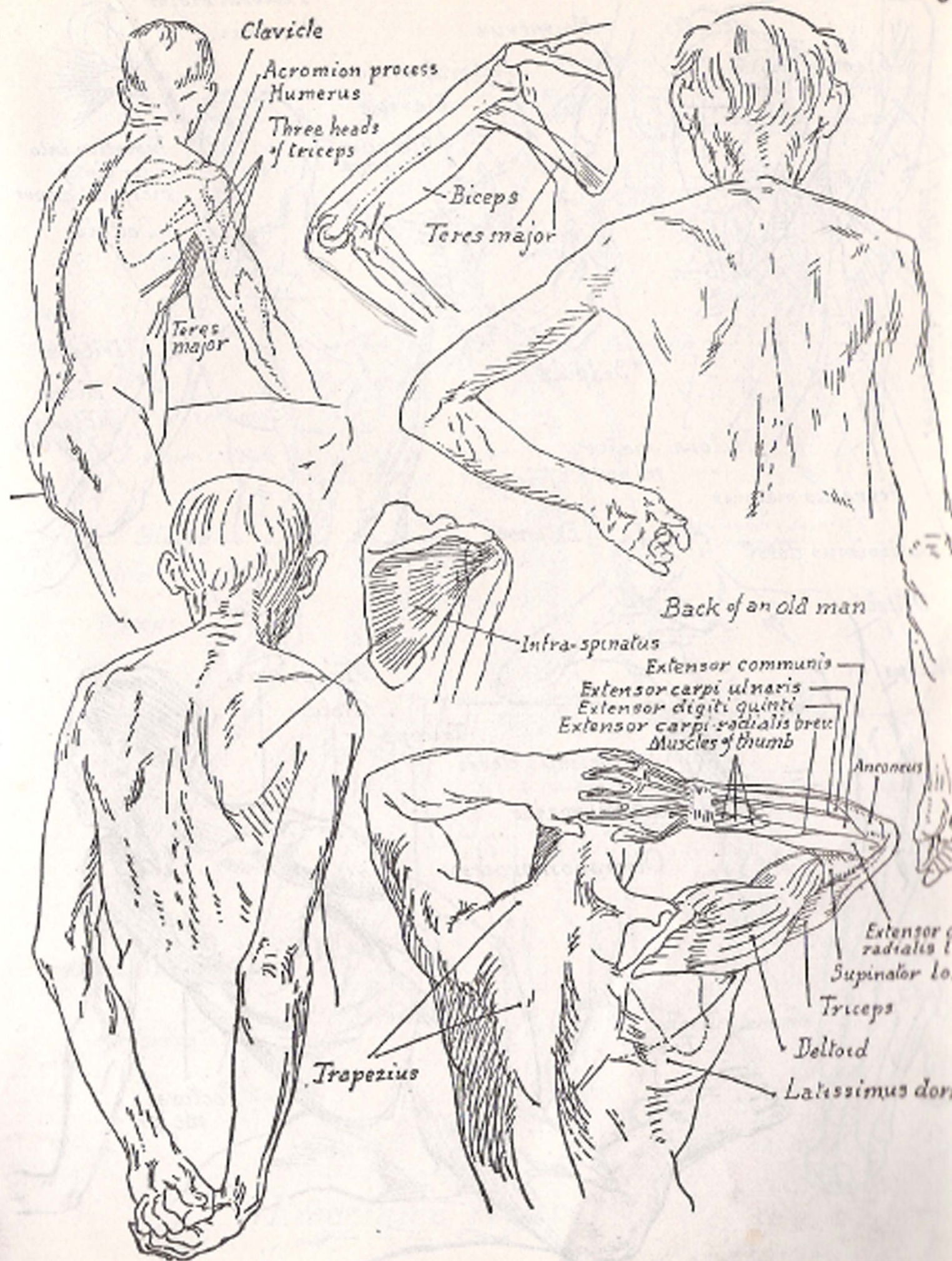
*Triceps*  
*Middle head*  
*Outer head*  
*Inner head*

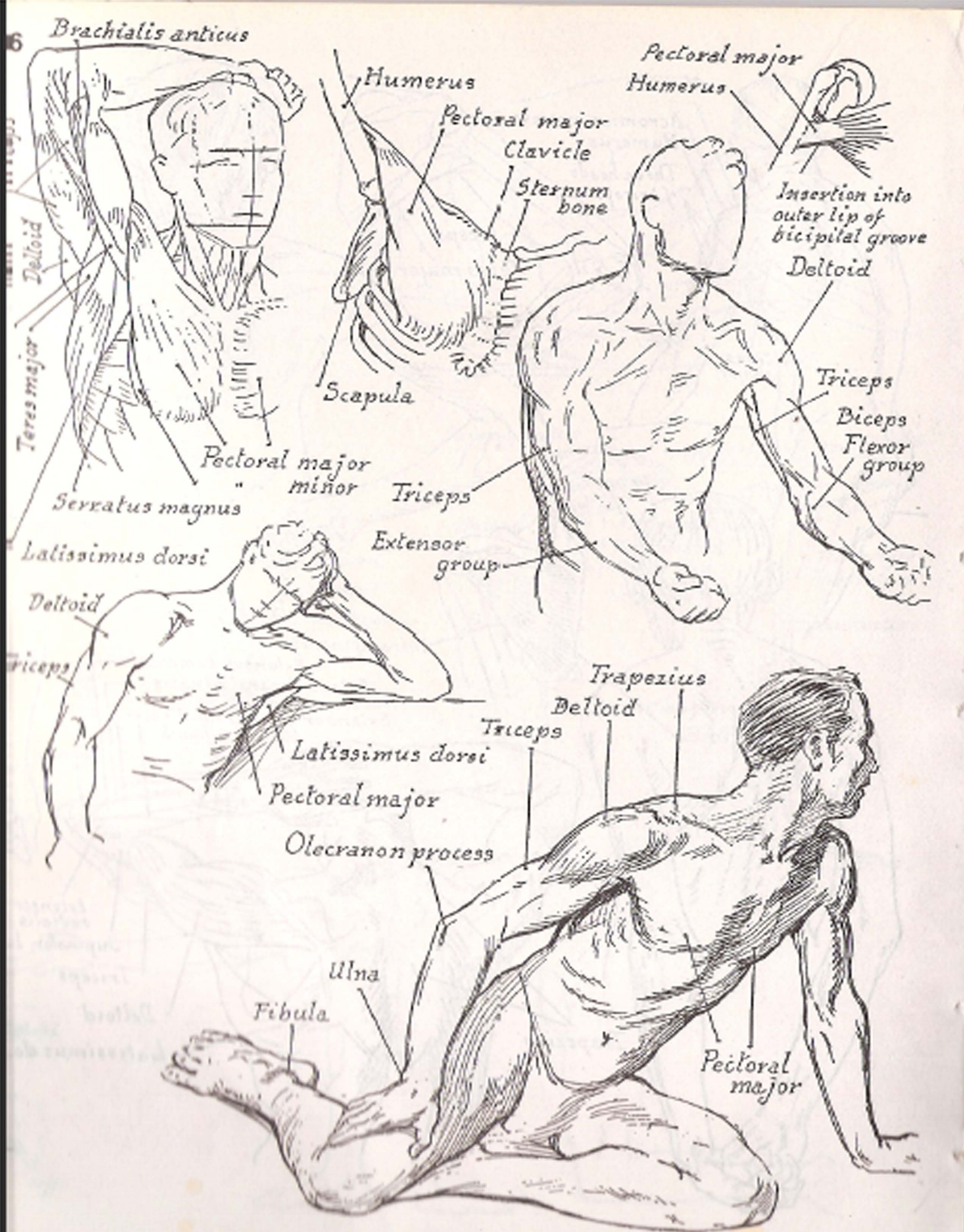
*Biceps*



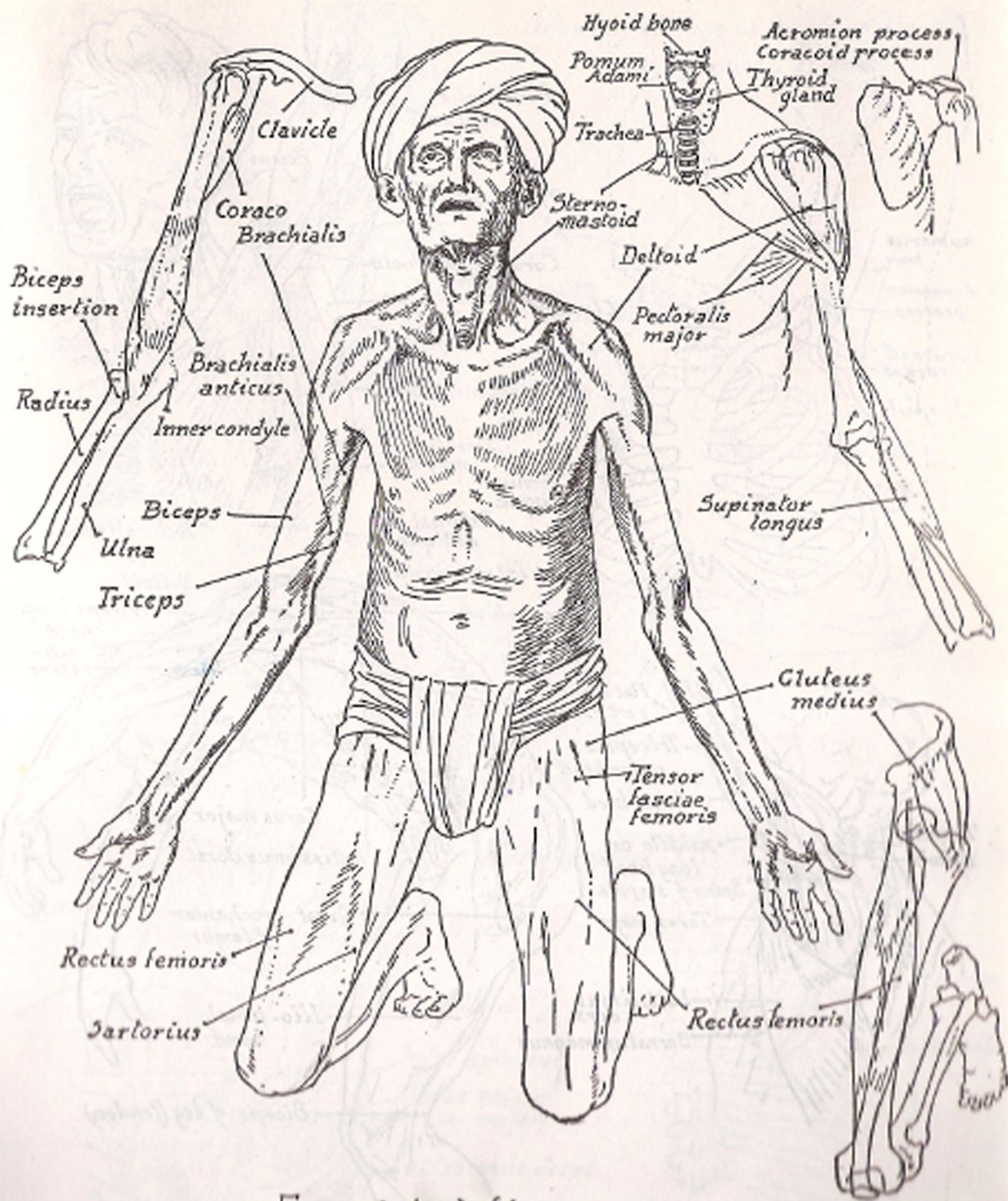
*Supra-spinatus*  
*Spine of Scapula*  
*Scapula*  
*Acromion process*  
*Deltoid*  
*Infraspinatus*  
*Teres major*  
*Teres minor*  
*Insertion of deltoid*  
*Biceps*  
*Humerus*  
*Ulna*  
*Radius*  
*Insertion of Biceps*



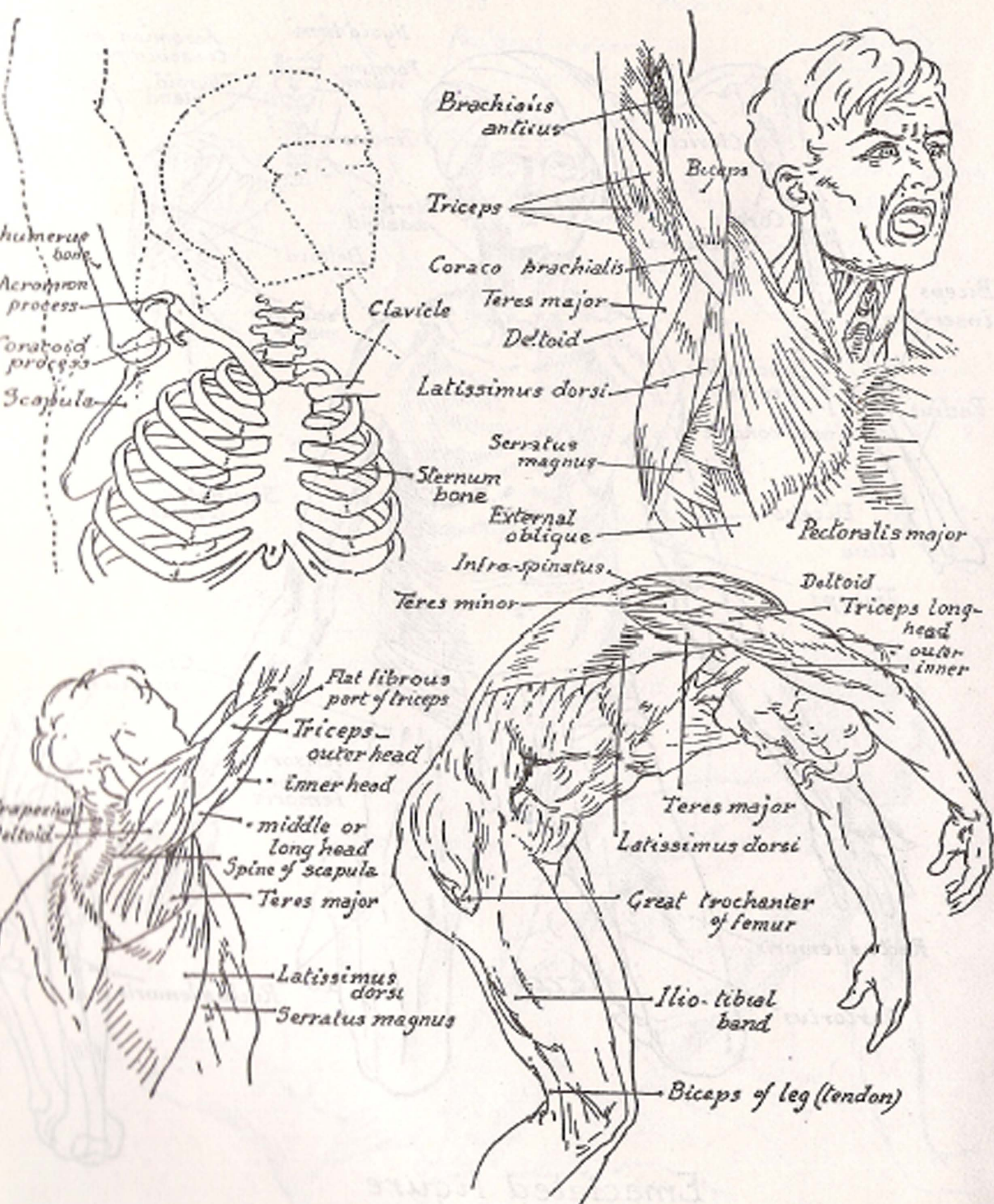




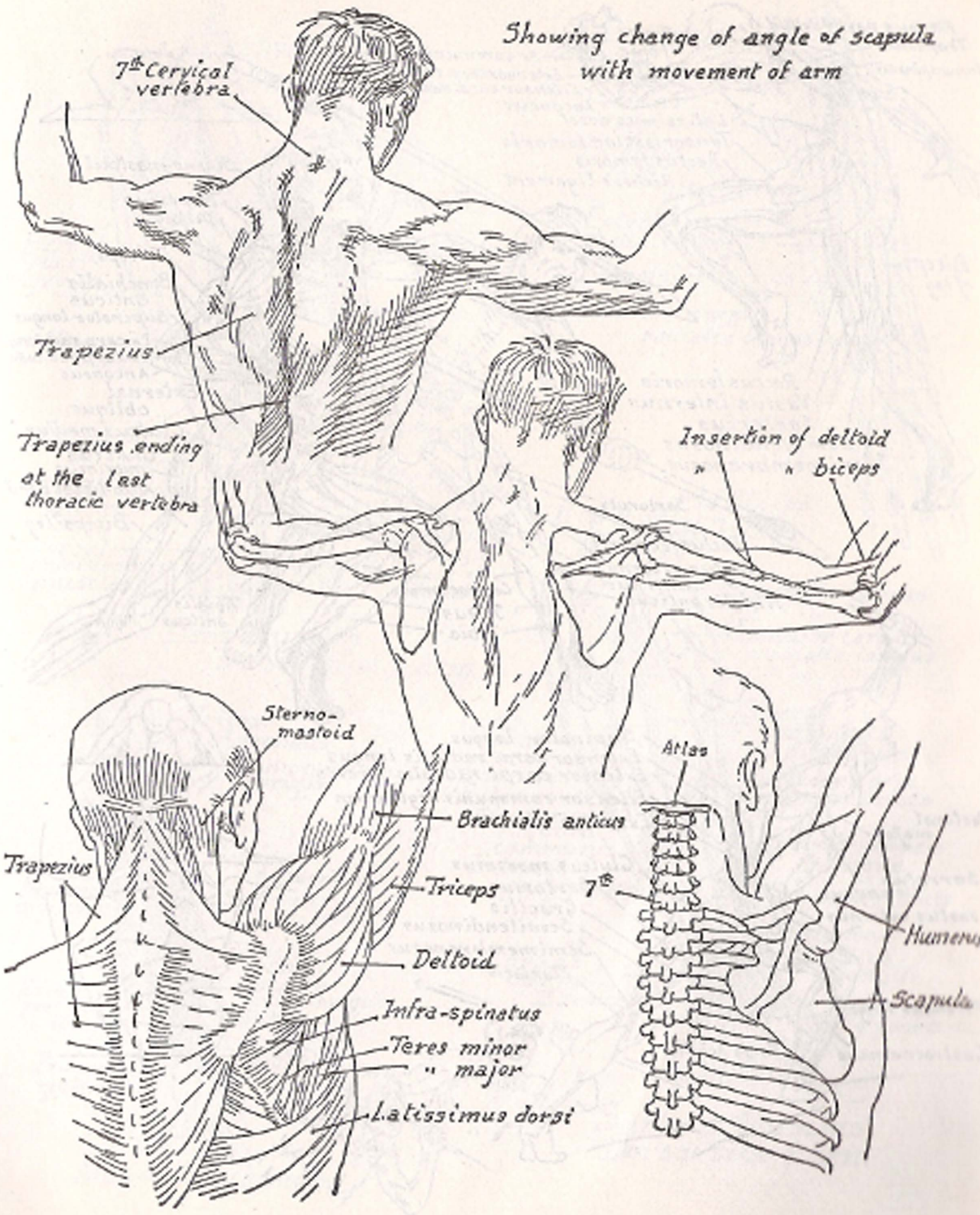


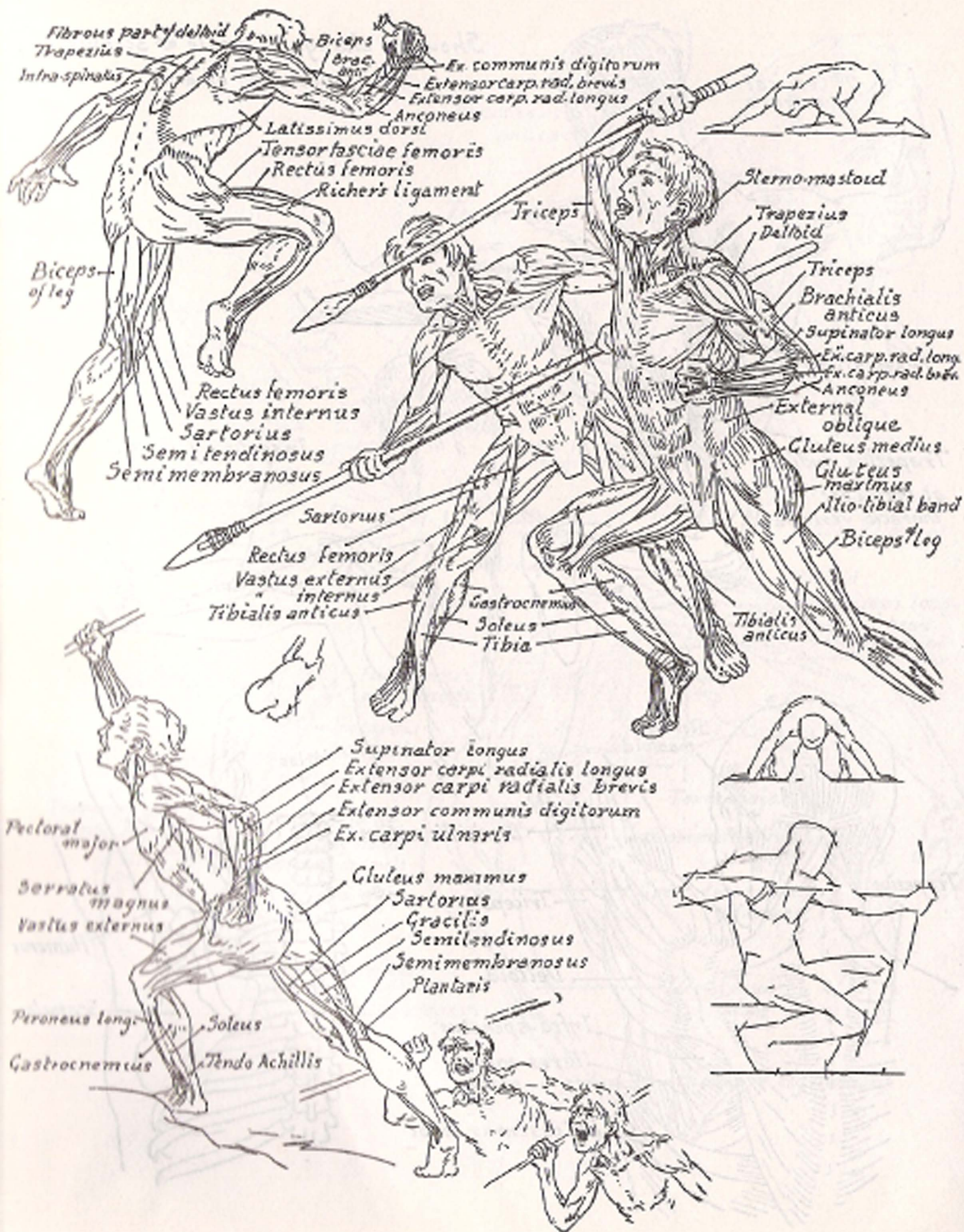


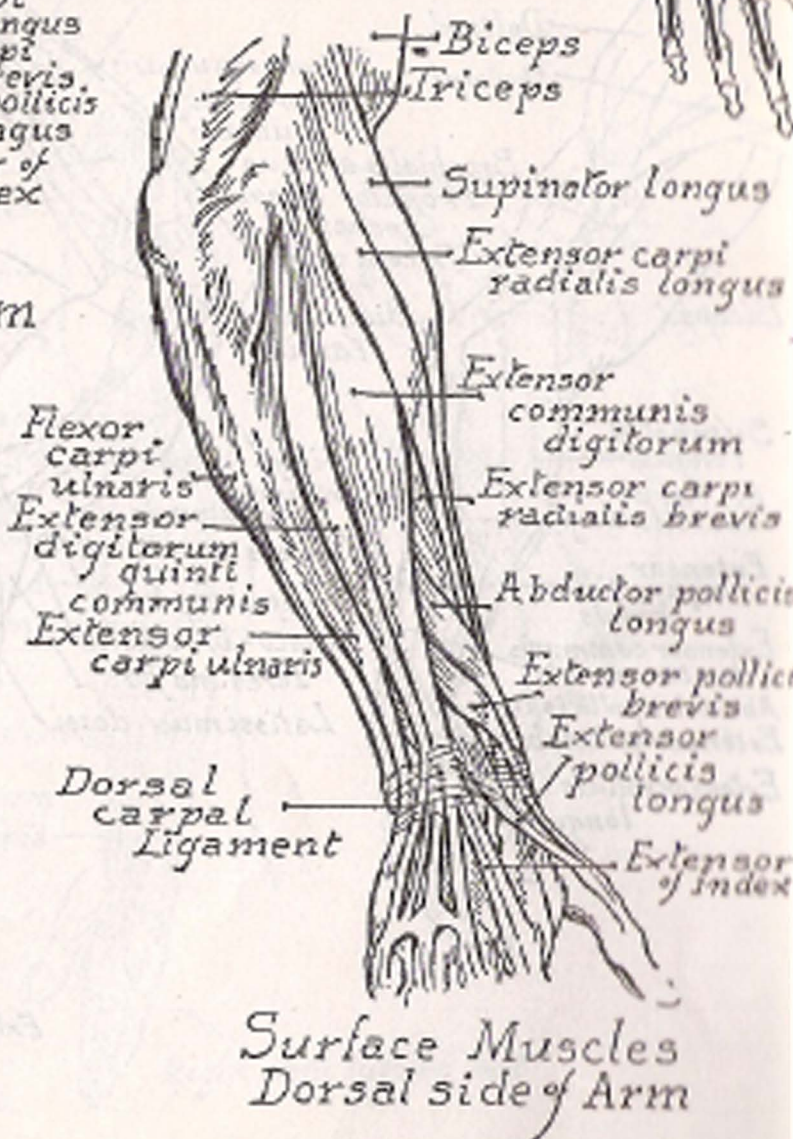
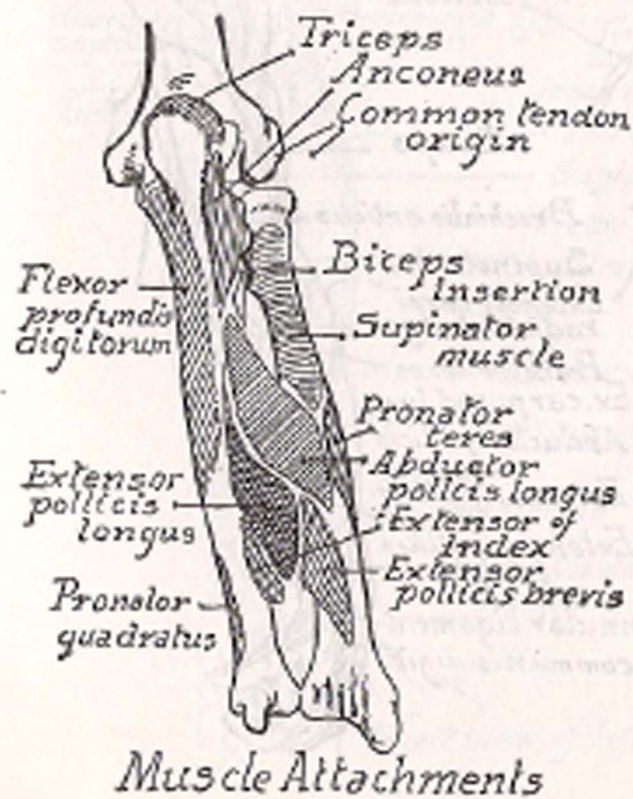
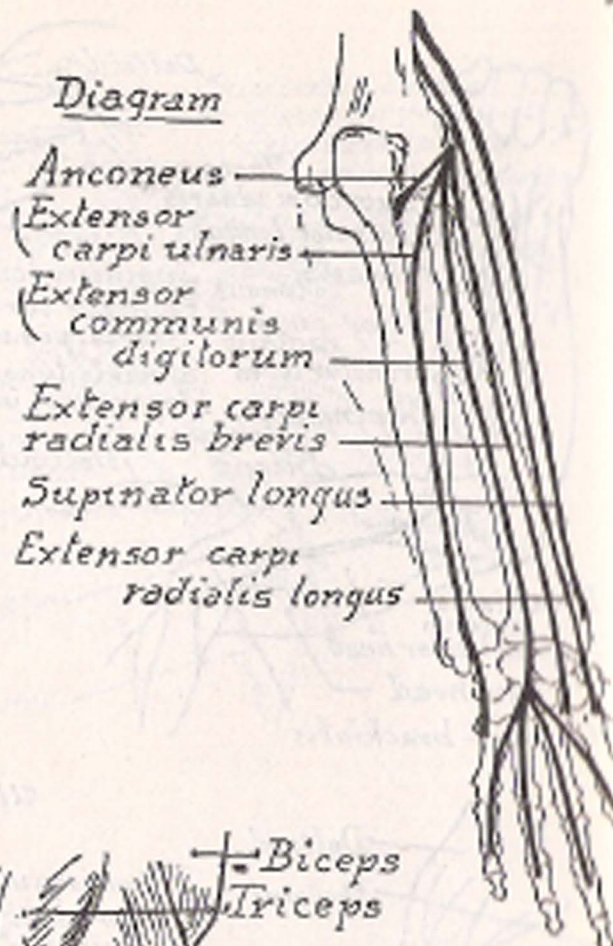
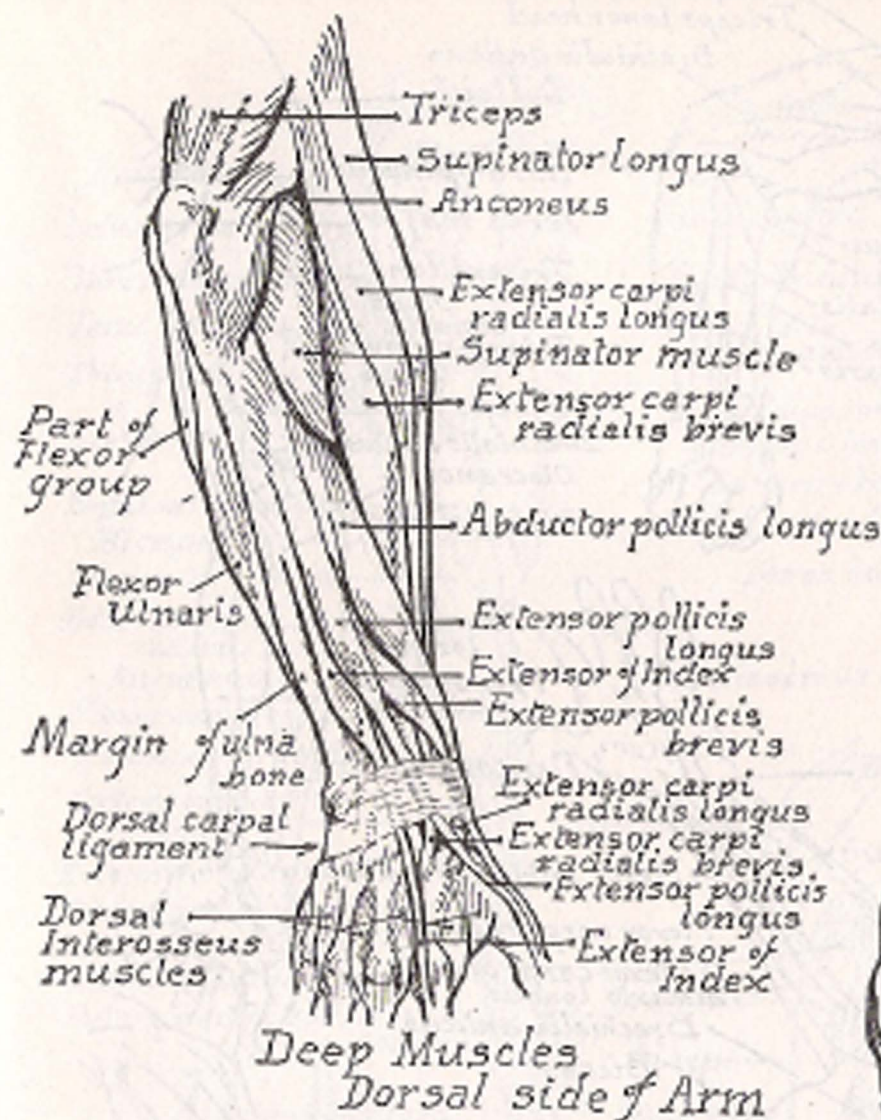
*Emaciated figure*

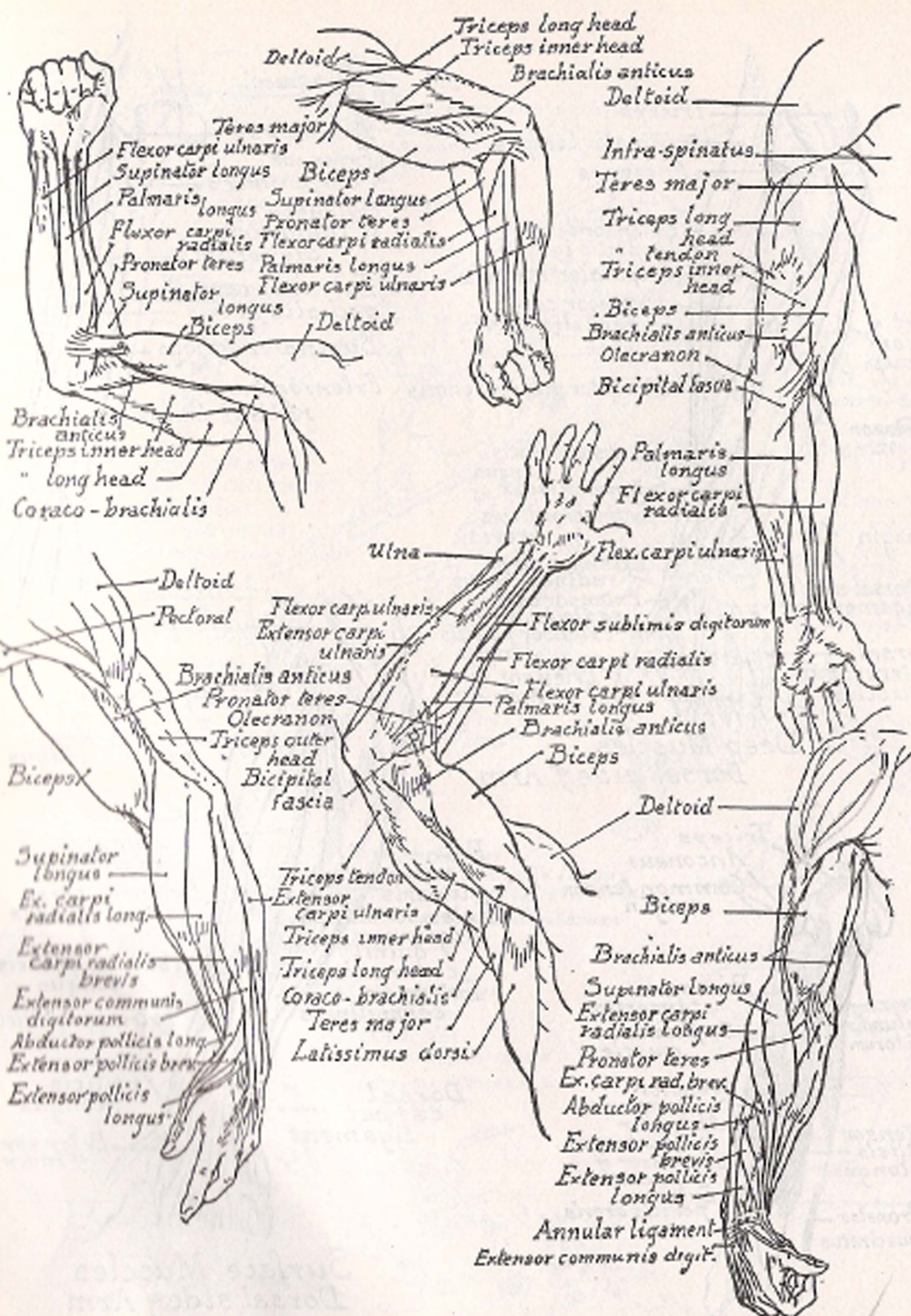


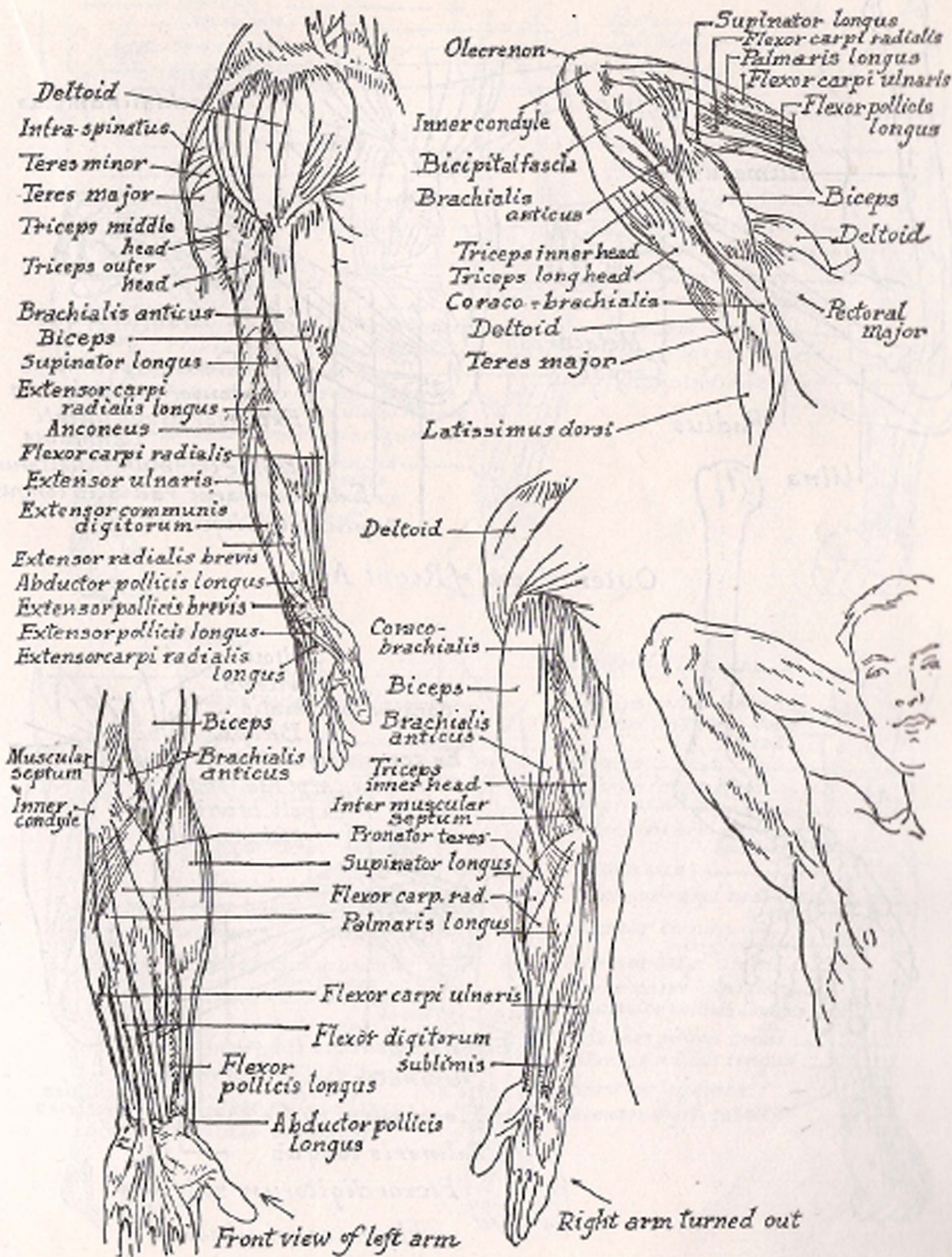
Showing change of angle of scapula with movement of arm

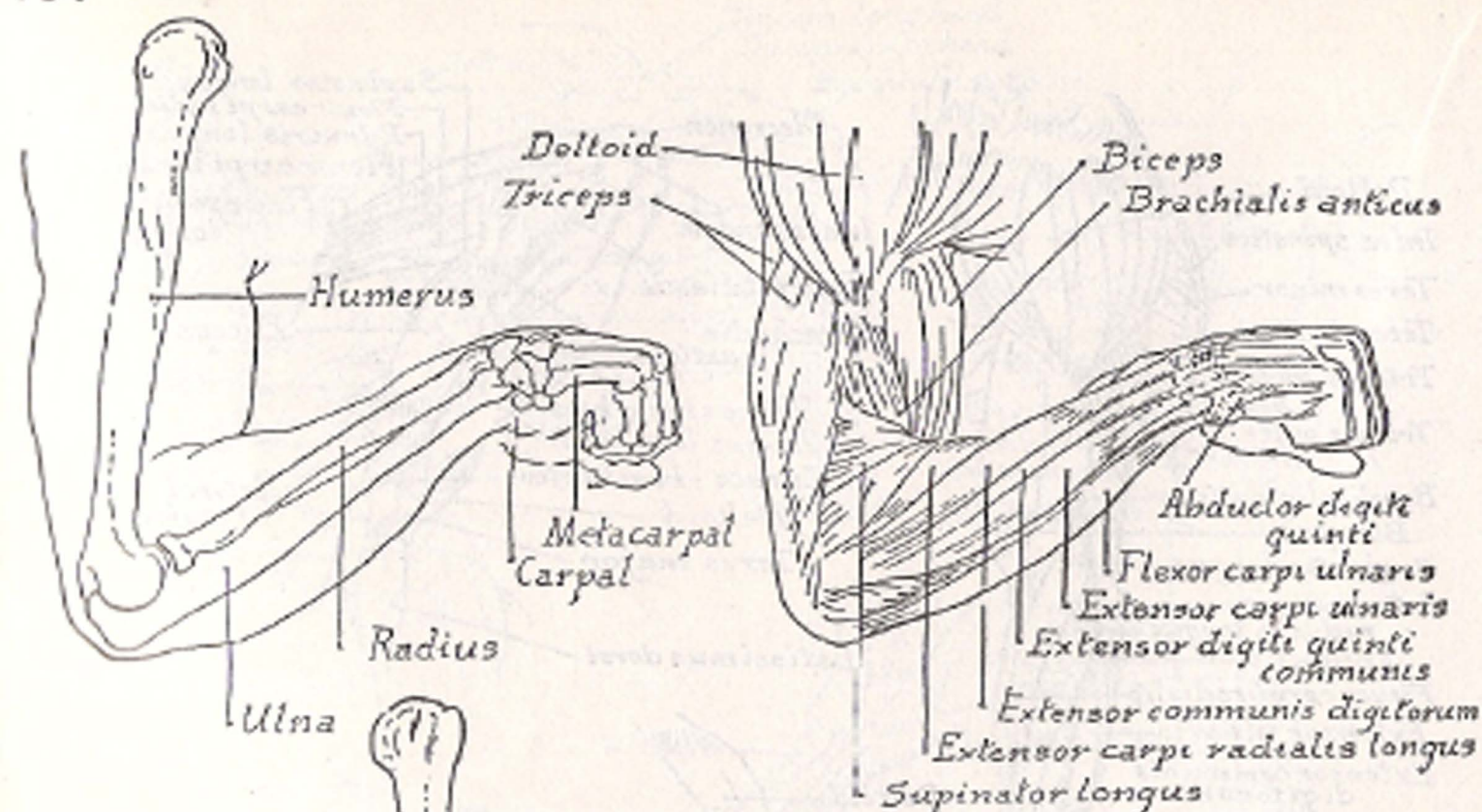




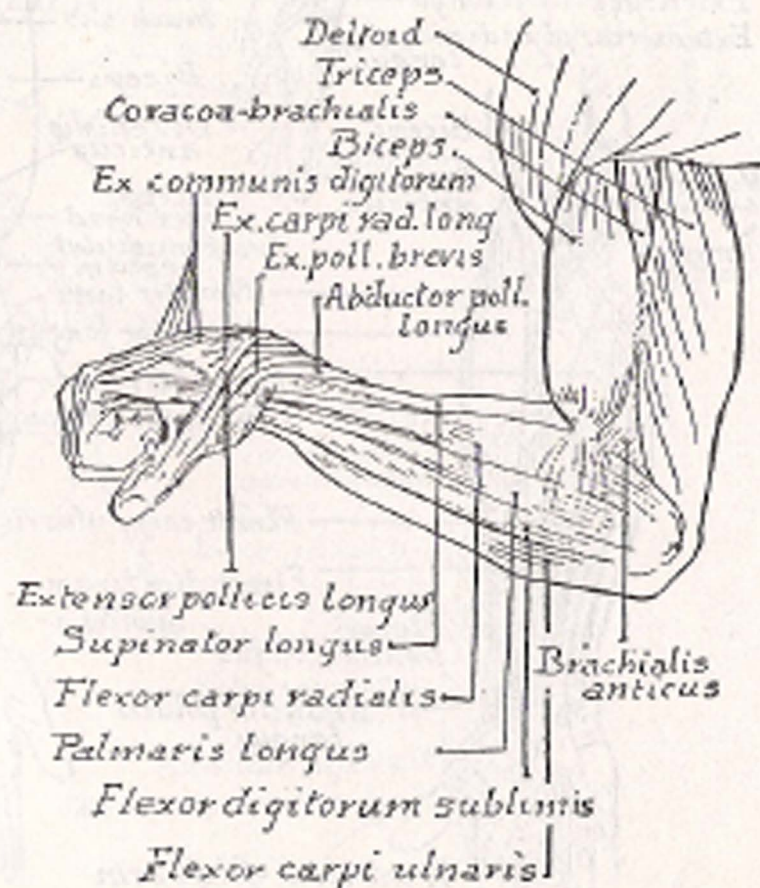
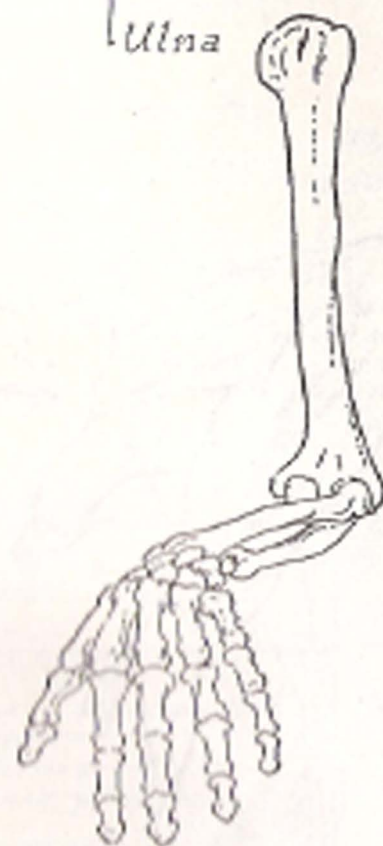






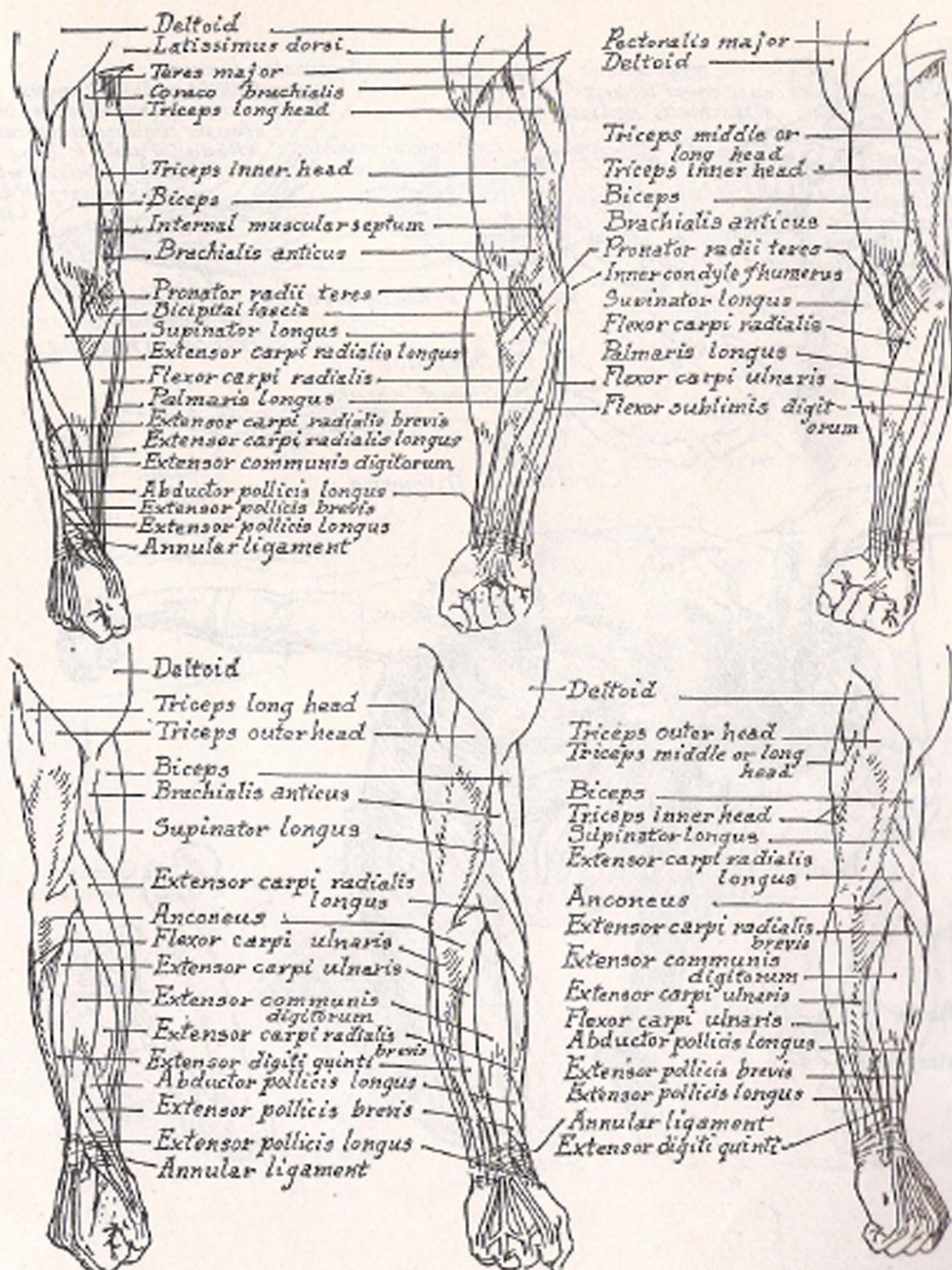
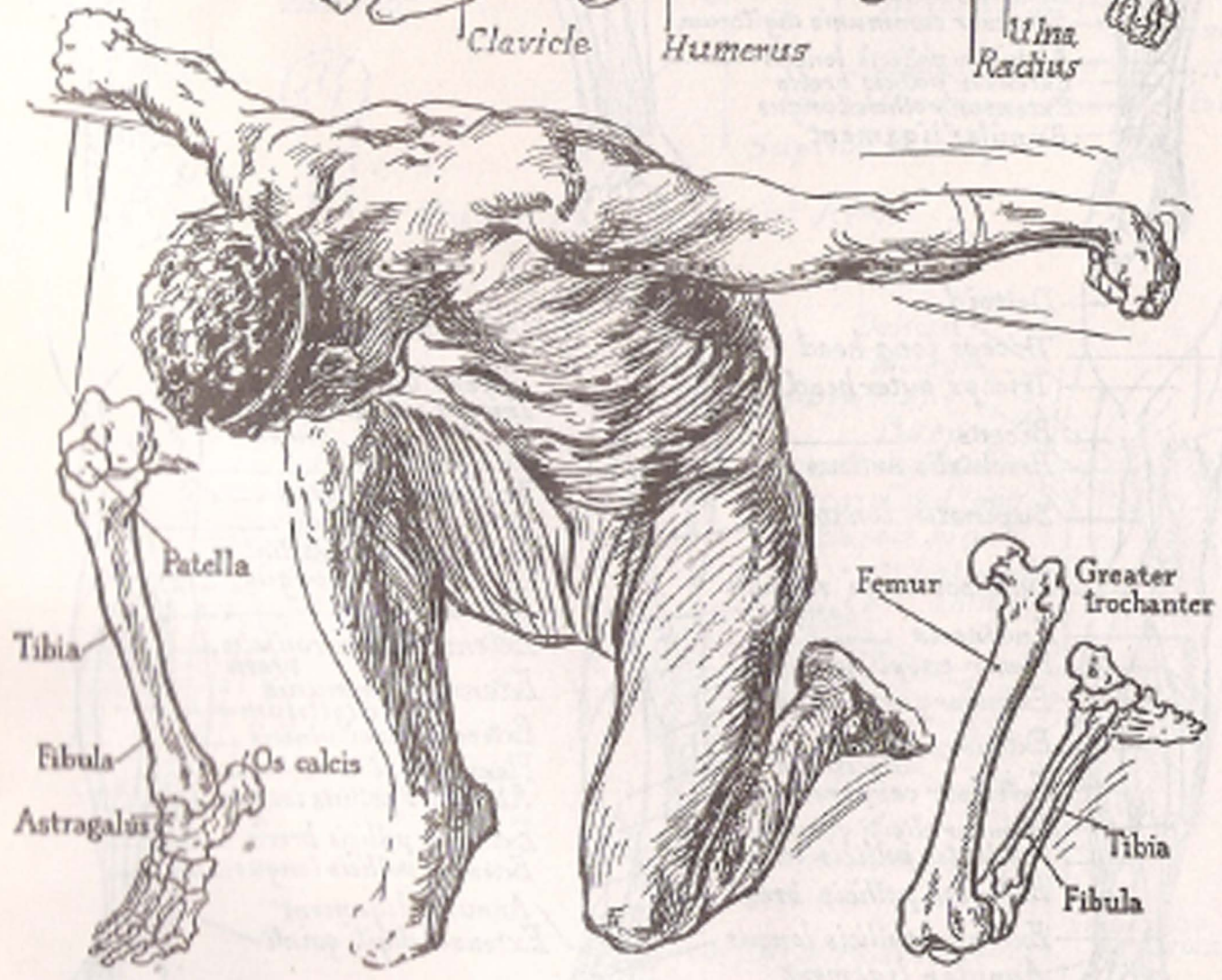
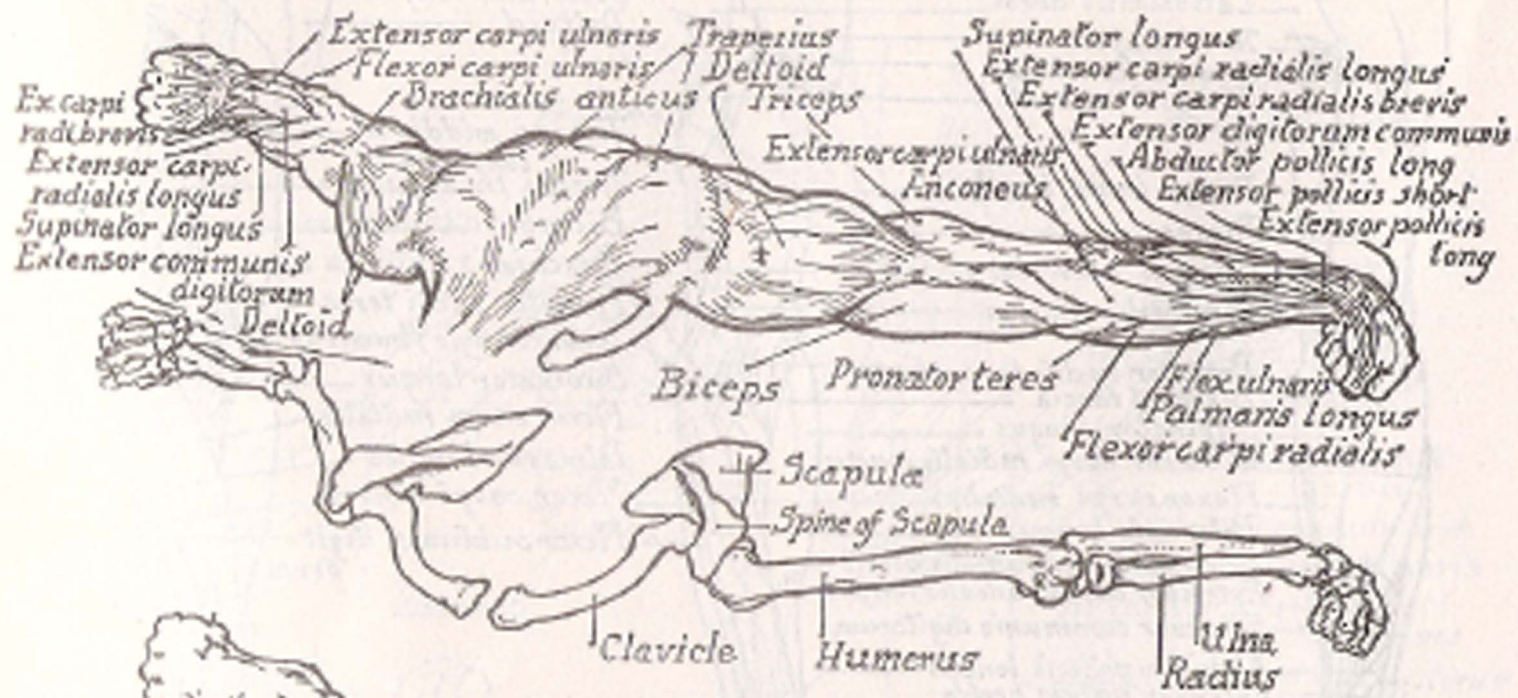
Outer View of Right Arm

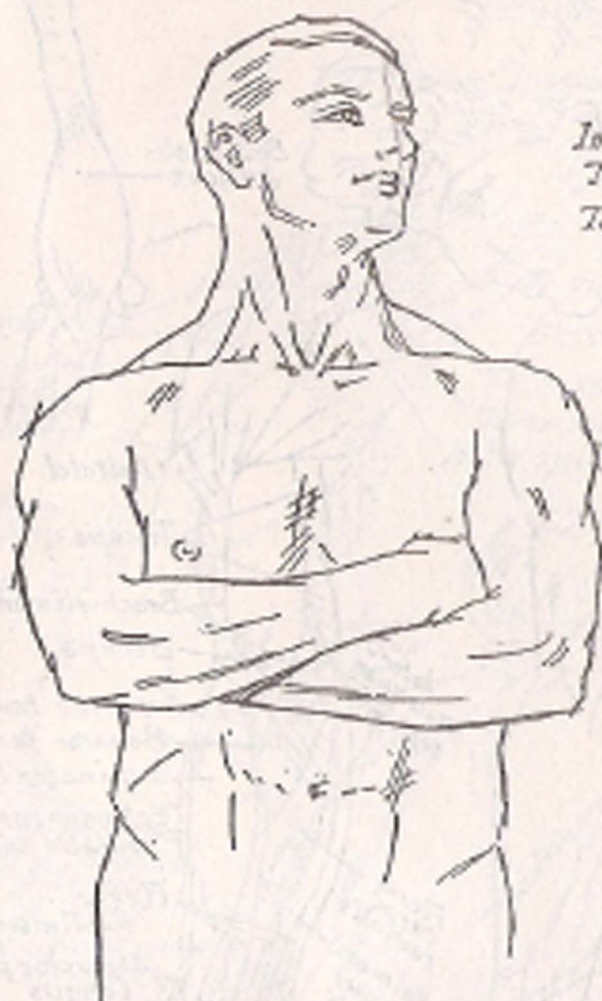


Inner view

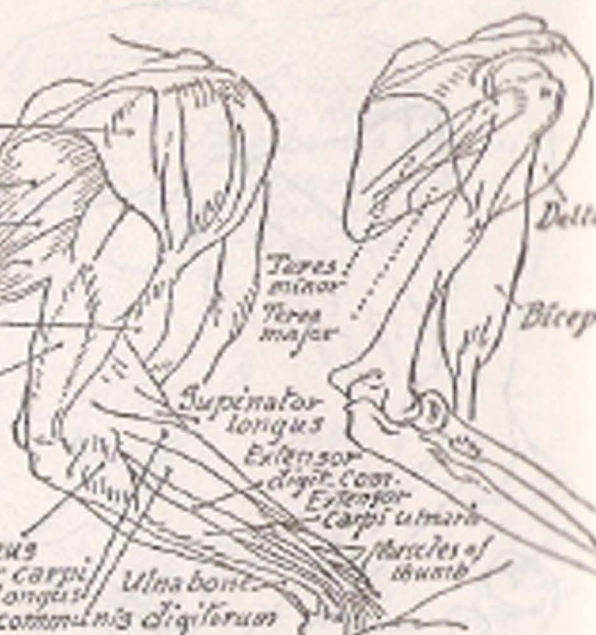






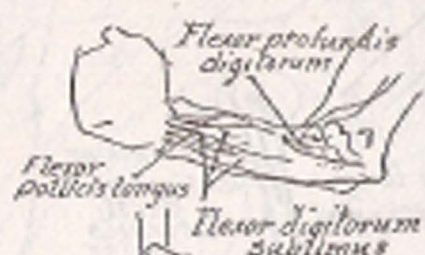

*Deltoid*  
*Intra-spinatus*  
*Teres minor*  
*Teres major*  
*Brachialis*  
*anticus*  
*Triceps*  
*lendon*



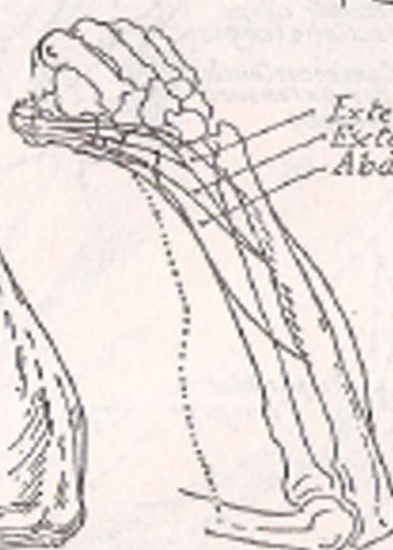
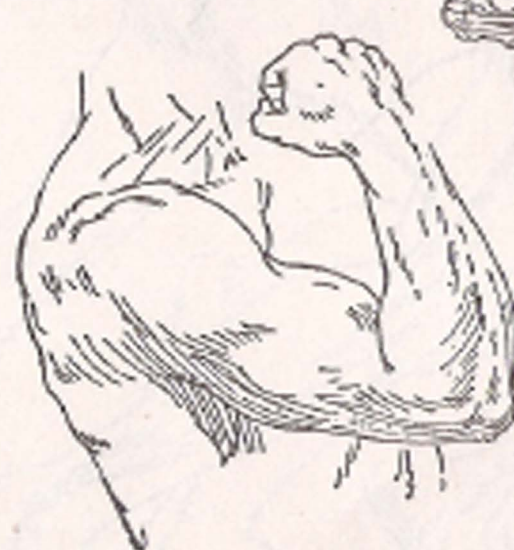*Anconeus*  
*Extensor carpi*  
*radialis longus*  
*Extensor communis digitorum*

*Teres minor*  
*Teres major*  
*Supinator longus*  
*Extensor digiti*  
*cost.*  
*Extensor carpi ulnaris*  
*Muscles of thumb*  
*Ulna bone*



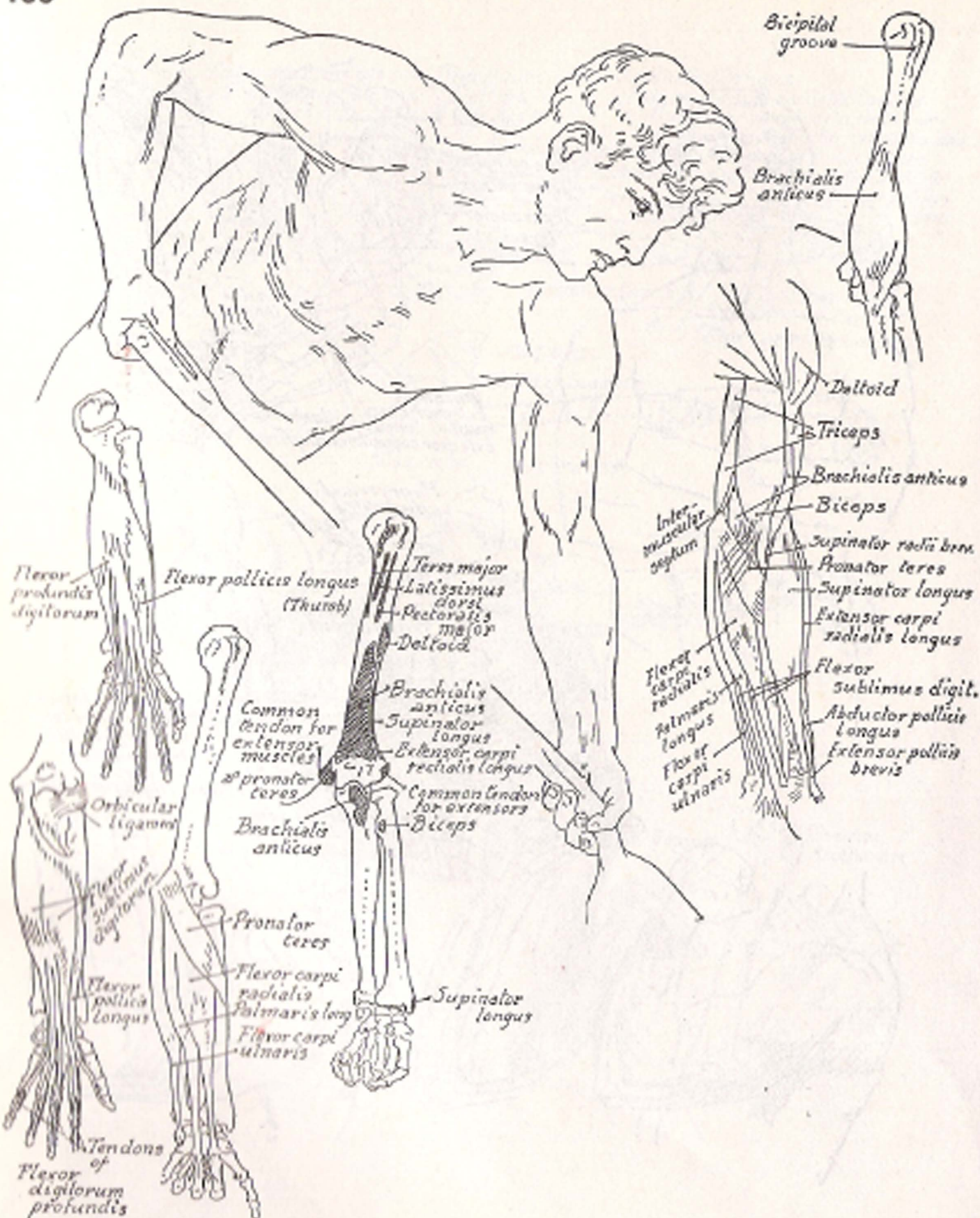
*Flexor profundus digitorum*  
*Flexor pollicis longus*  
*Flexor digitorum sublimis*

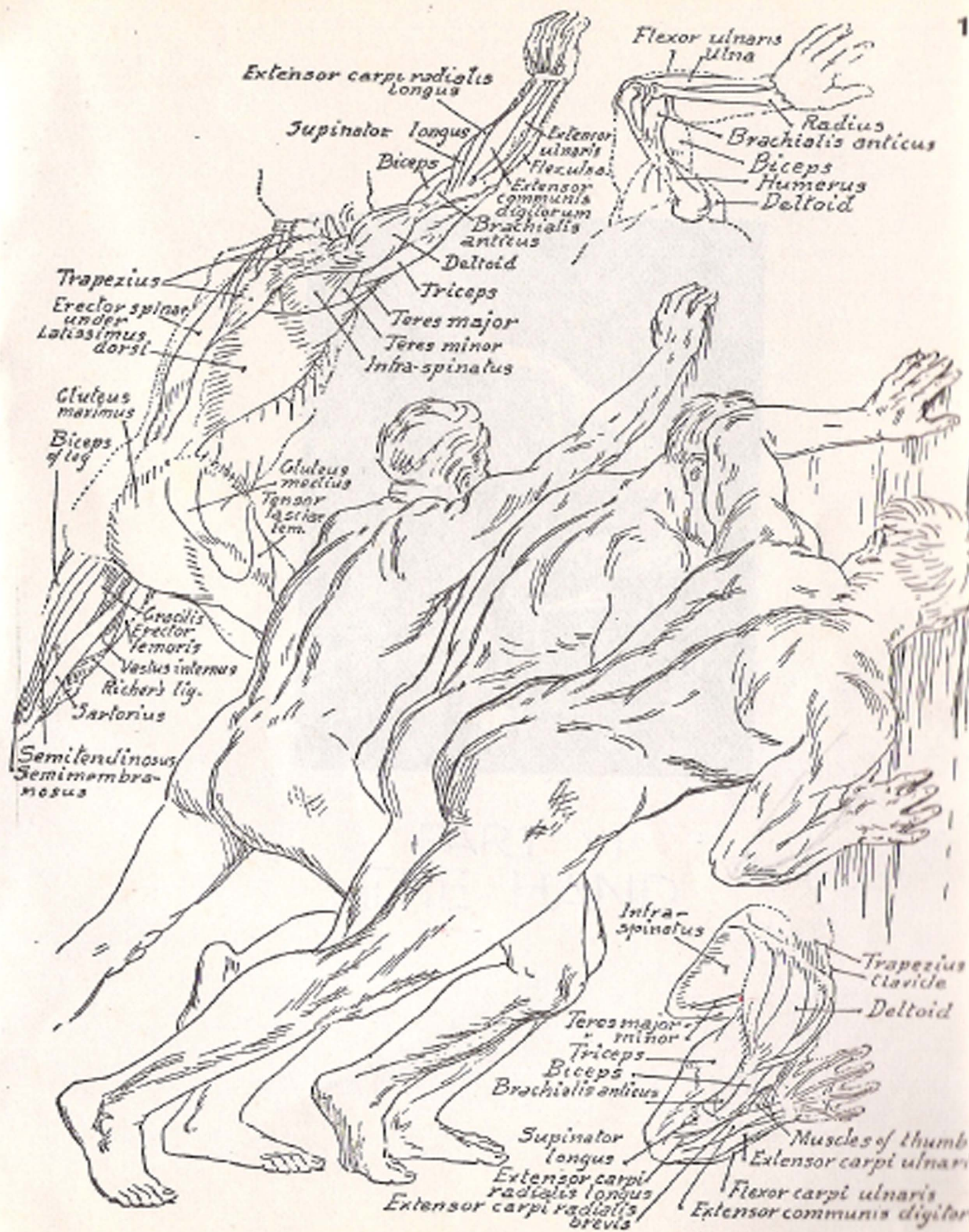
*Supinator longus*  
*Pronator radii lateralis*  
*Flexor carpi radialis*  
*Palmaris longus*  
*Flexor carpi ulnaris*  
*Flexor digitorum sublimis*



*Extensor pollicis longus*  
*Extensor pollicis brevis*  
*Abductor pollicis longus*



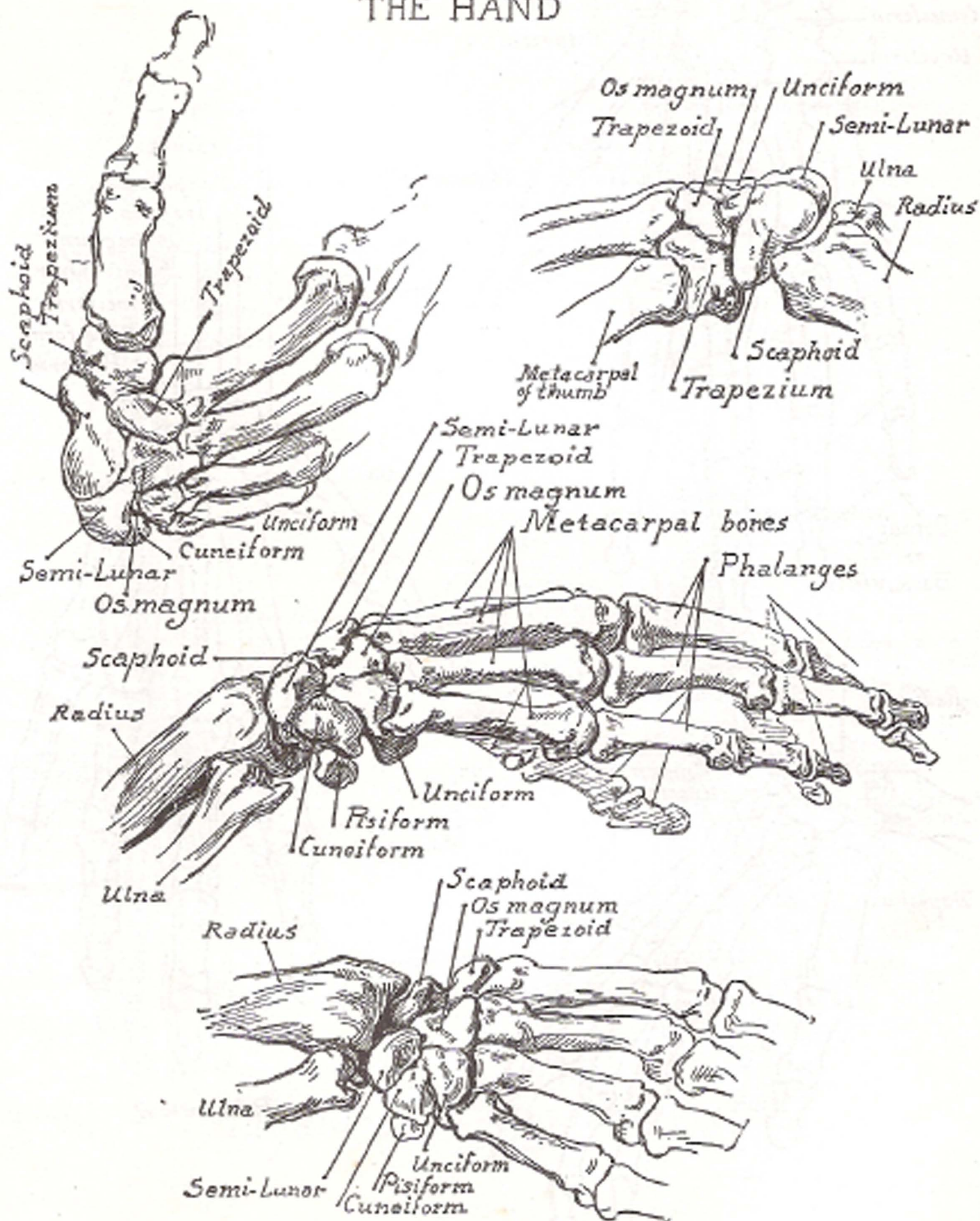


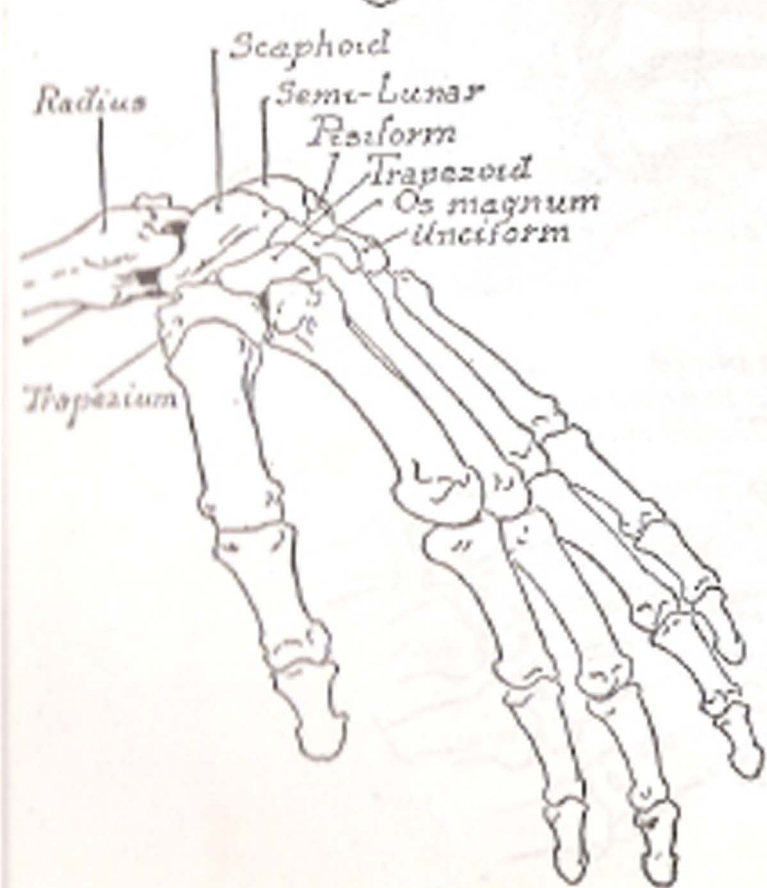
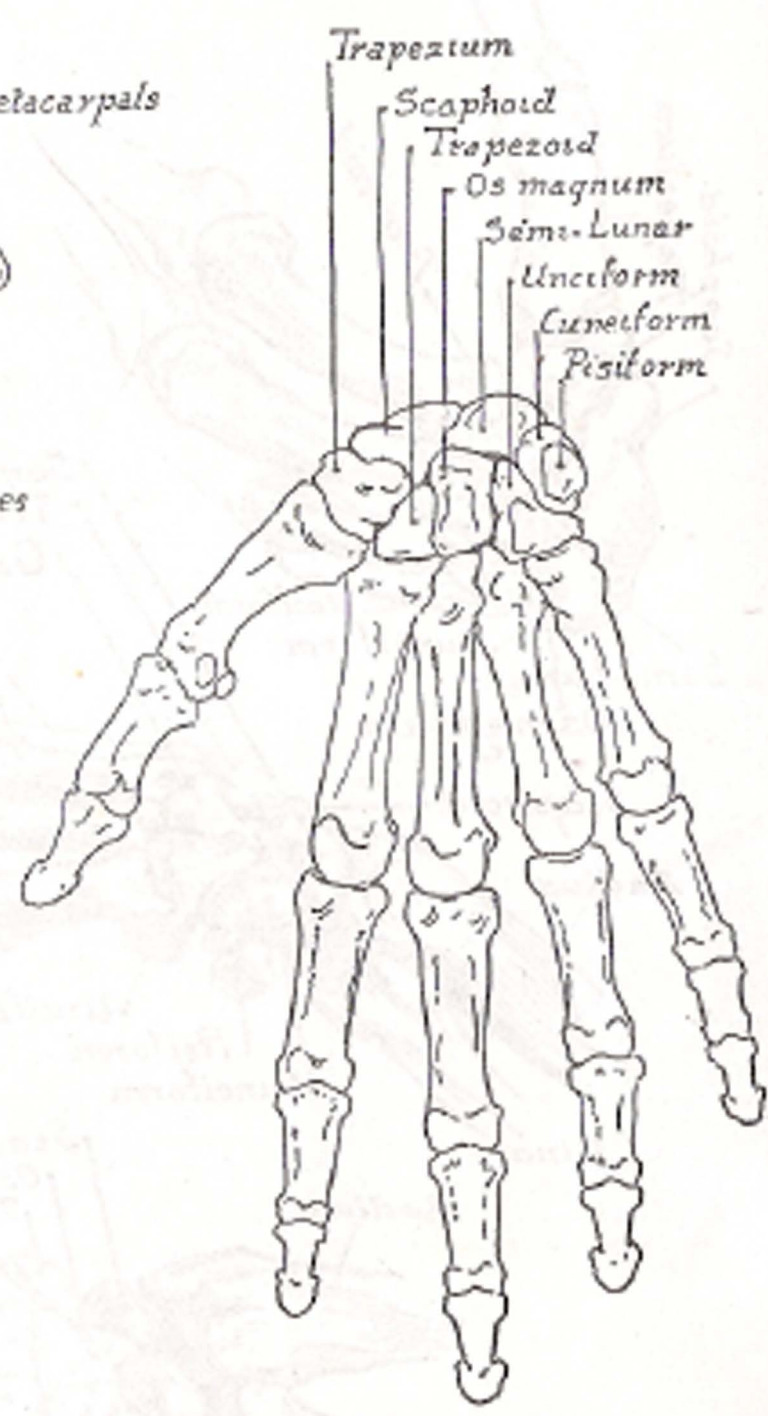
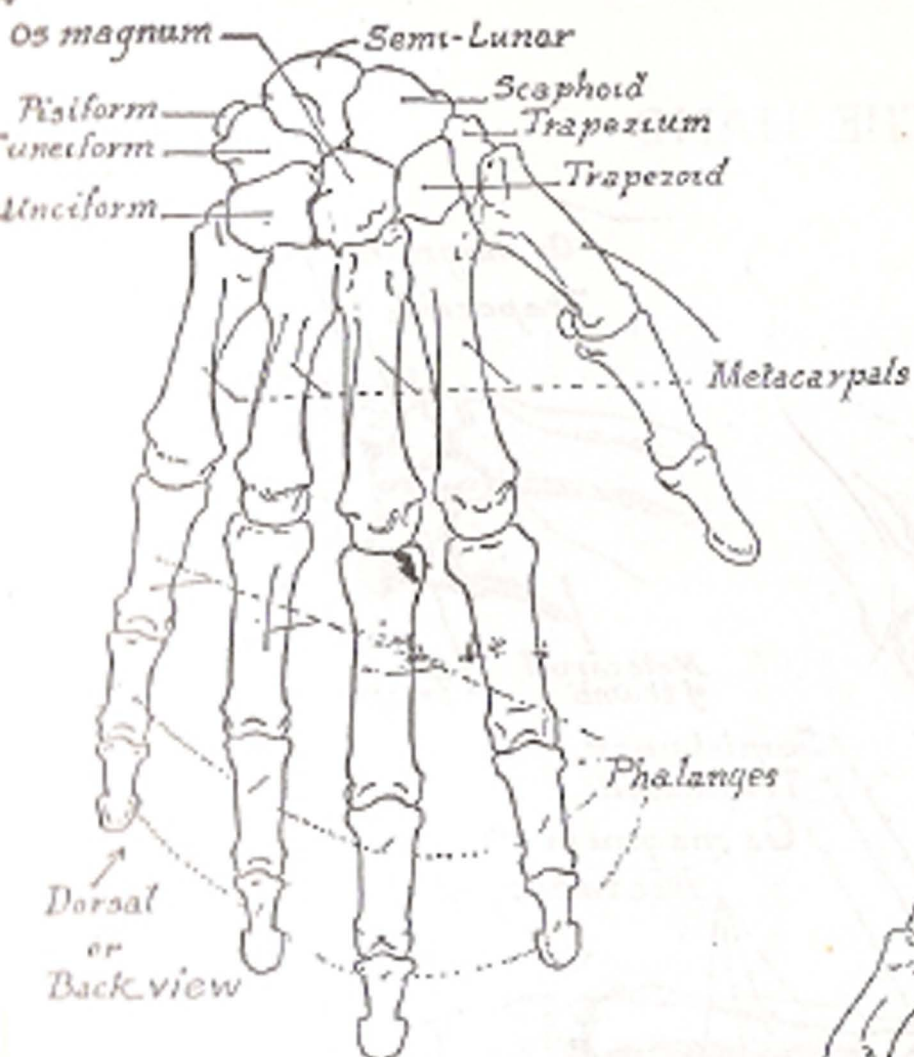




PART VI  
THE HAND

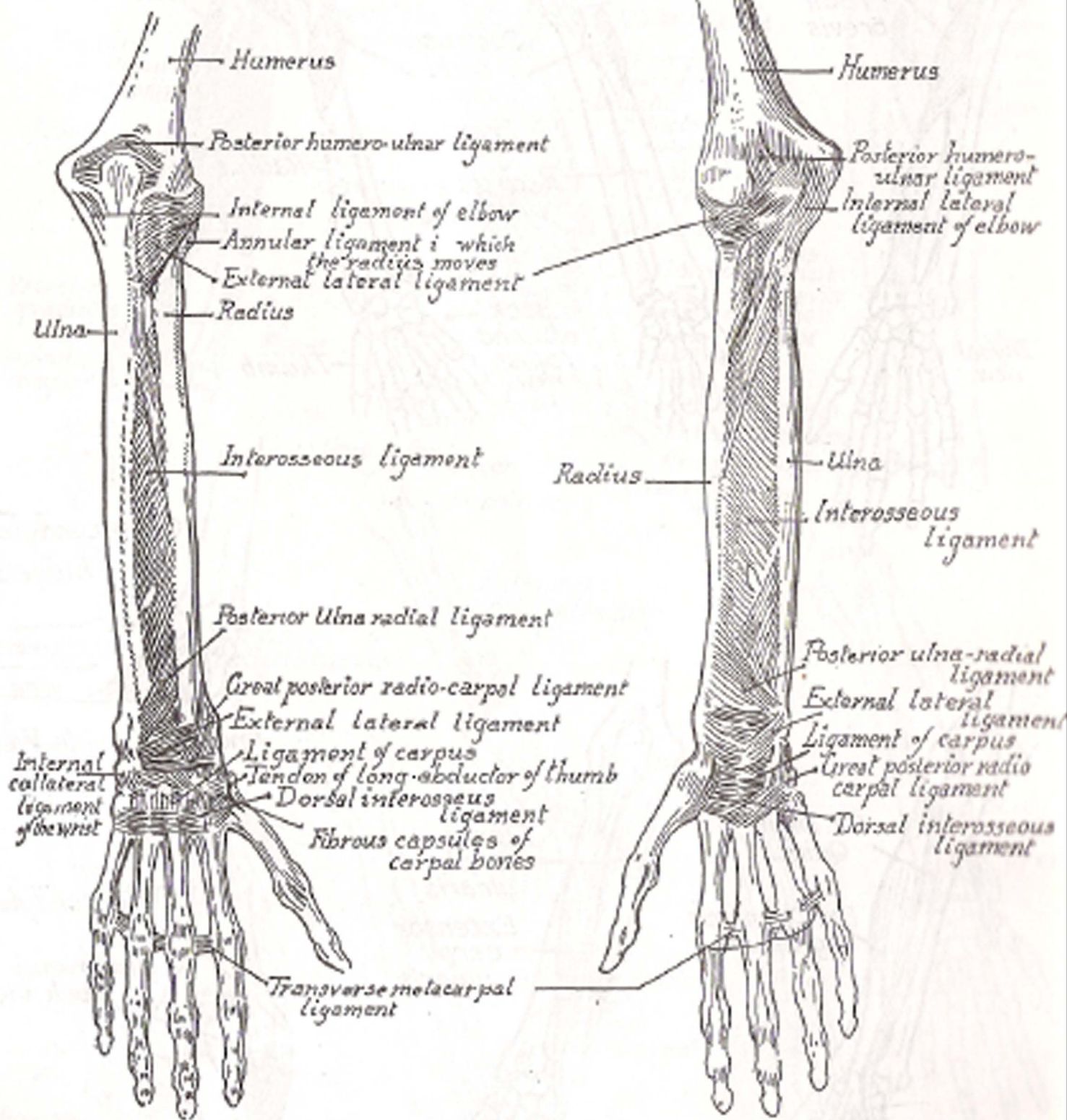
## THE HAND



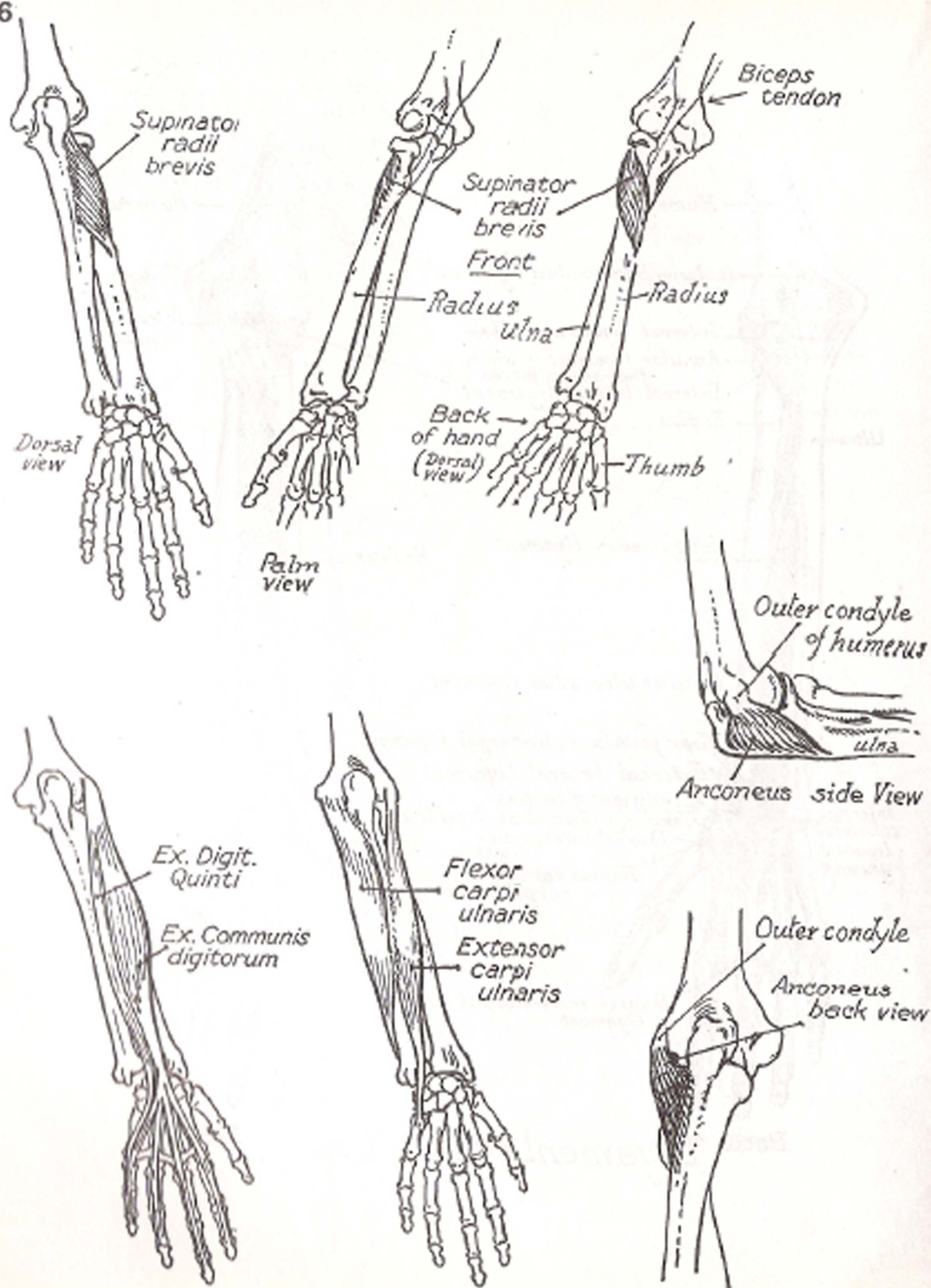


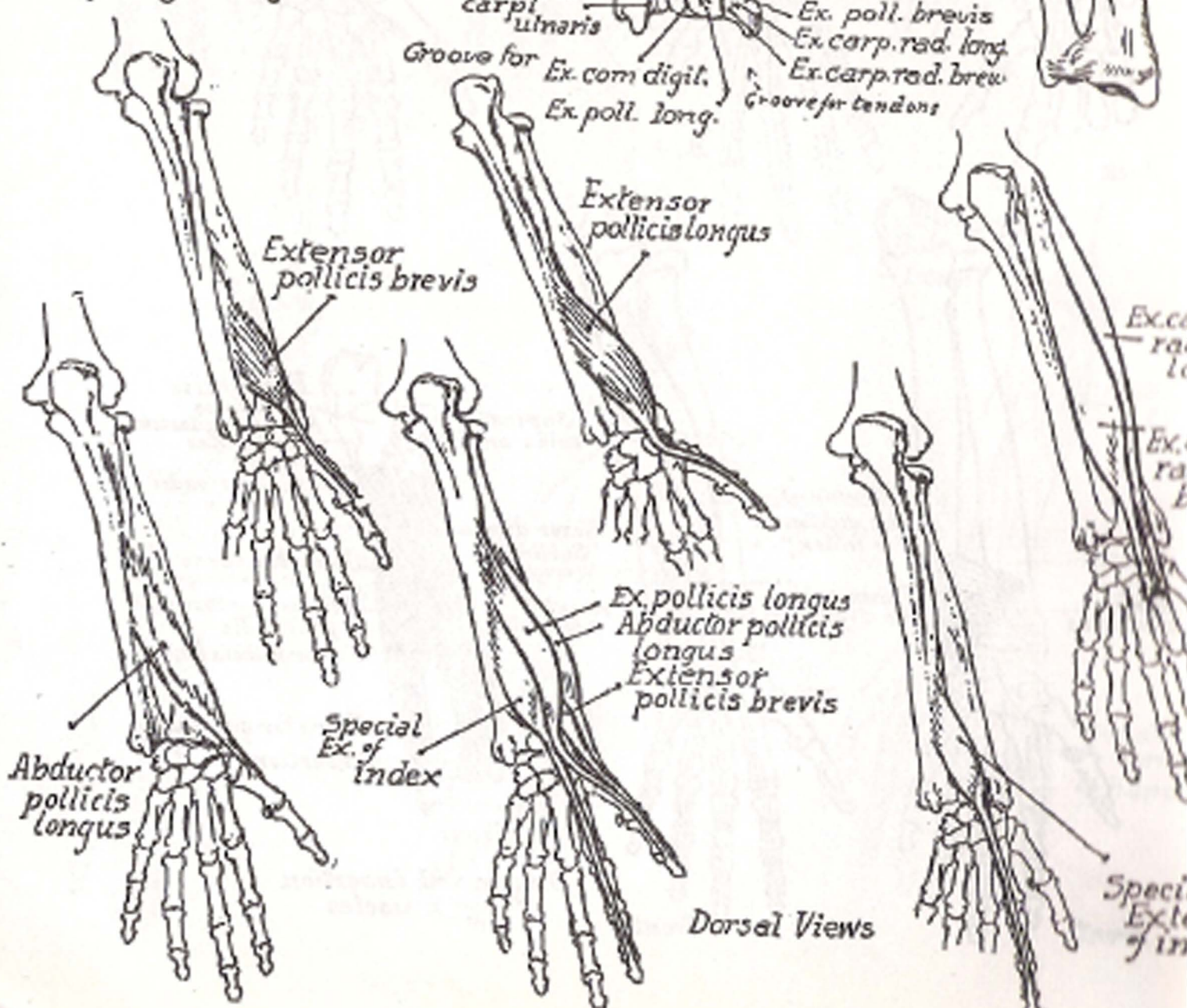
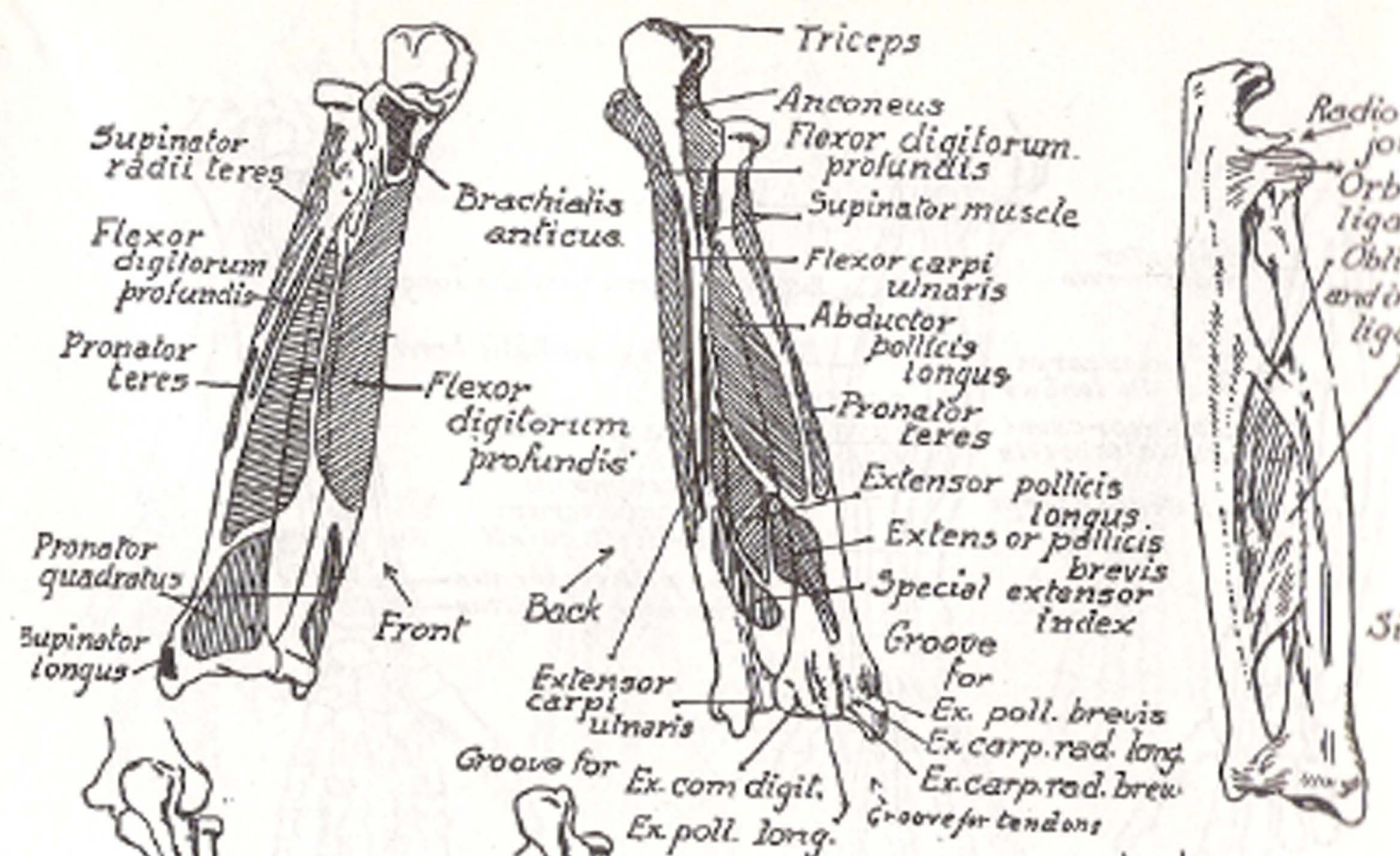
Palm view

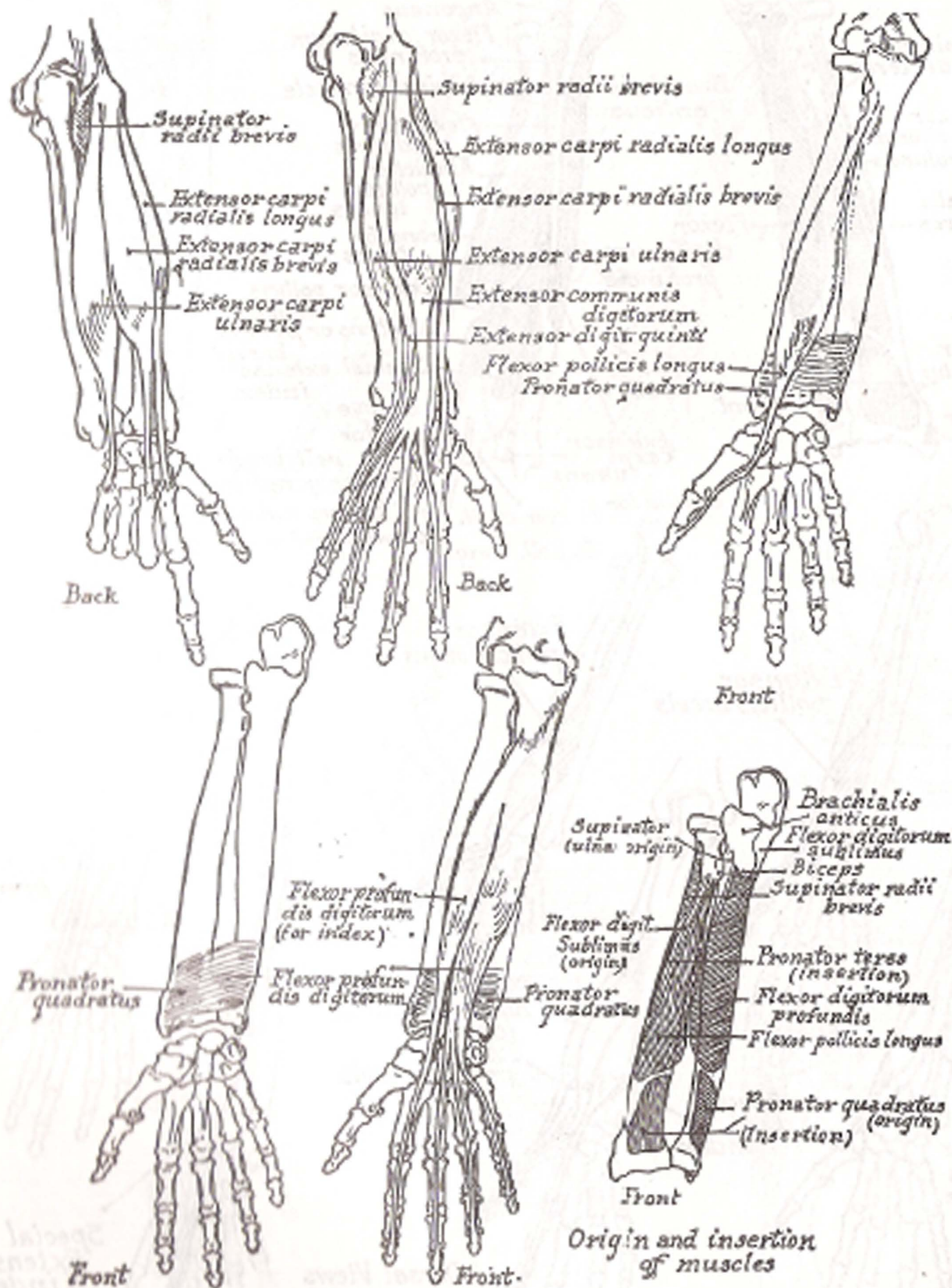


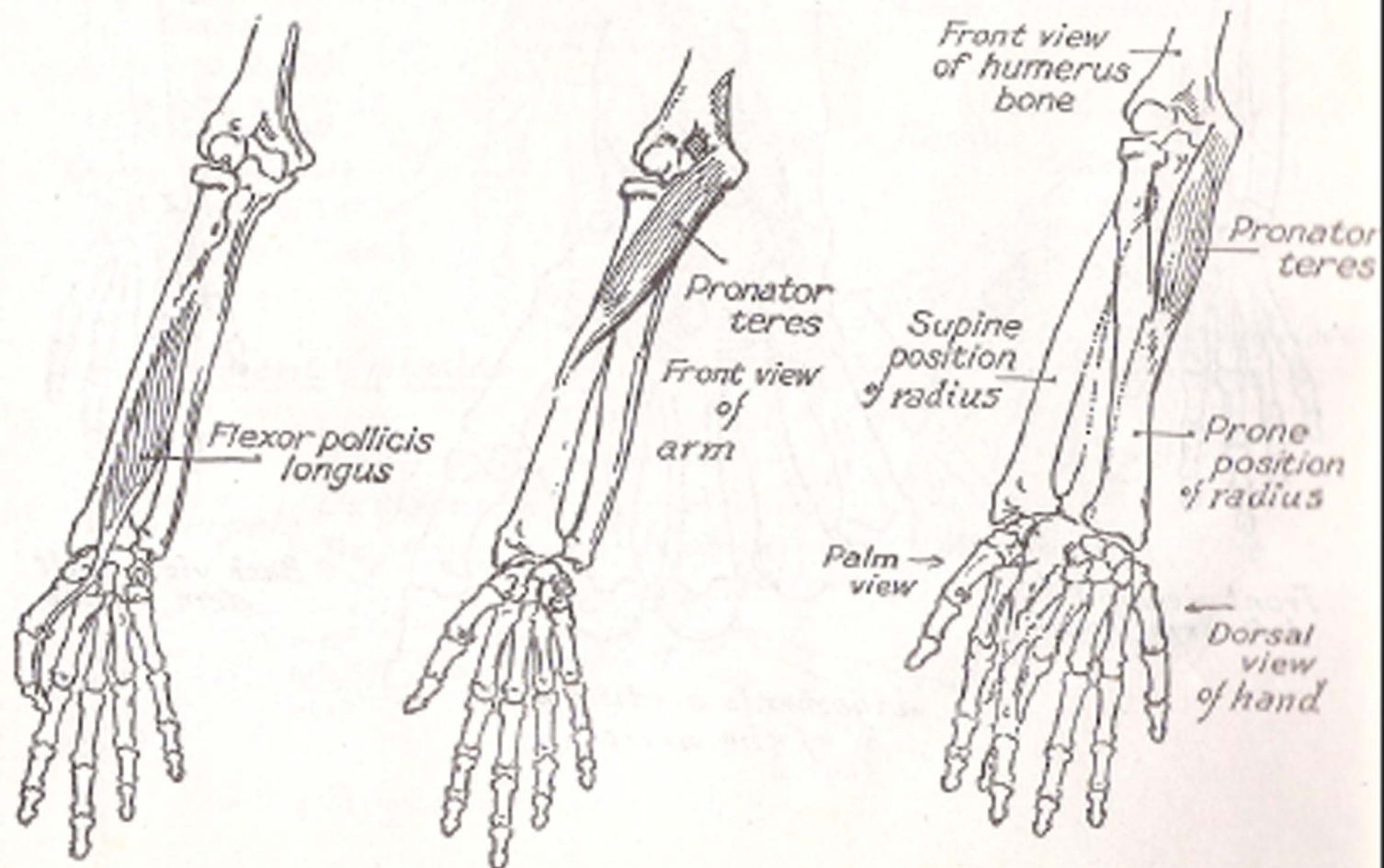
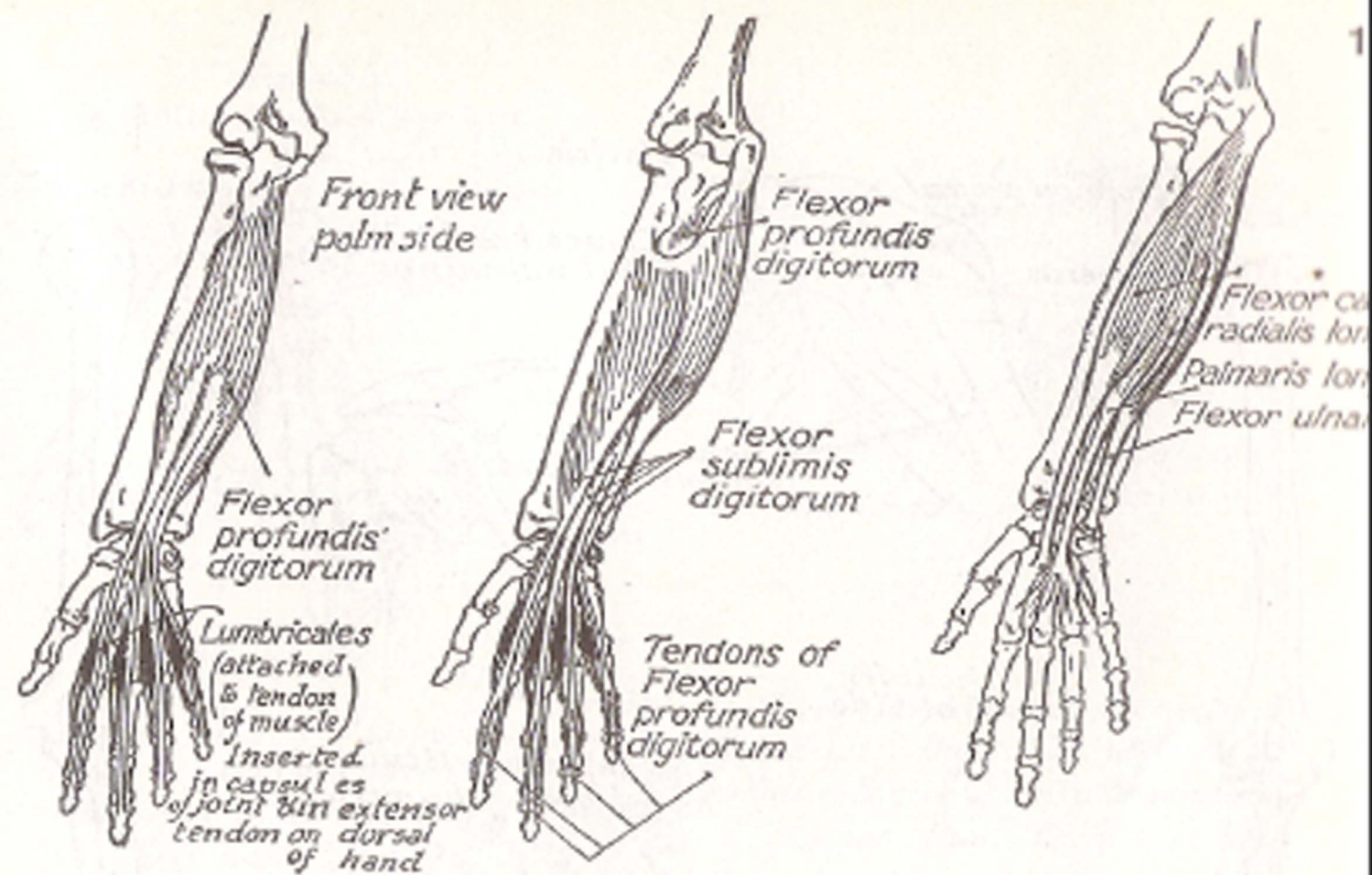


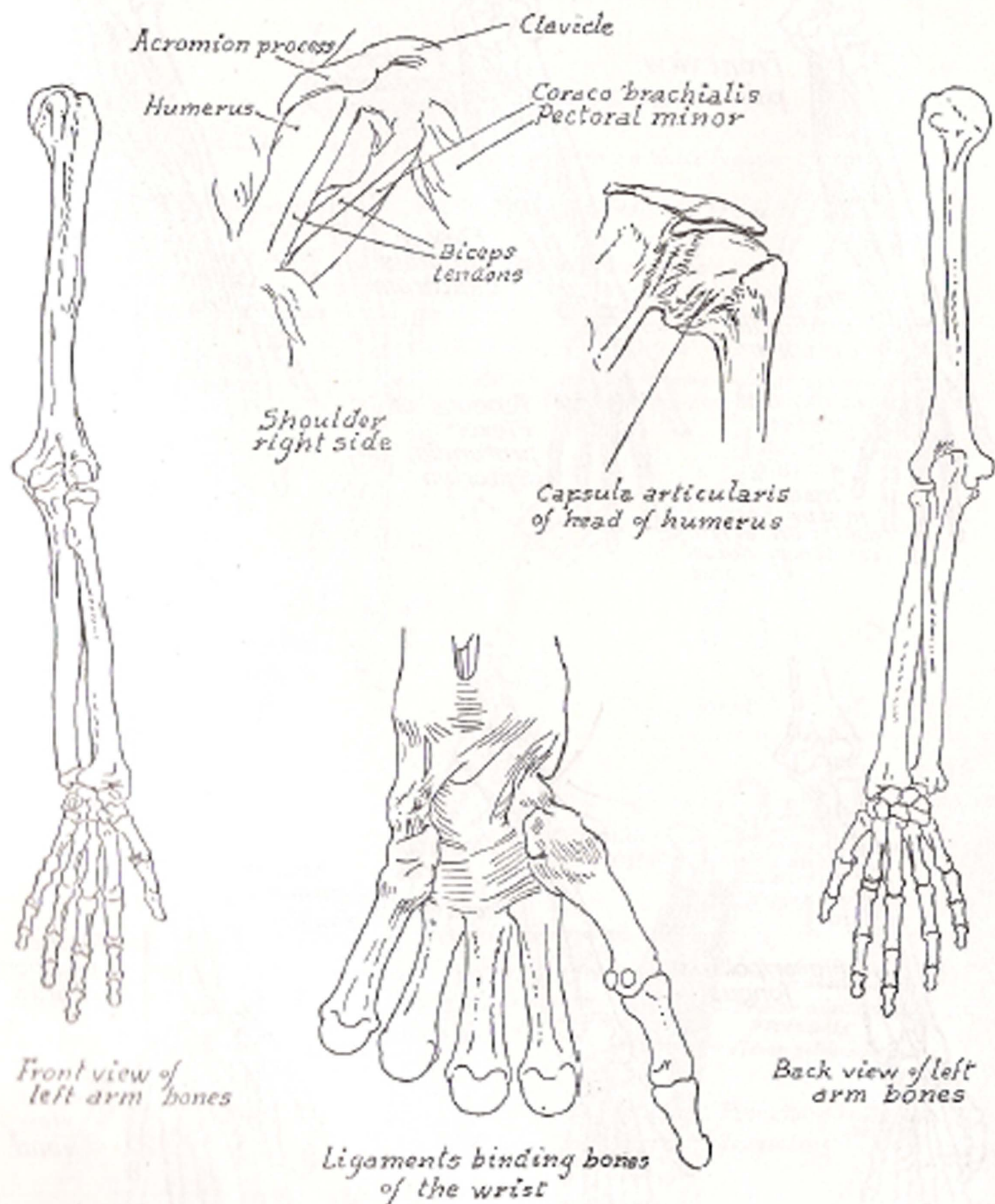
Back Ligaments of Forearm Front

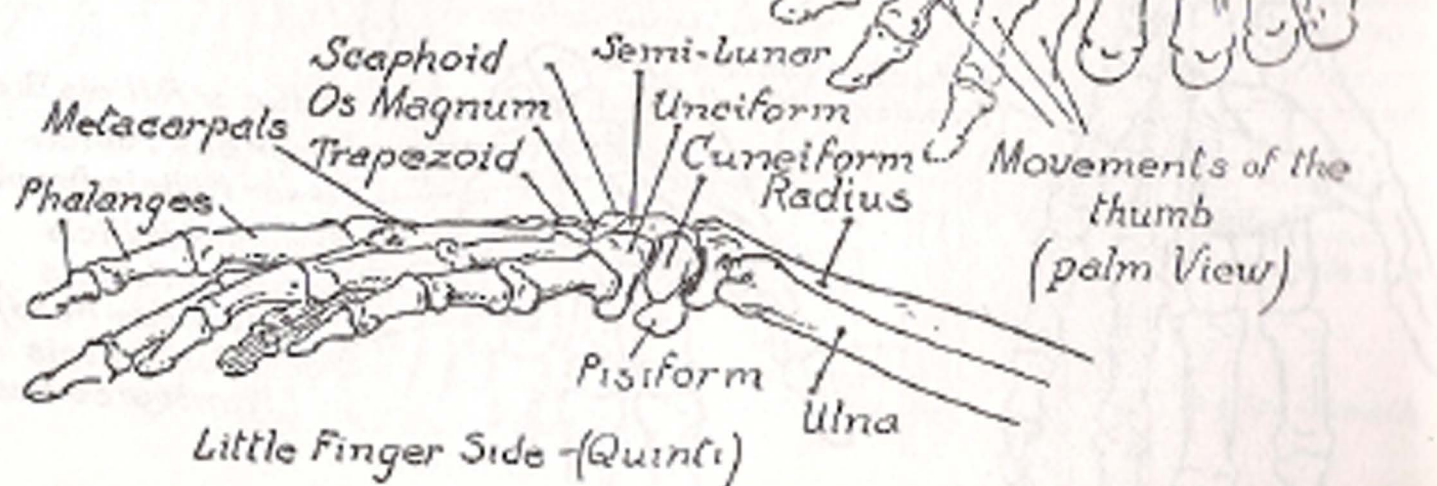
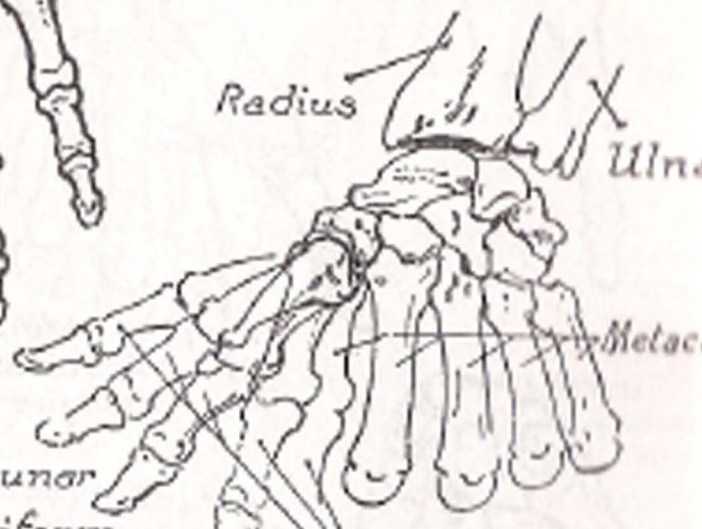
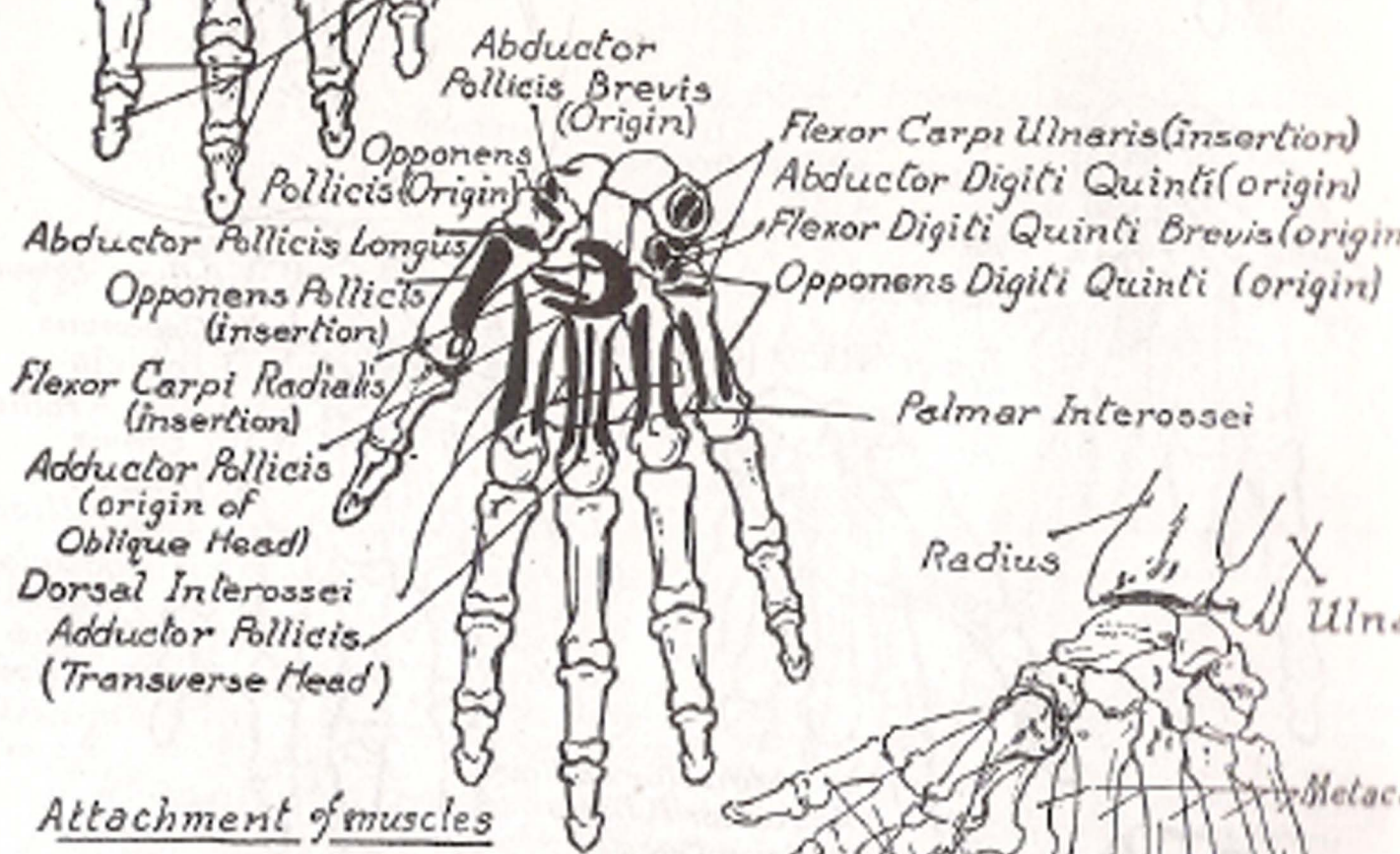
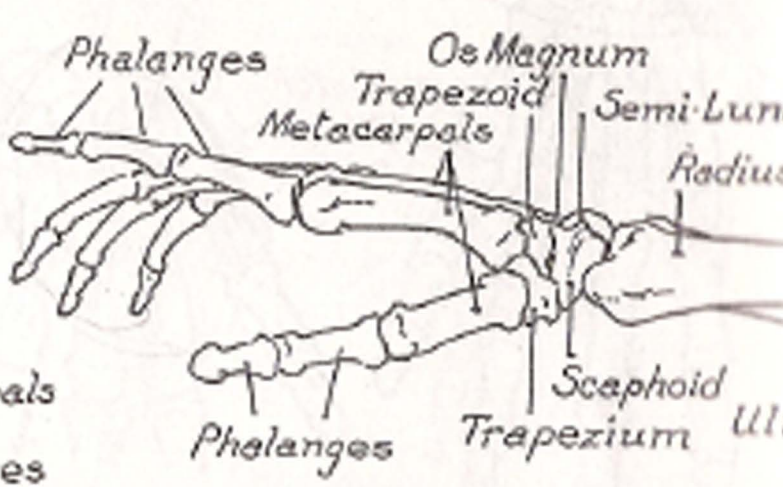
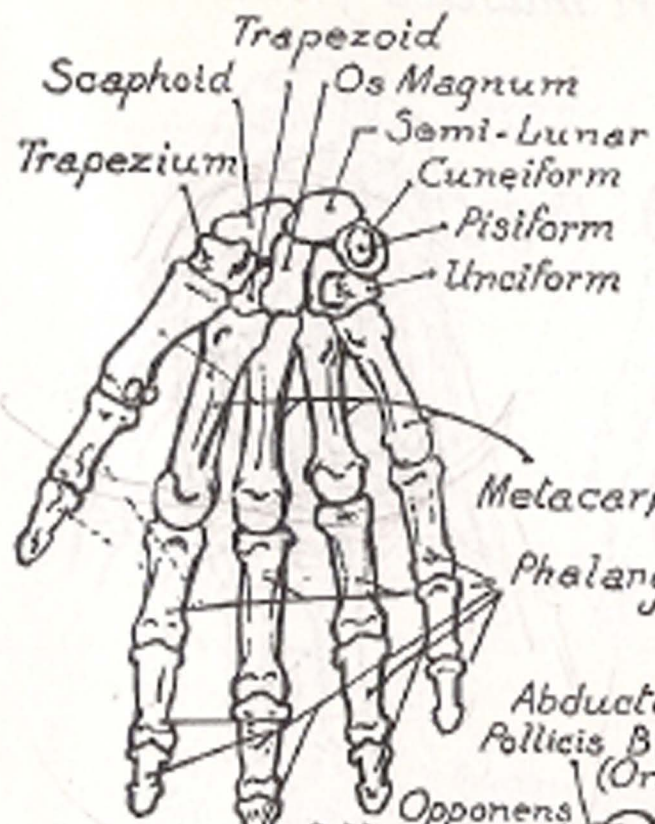




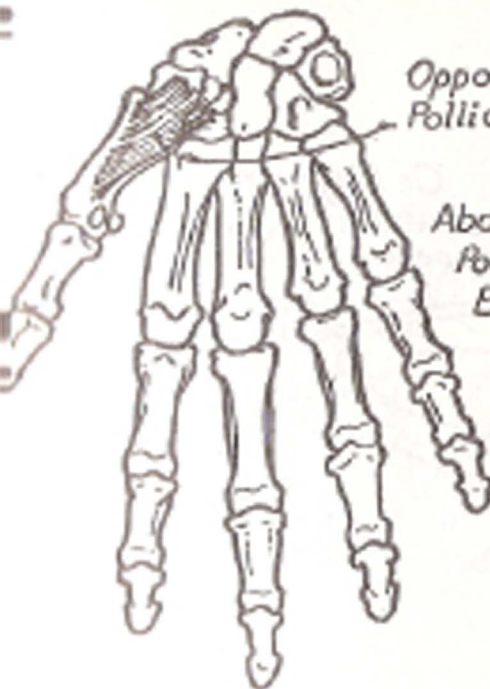






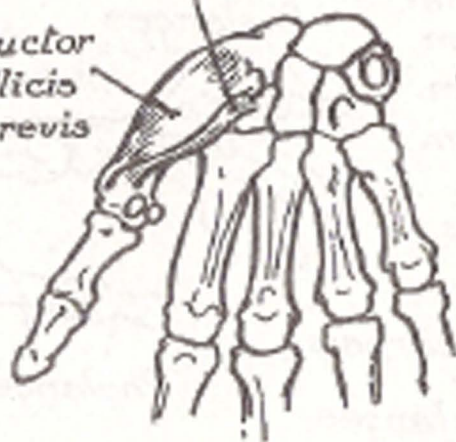


# Short muscles of thumb

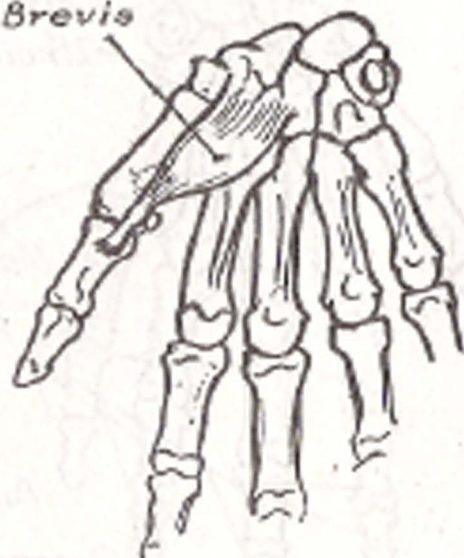

Opponens Pollicis

Abductor Pollicis Brevis



Flexor Pollicis Brevis

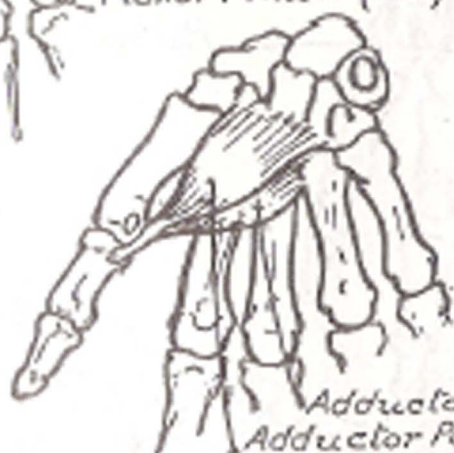

Abductor Pollicis Brevis

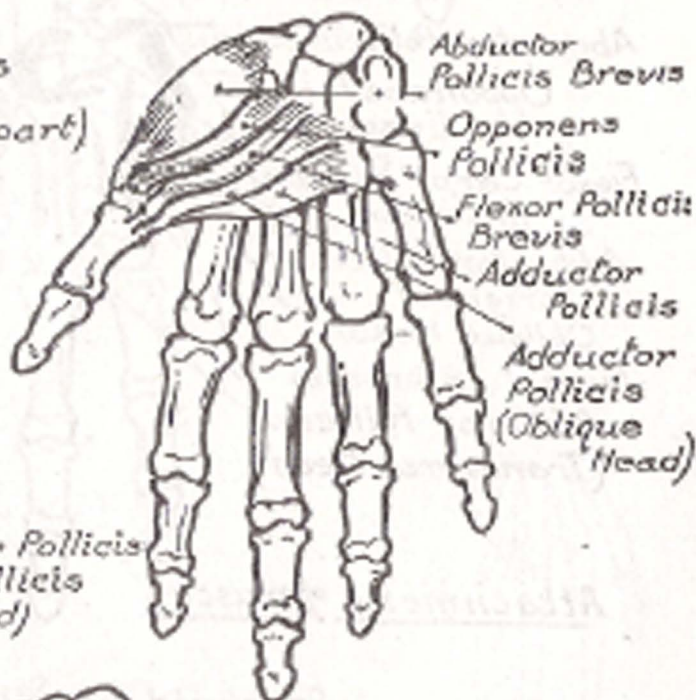
Opponens Pollicis

Flexor Pollicis Brevis

Flexor Pollicis (deep part)



Adductor Pollicis  
Adductor Pollicis (Oblique Head)



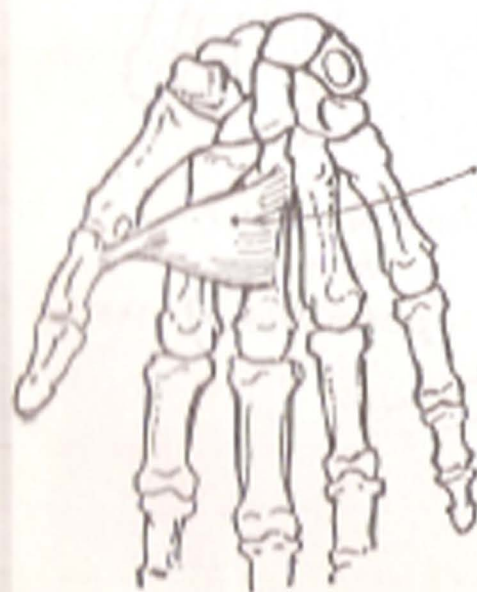Abductor Pollicis Brevis

Opponens Pollicis

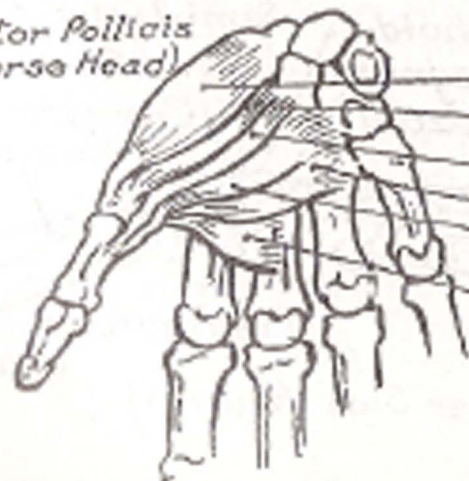
Flexor Pollicis Brevis

Adductor Pollicis

Adductor Pollicis (Oblique Head)



Adductor Pollicis (Transverse Head)



Abductor Pollicis Brevis

Opponens Pollicis

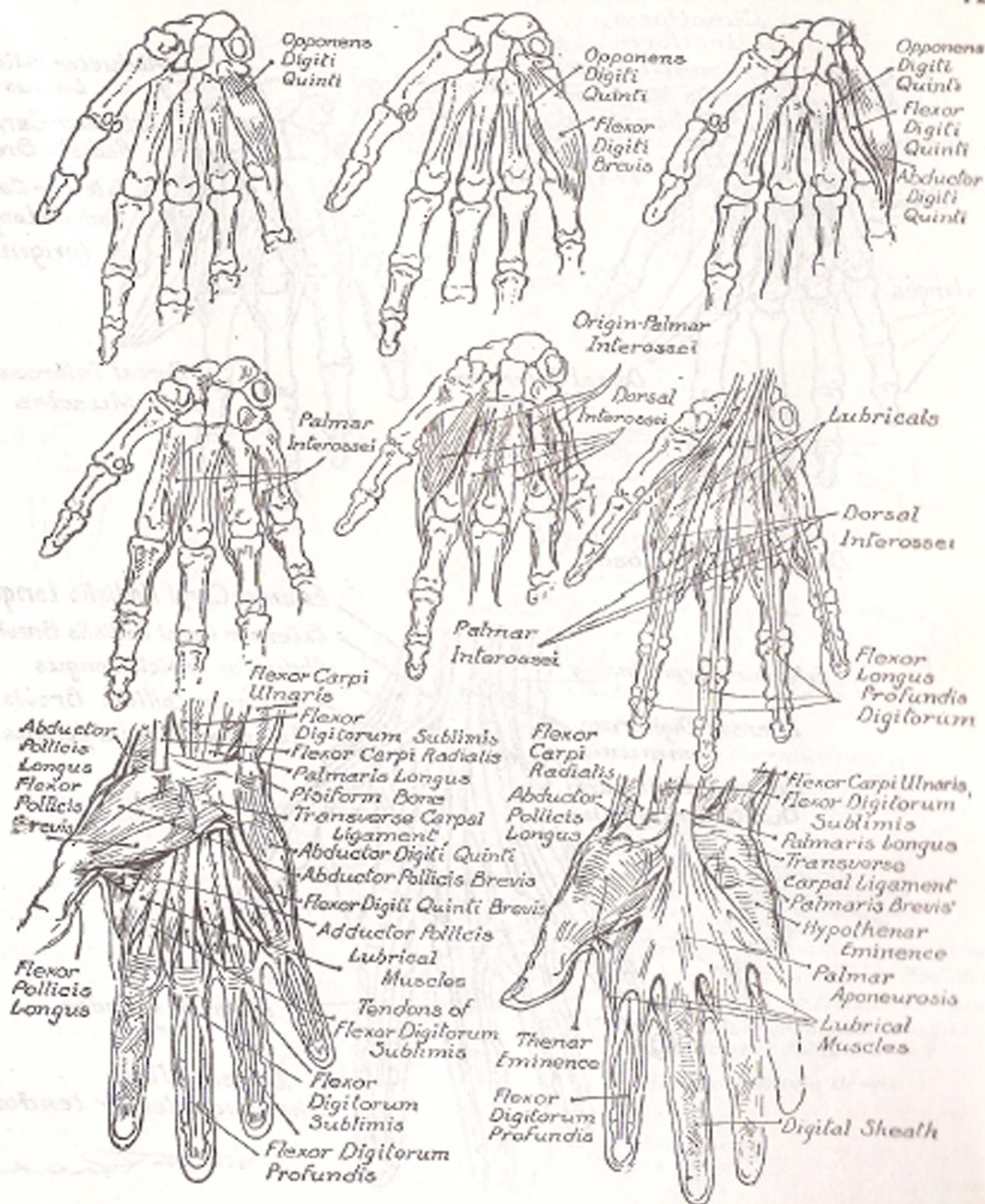
Flexor Pollicis Brevis

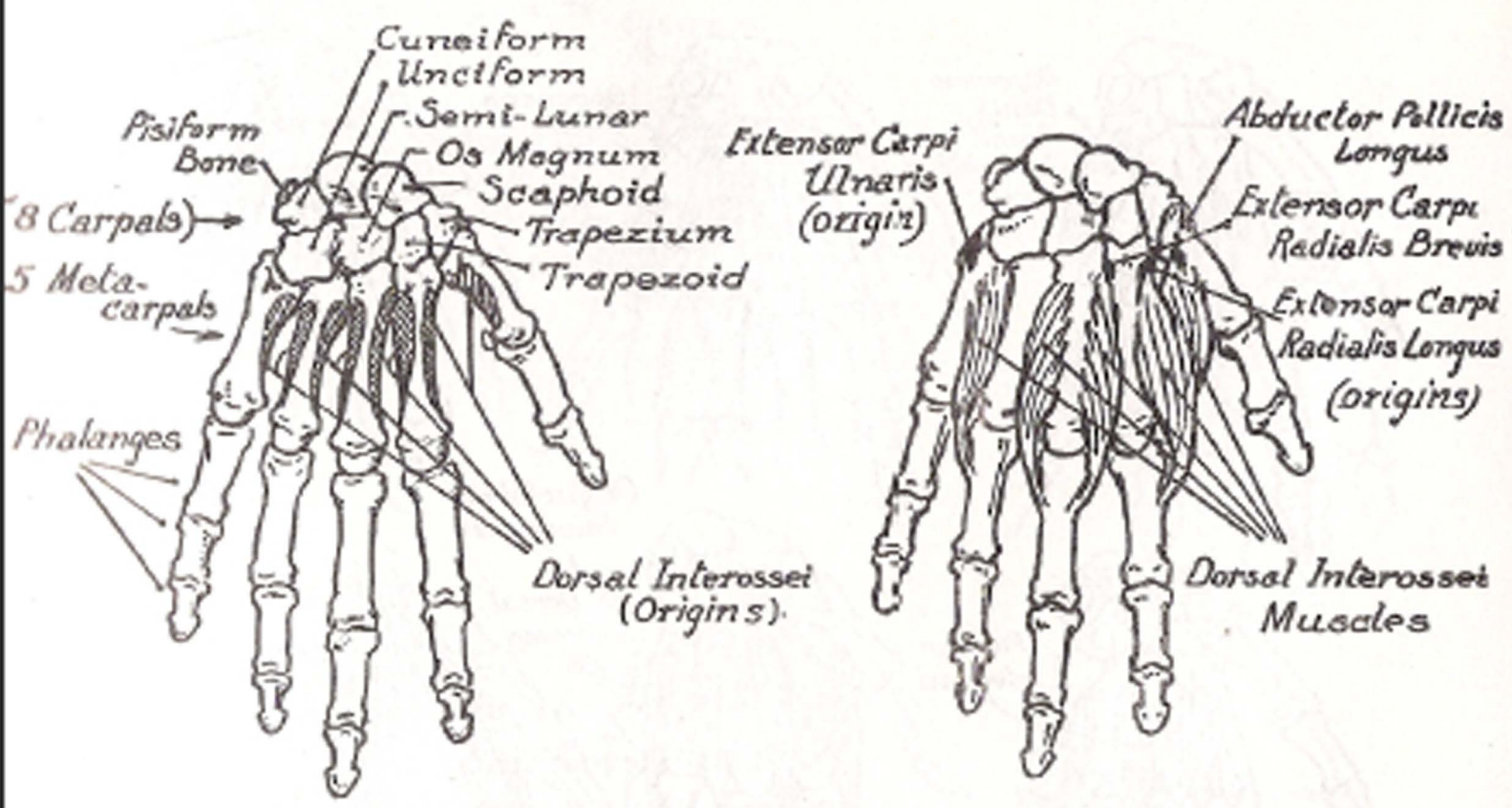
Adductor Pollicis

Adductor Pollicis (Oblique Head)

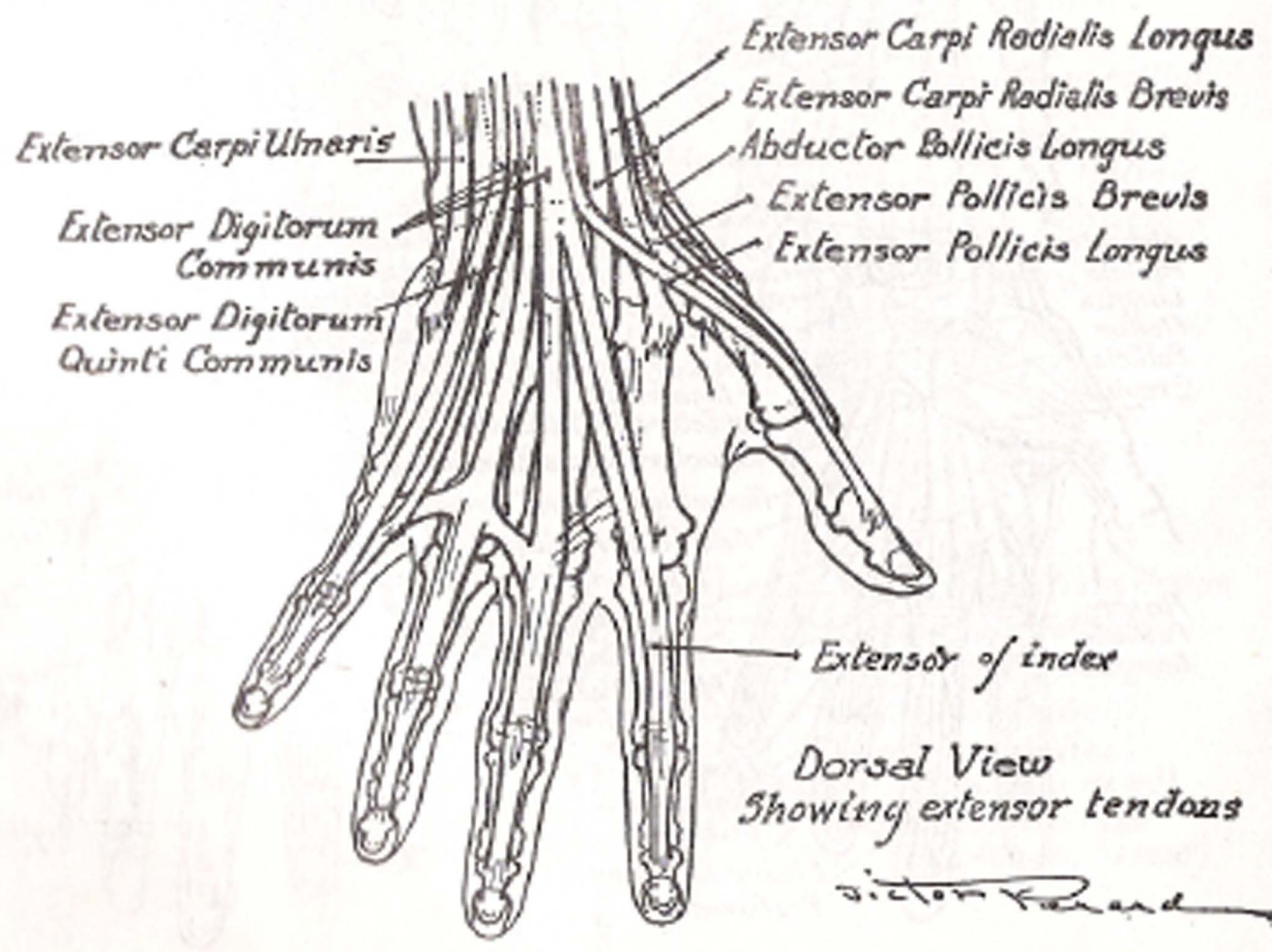
Adductor Pollicis (Transverse Head)





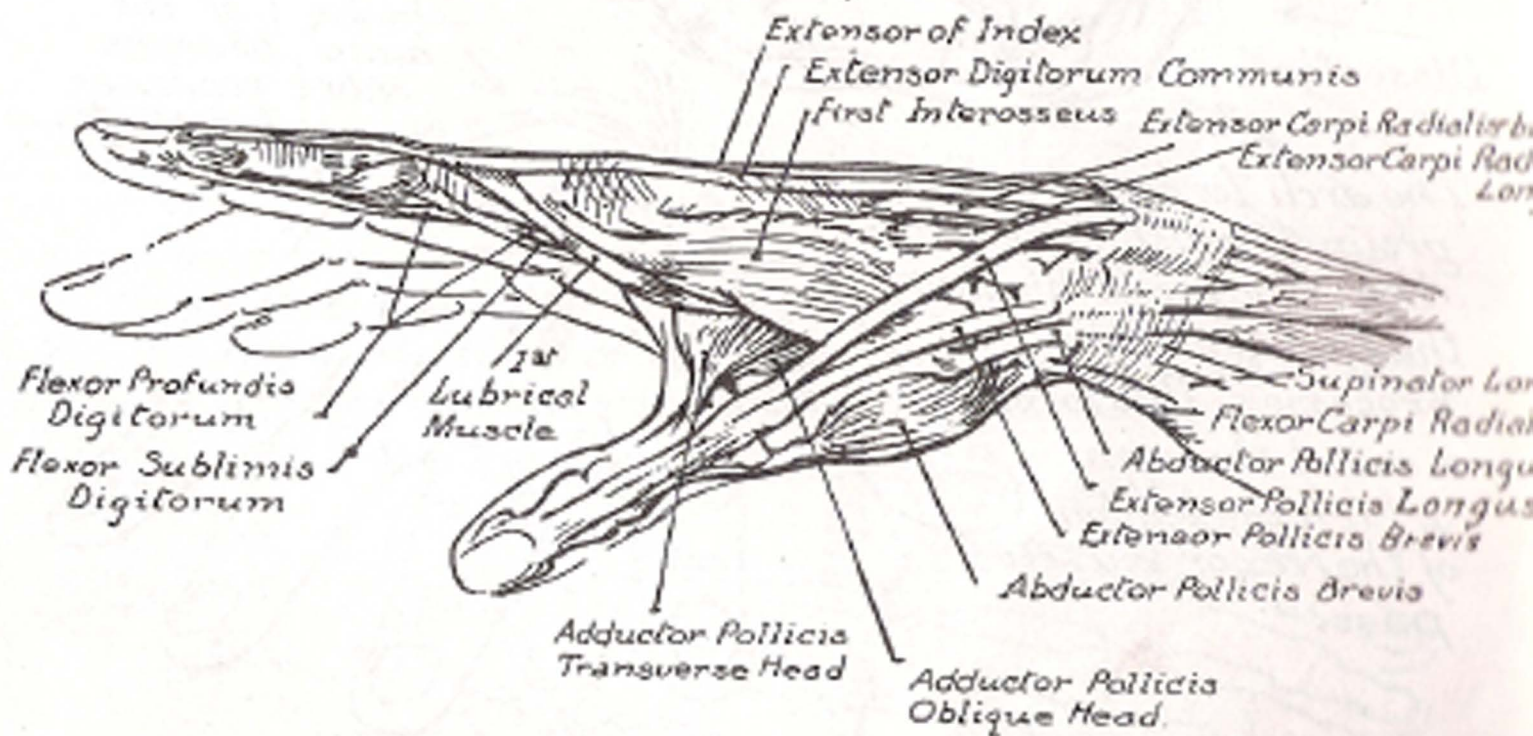

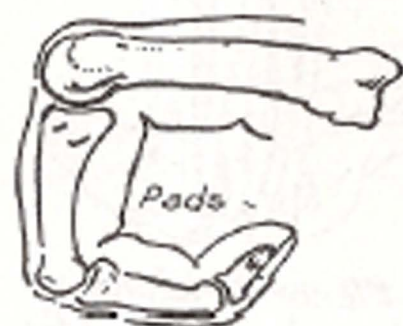
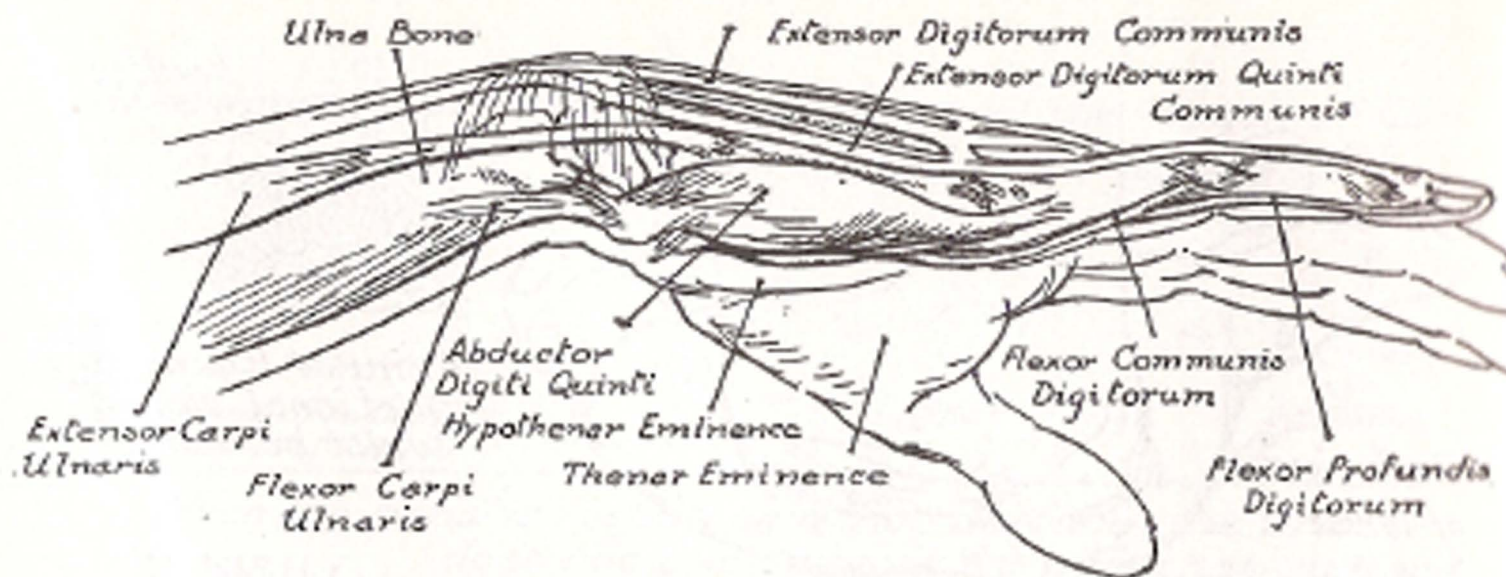

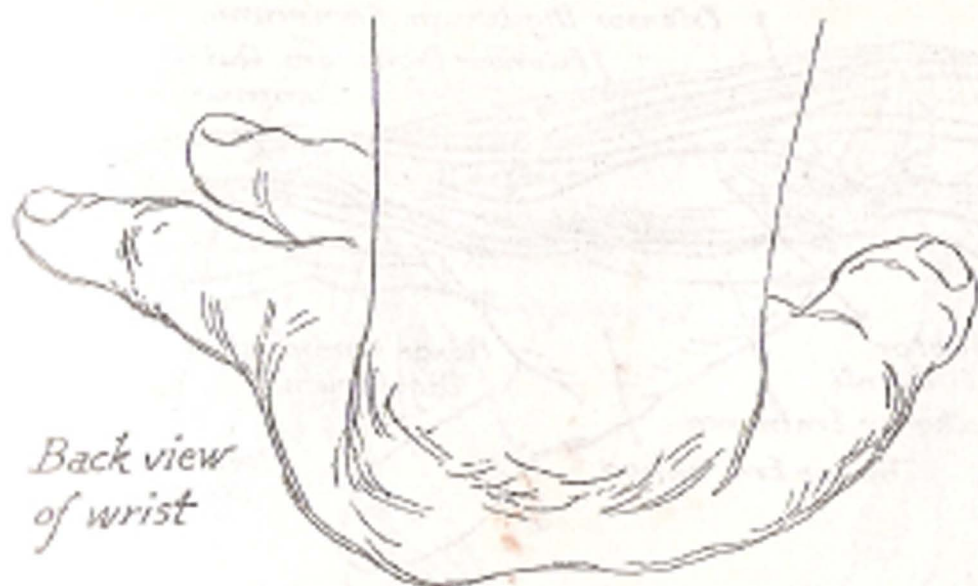
Dorsal View (back)



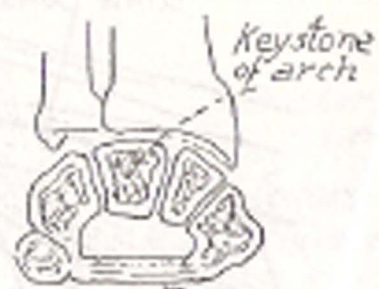
Dorsal View  
Showing extensor tendons

*Victor Rend*

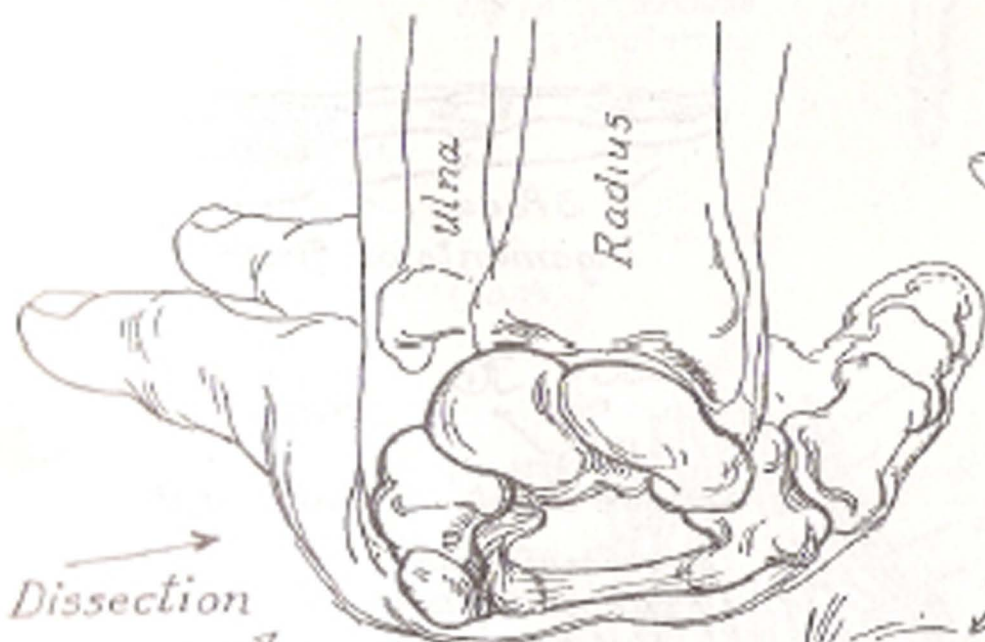




*Back view  
of wrist*

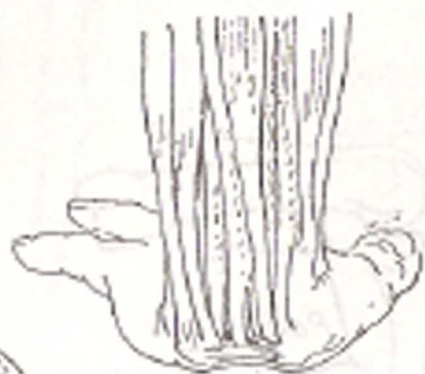

*Keystone  
of arch*  
*Annular ligament.  
Sectional view of  
wrist bones*



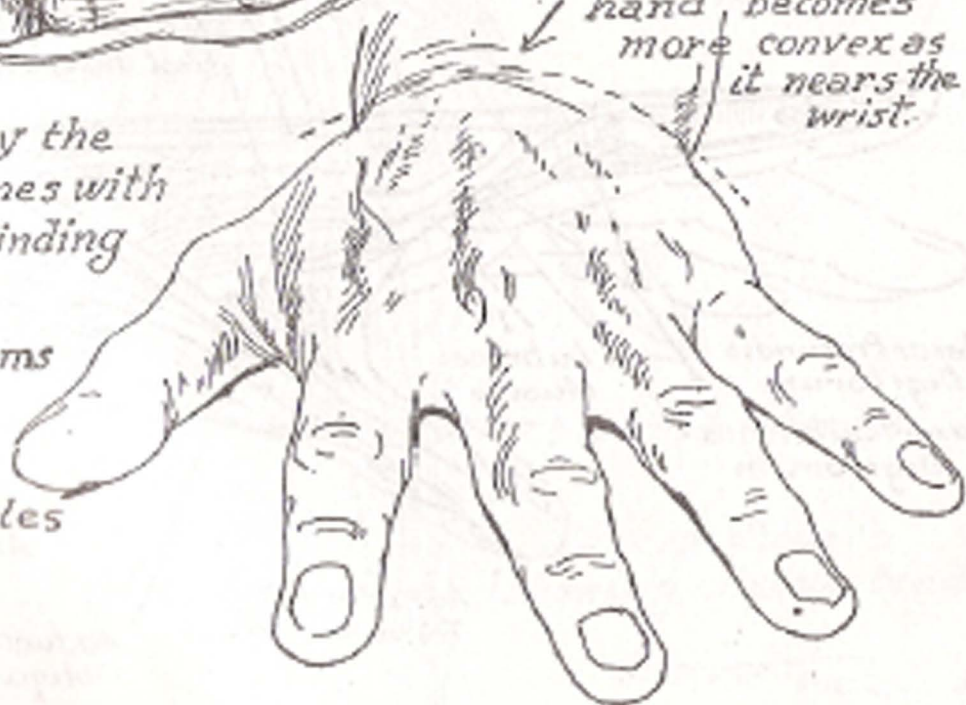*Dissection*

*The arch formed by the group of wrist bones with the ligament binding the two hook like processes. This forms a canal through which the tendons of the flexor muscles pass.*

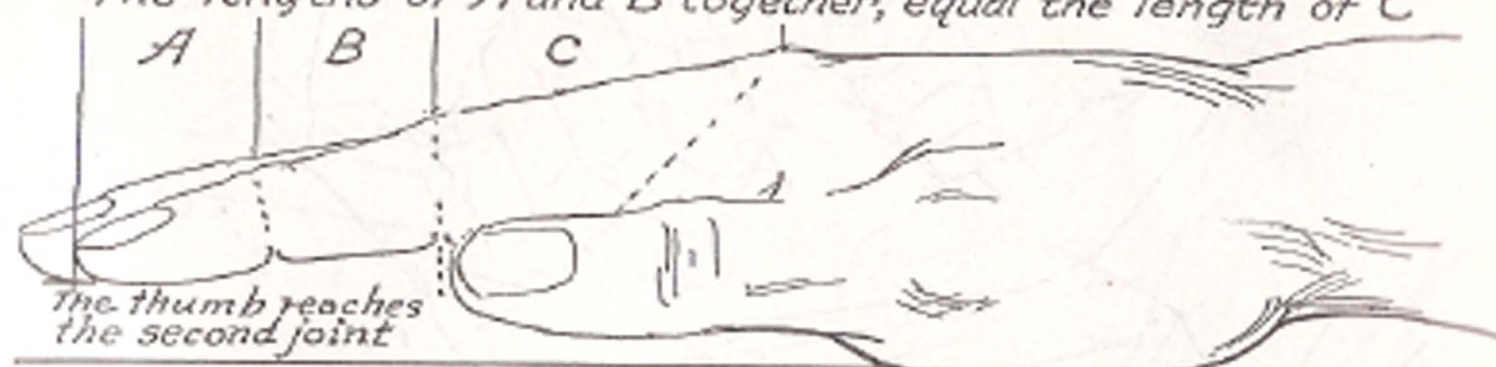


*Flexor tendons  
passing under the  
arch of the wrist  
bones.*

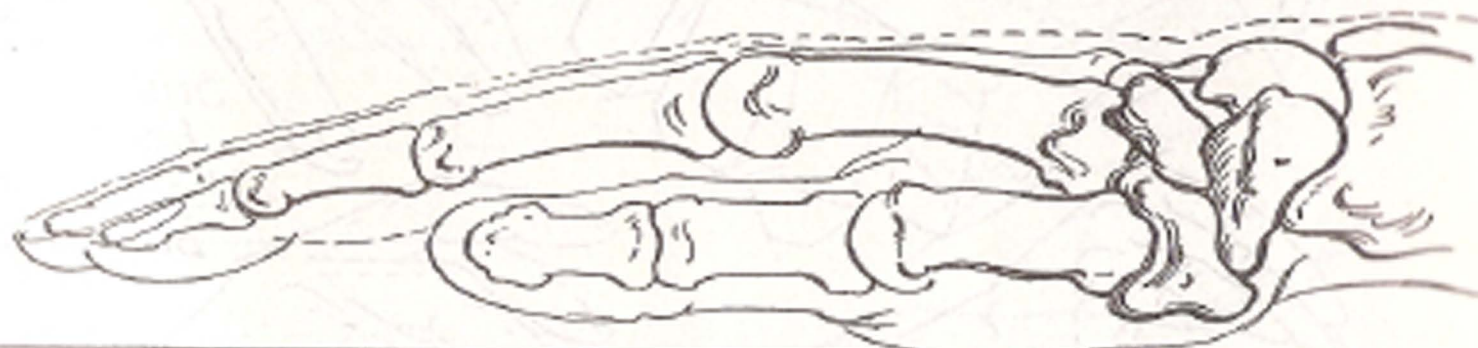*The back of the hand becomes more convex as it nears the wrist.*




The lengths of A and B together, equal the length of C



When the hand is resting on a flat surface, the wrist does not come in contact with that surface.

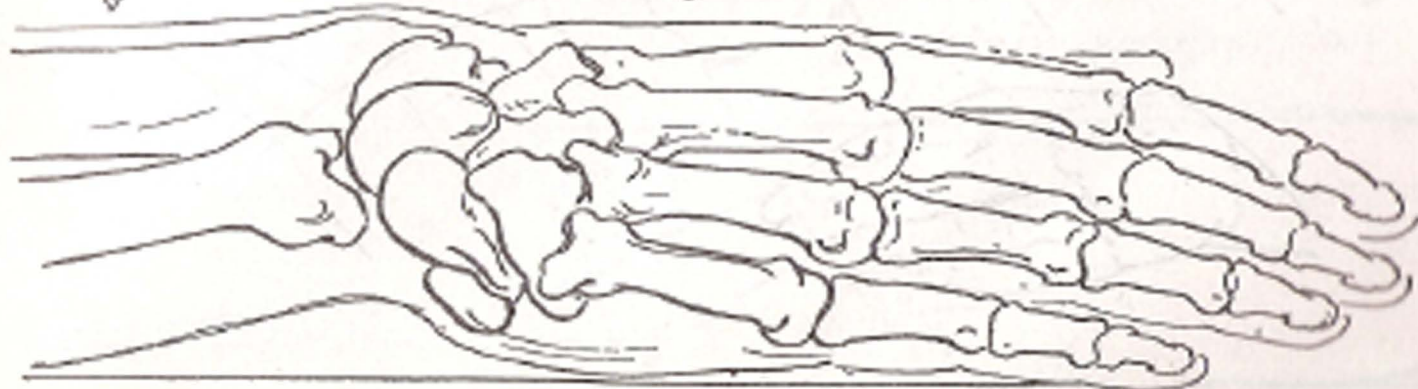

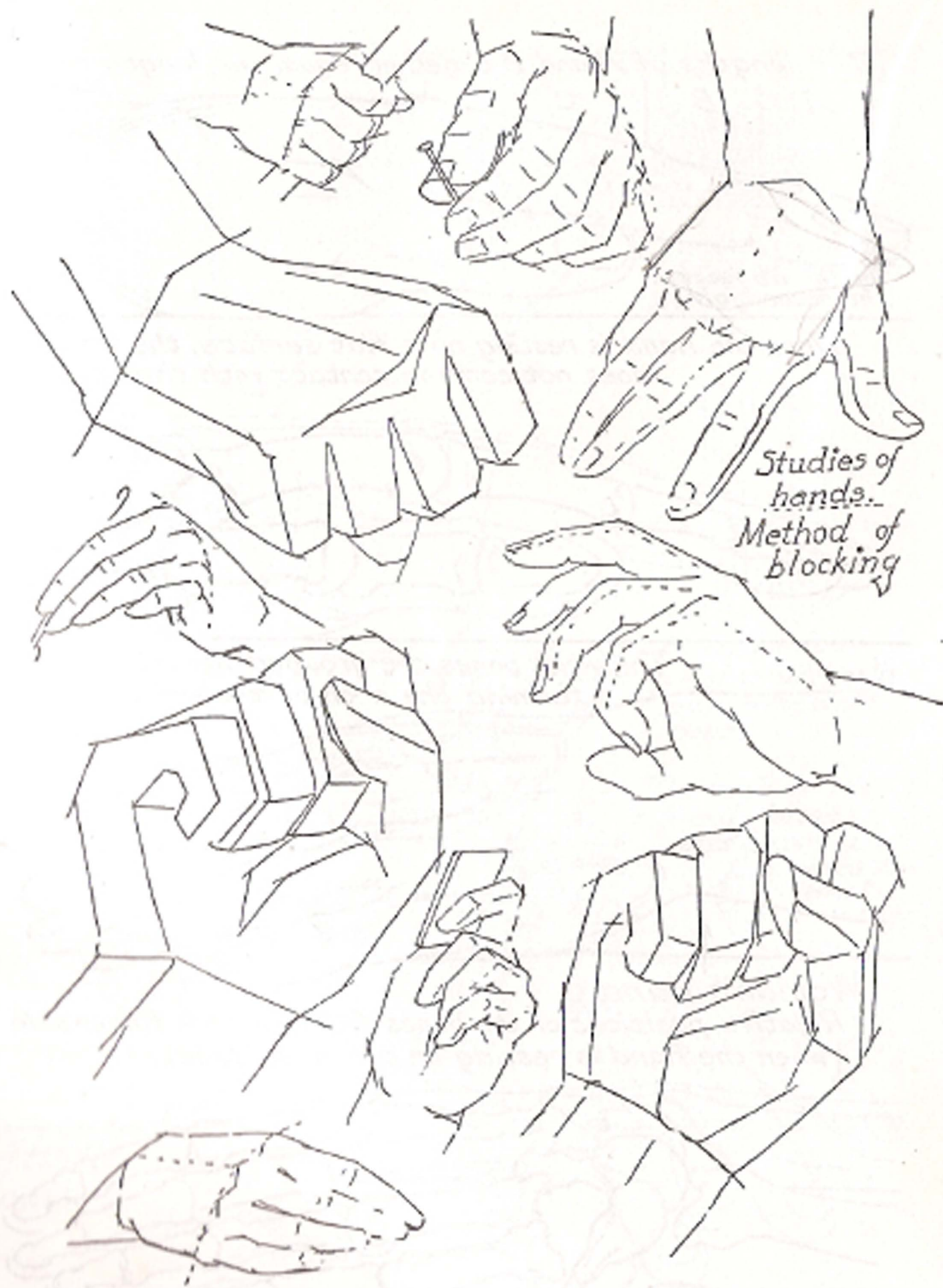
The wrist bones are grouped far into the wrist forming the arch of the wrist.

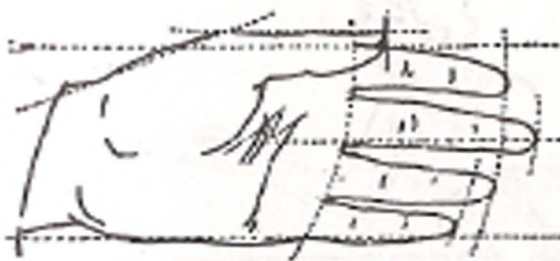
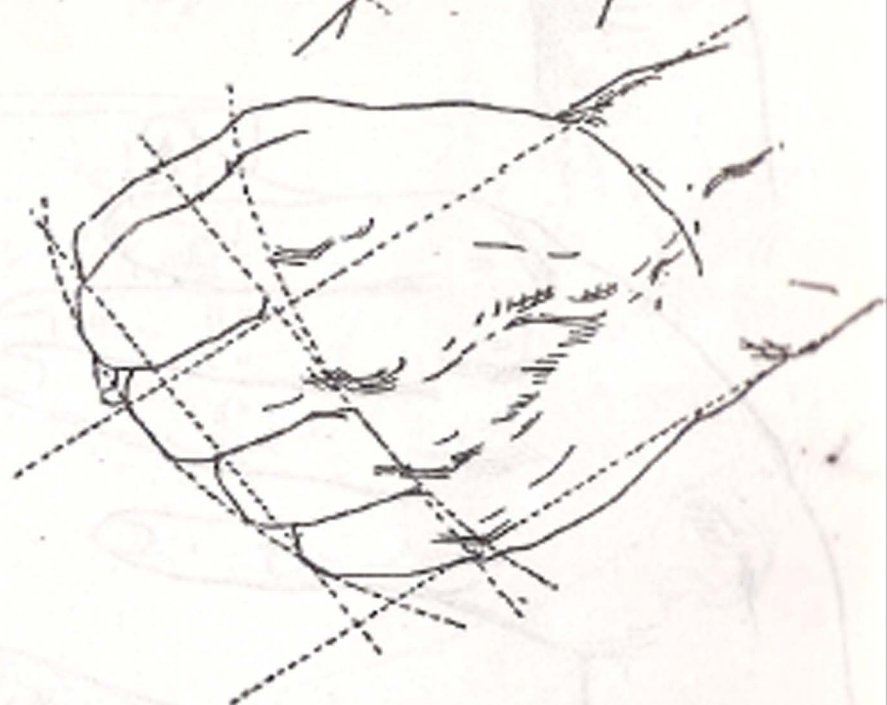
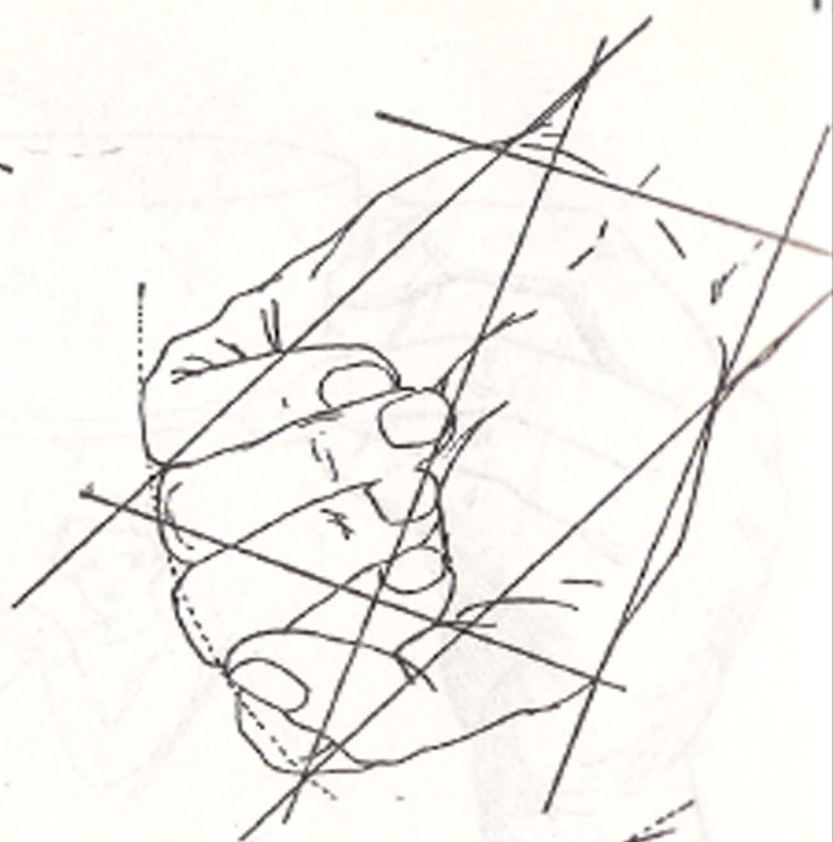
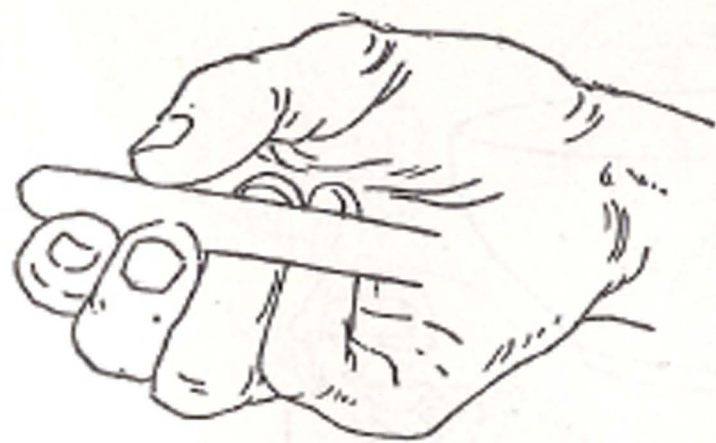


Woman's hand

Relative positions of the bones from the little finger side when the hand is resting on a flat surface.

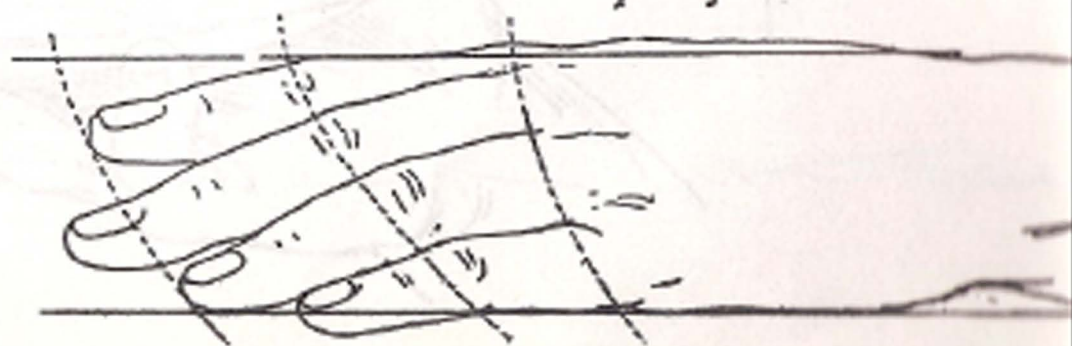

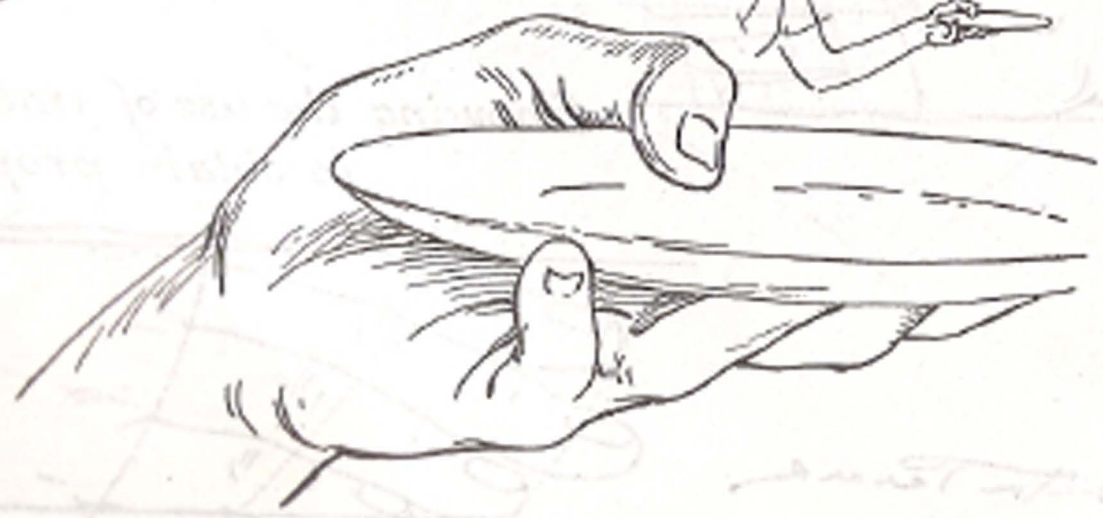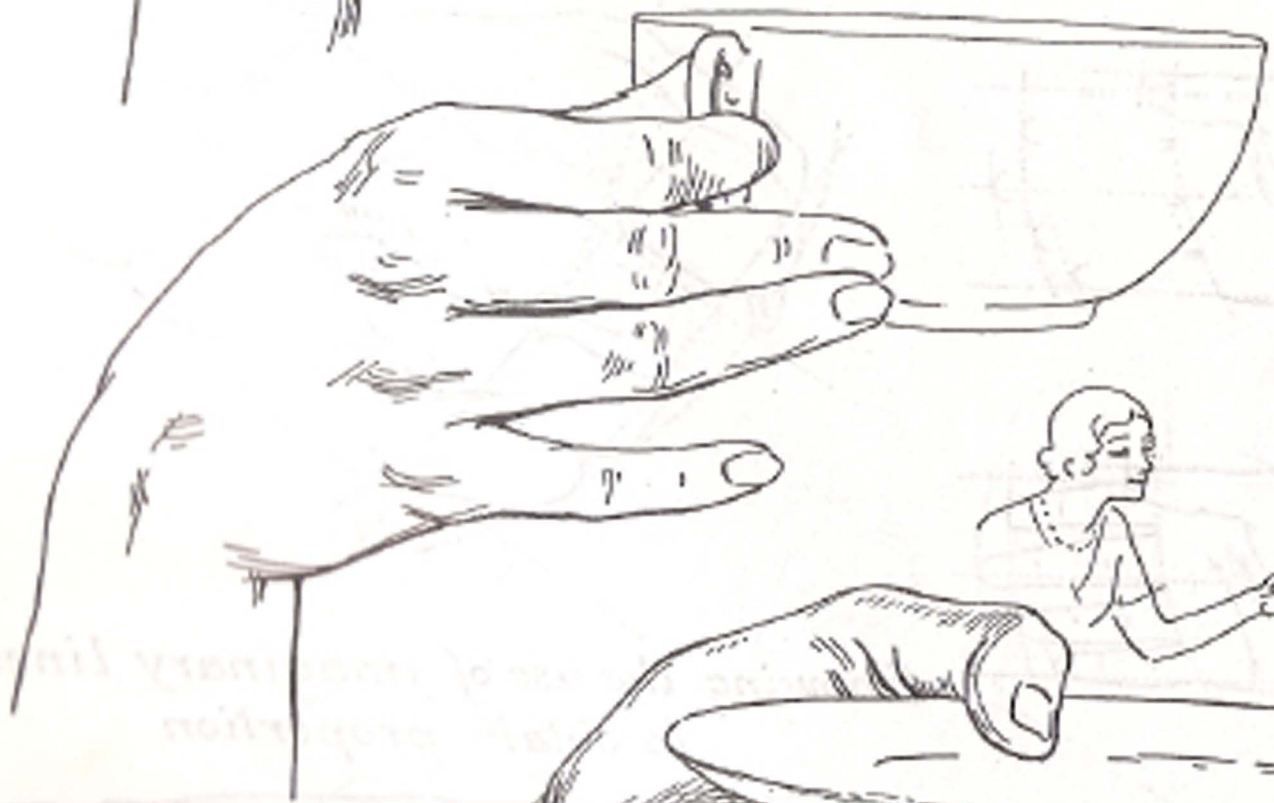




*Showing the use of imaginary line  
to obtain proportion*

*Victor Perard*



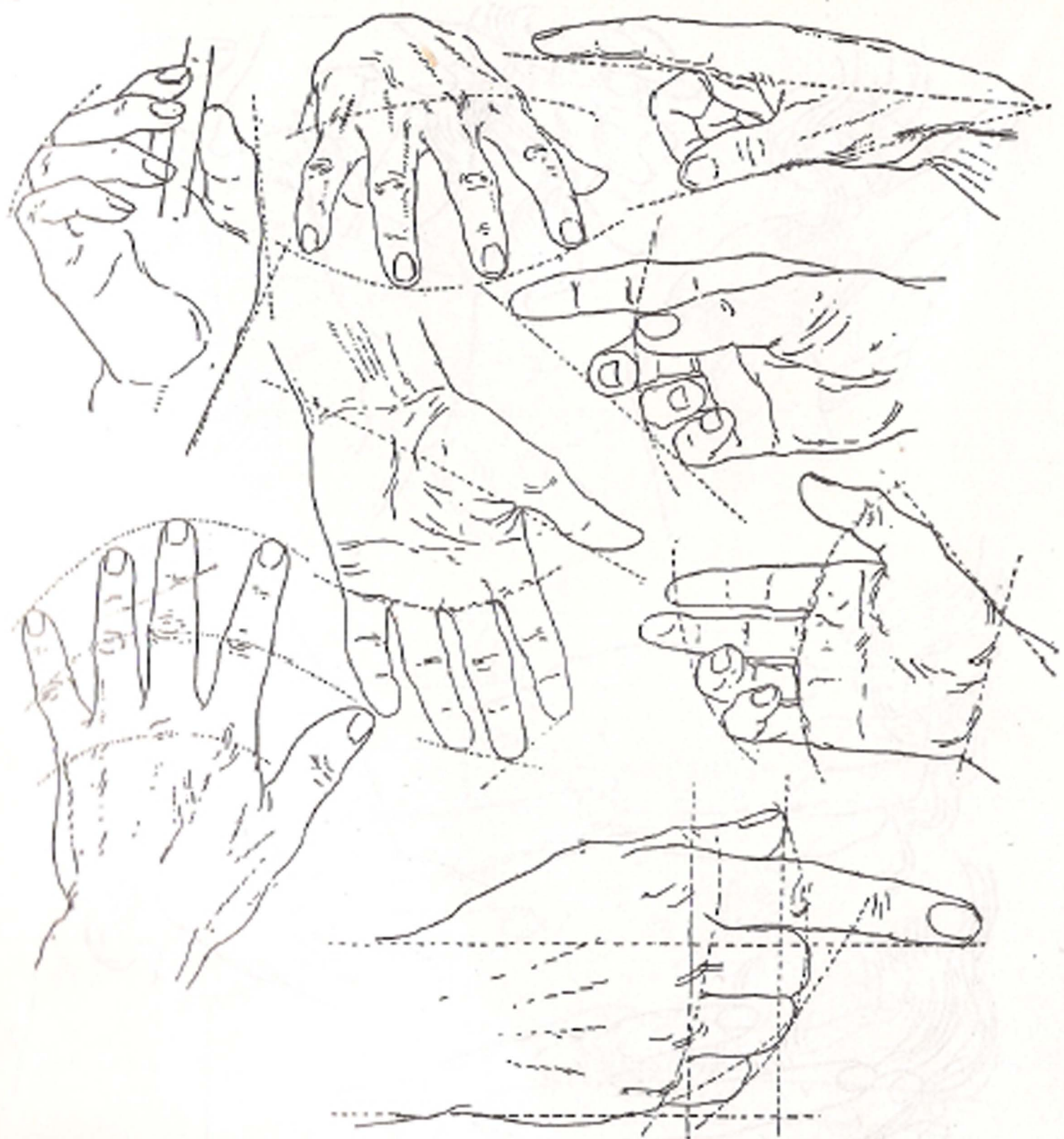




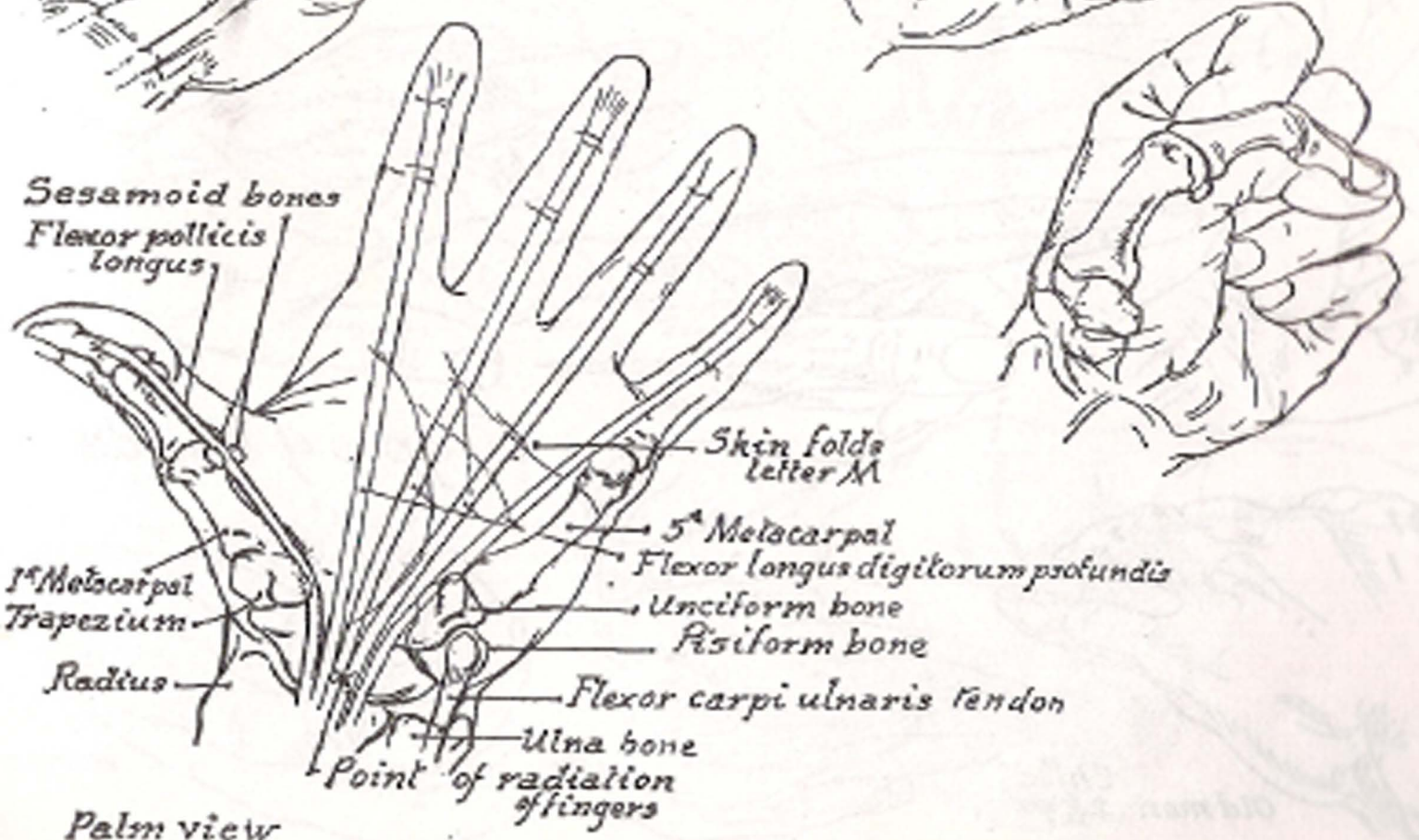
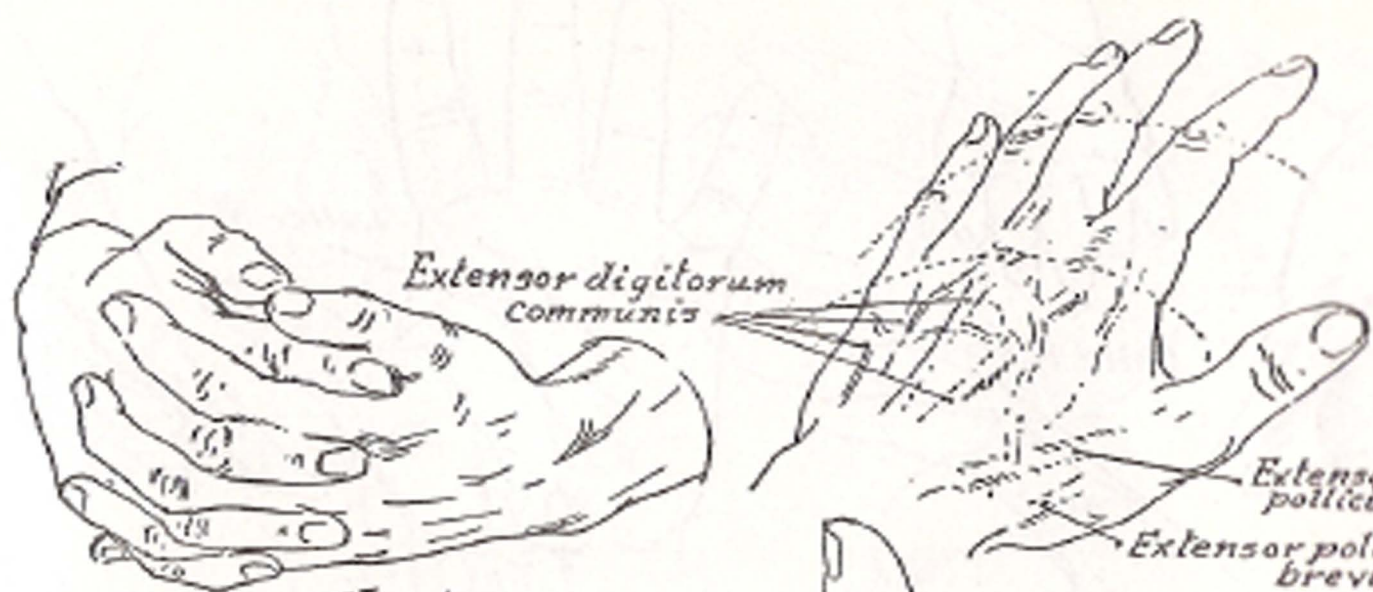

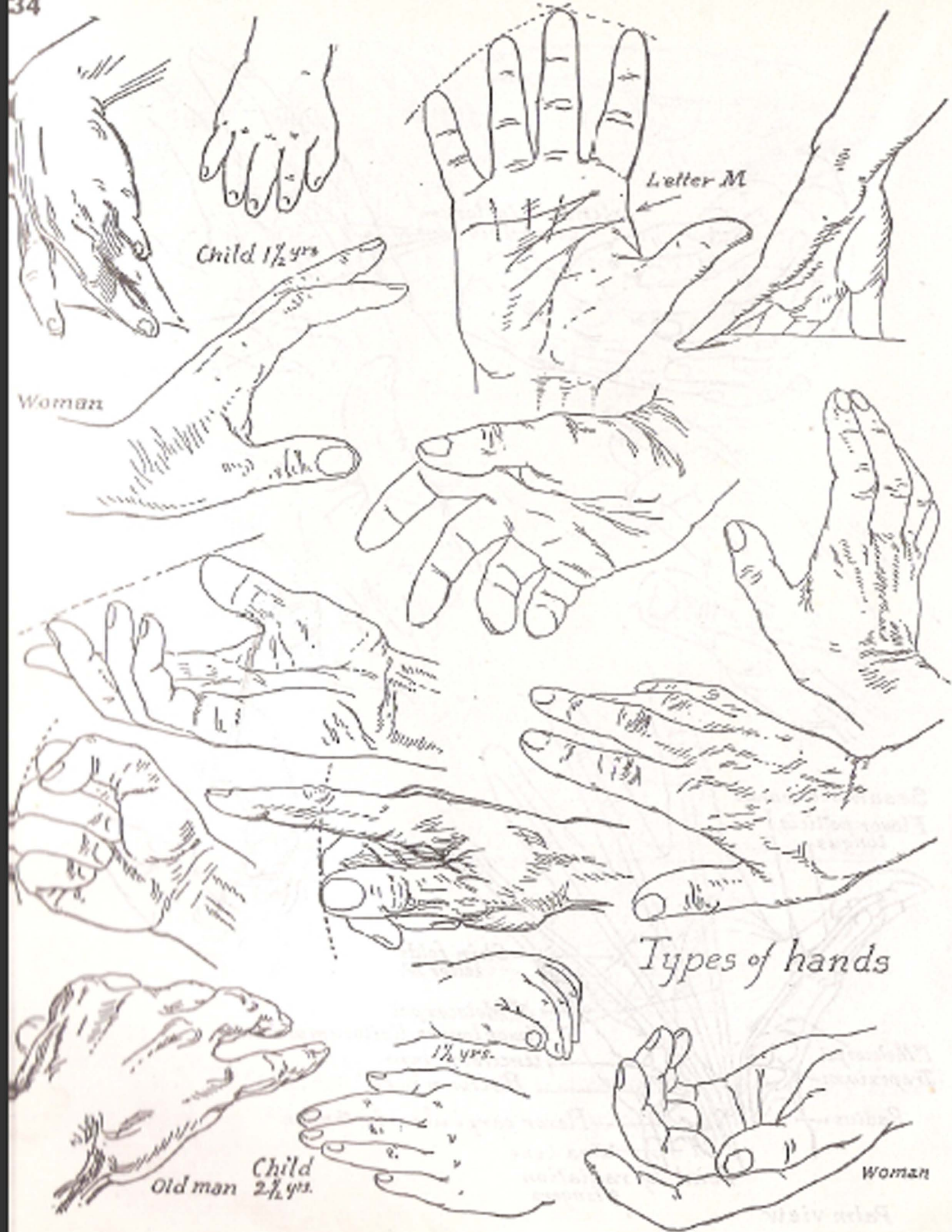
Studies of Hands with Hair

Victor Perard



*Studies of hands with use of imaginary lines  
for proportion*





Child 1 1/2 yrs

Letter M

Woman

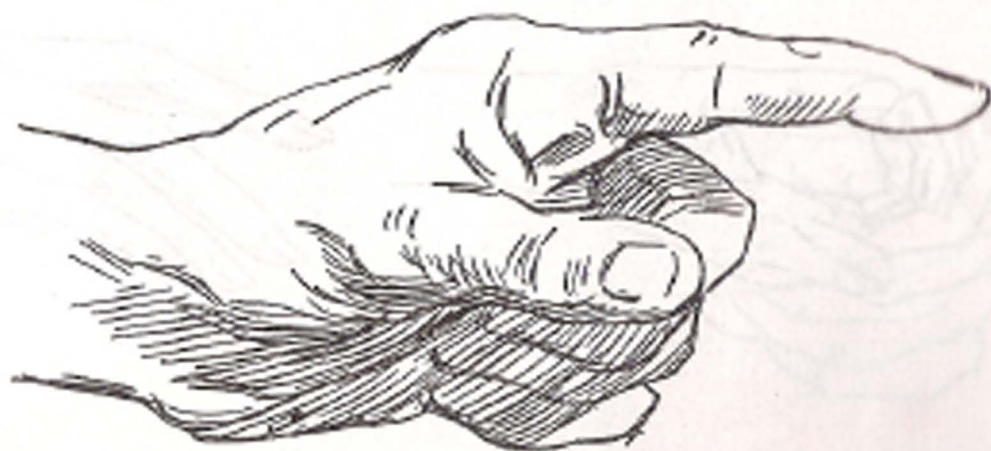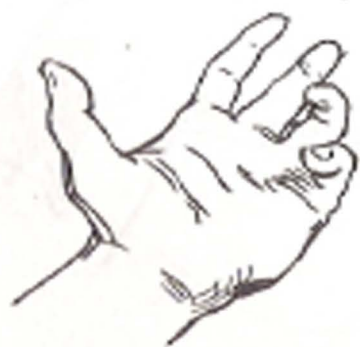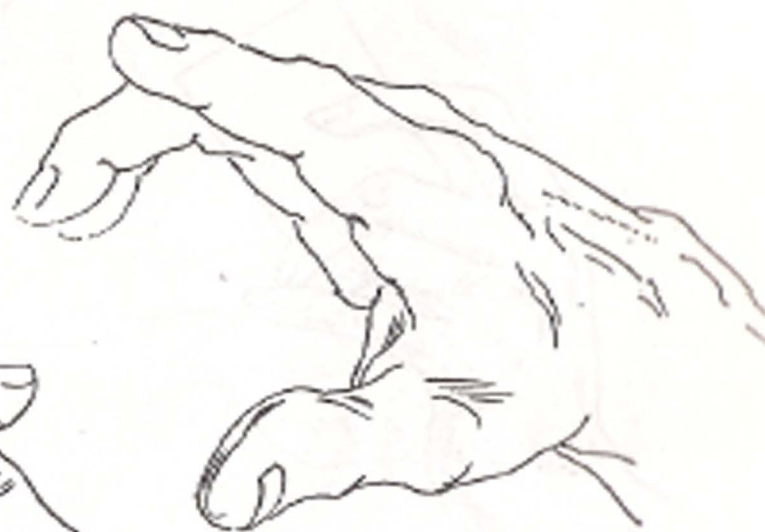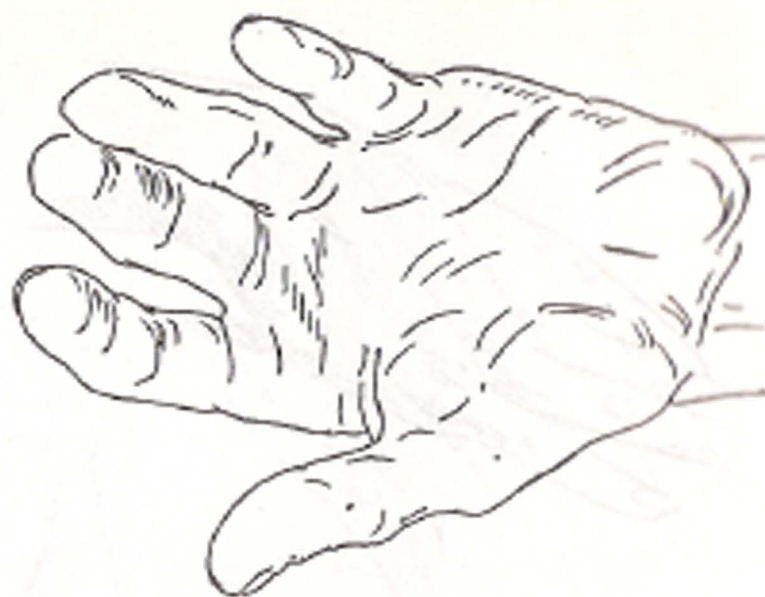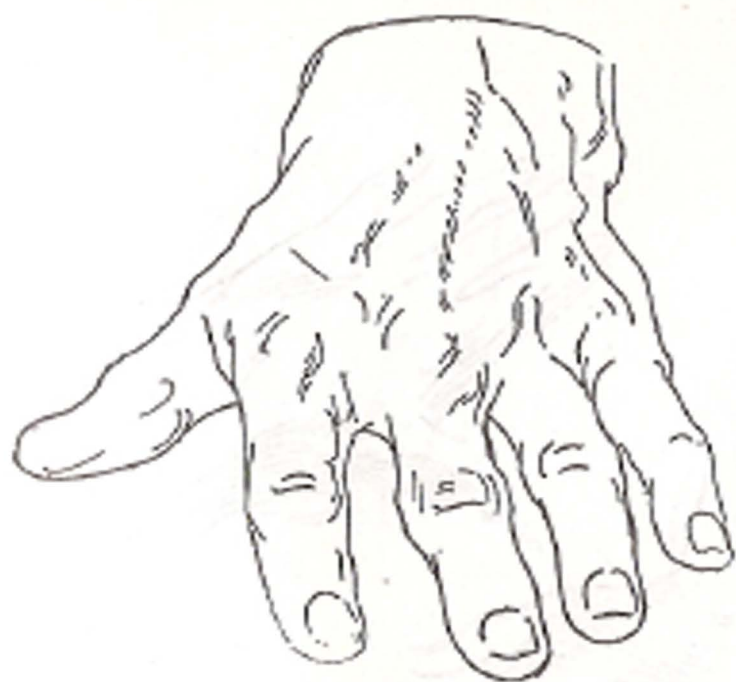Woman

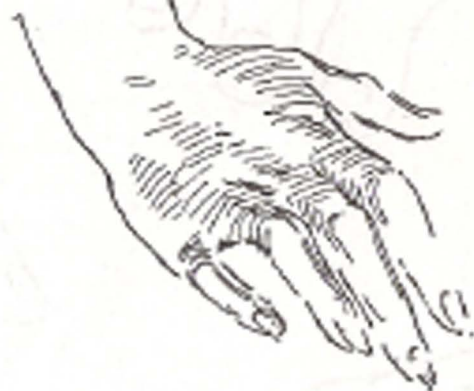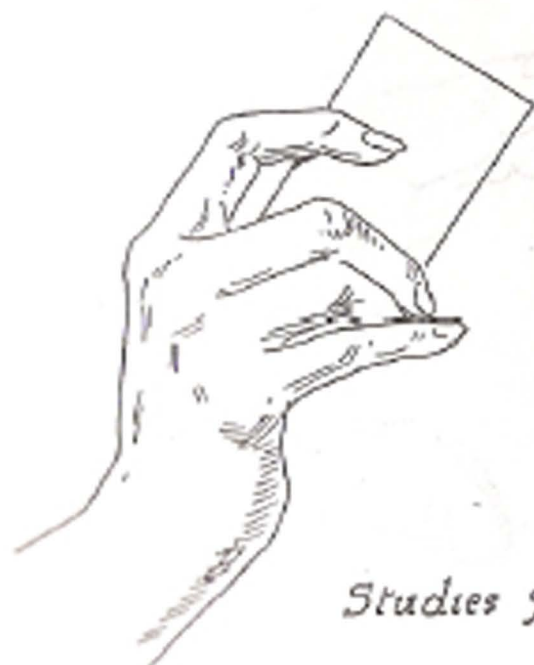Types of hands

Old man Child 2 1/2 yrs

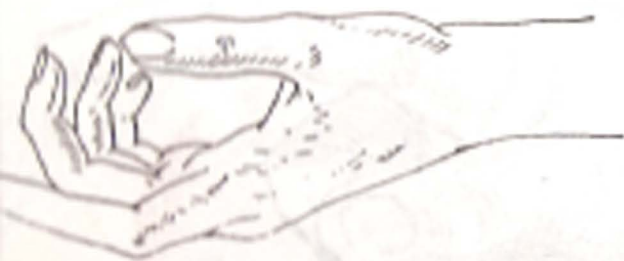1 1/2 yrs.

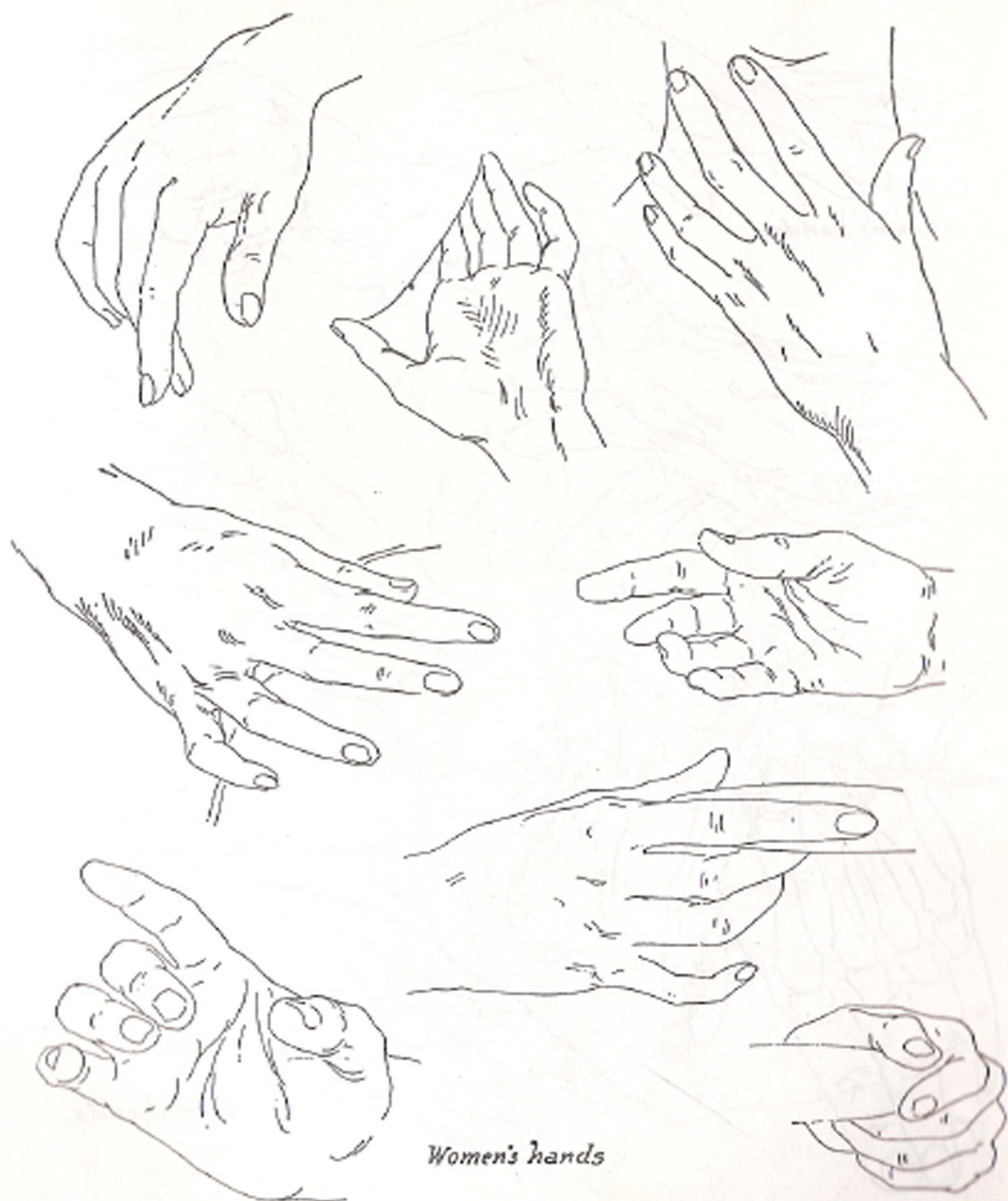
Woman



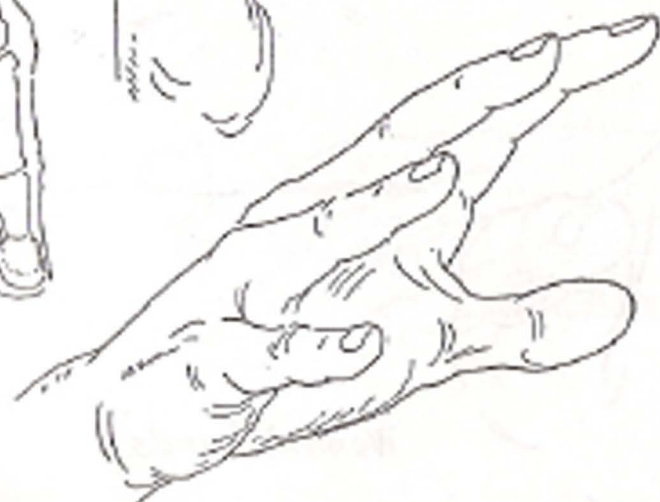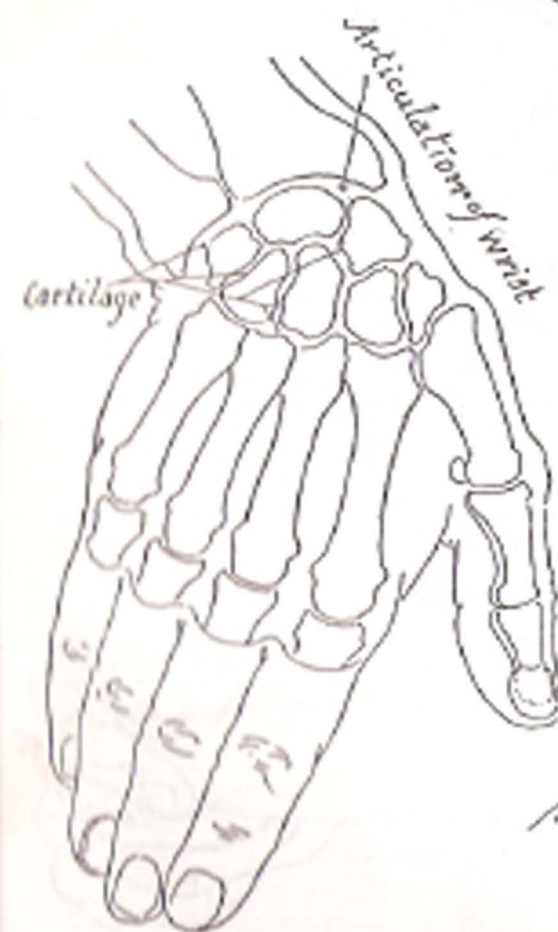

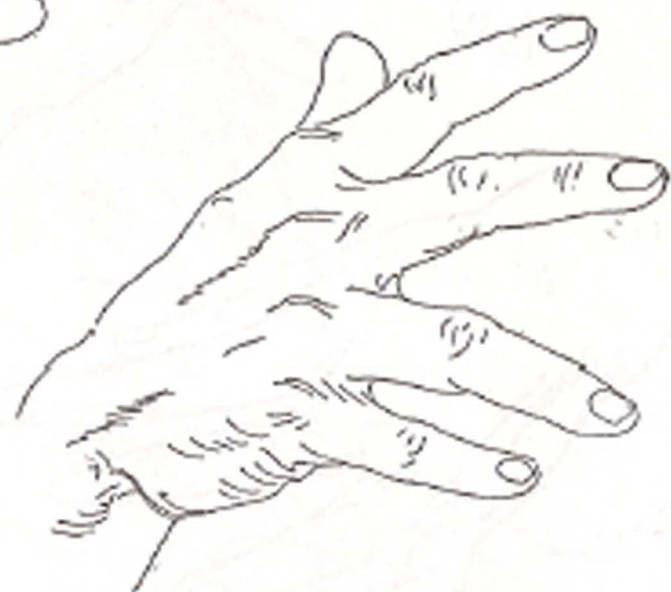
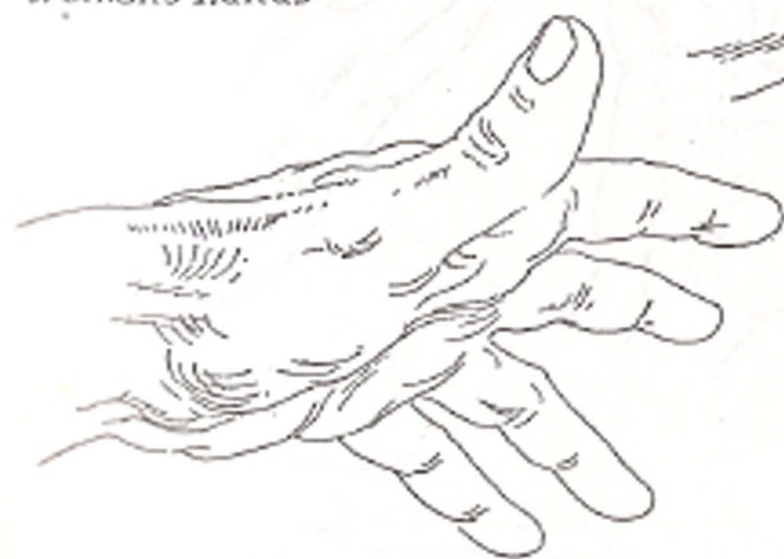*Studies of Women's Hands*

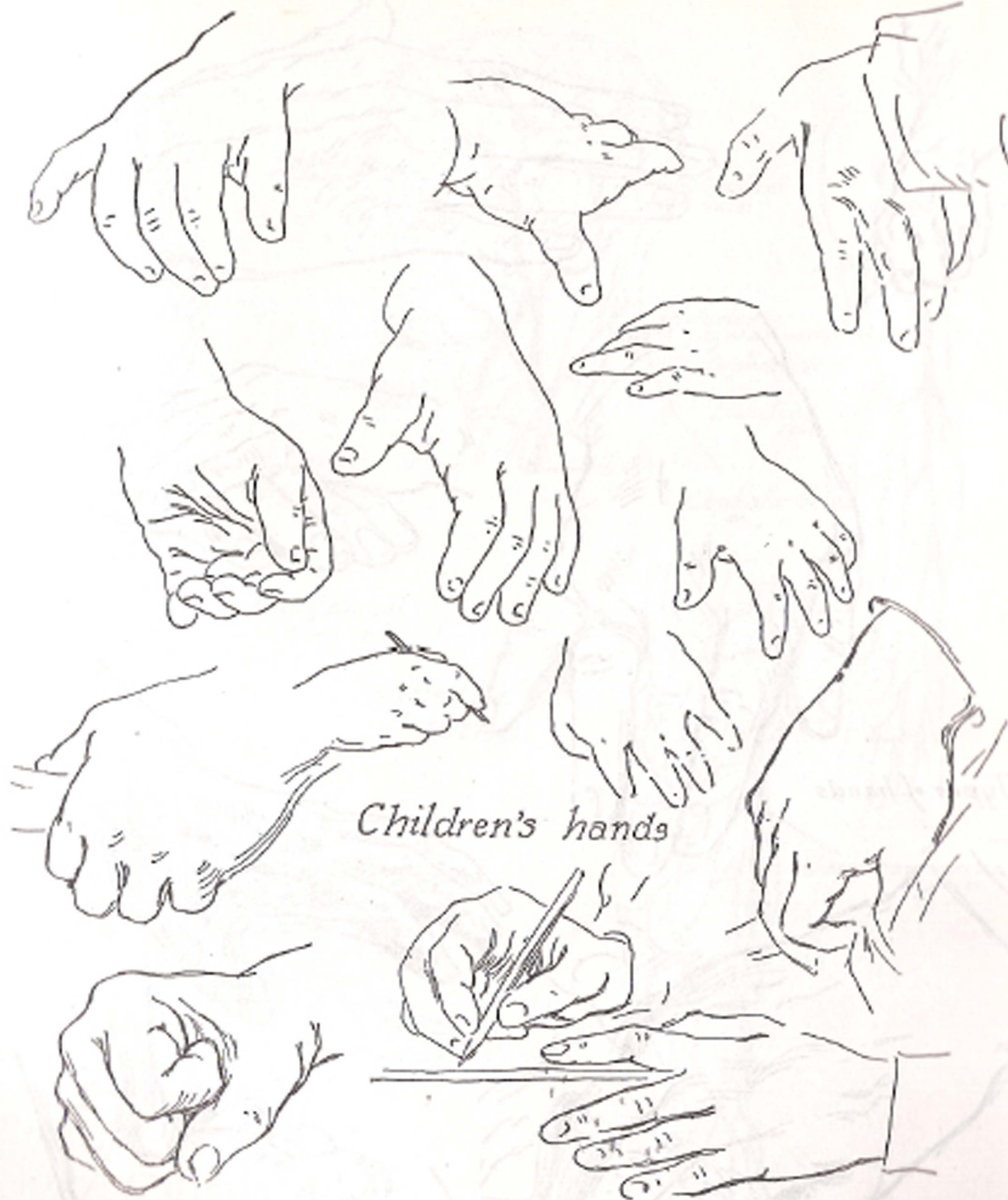




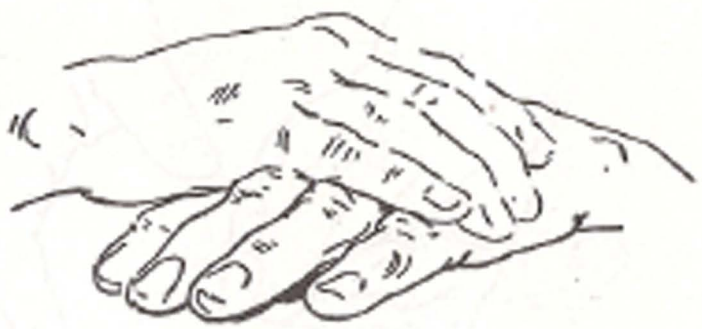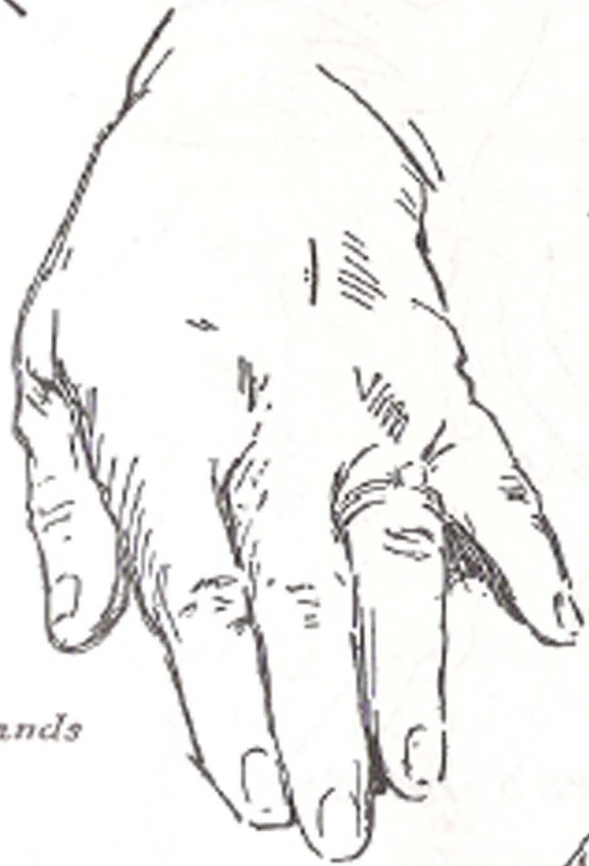
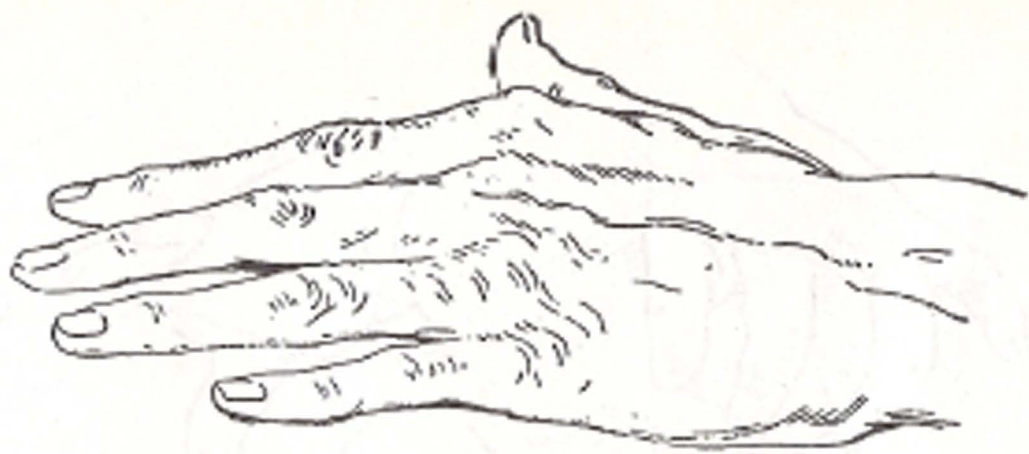
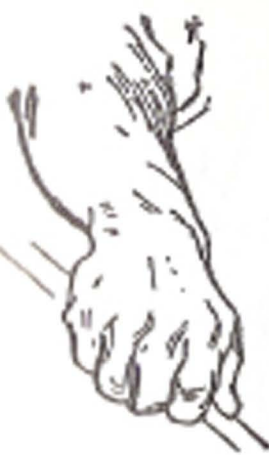*Women's hands*

*Women's hands**Men's hands*

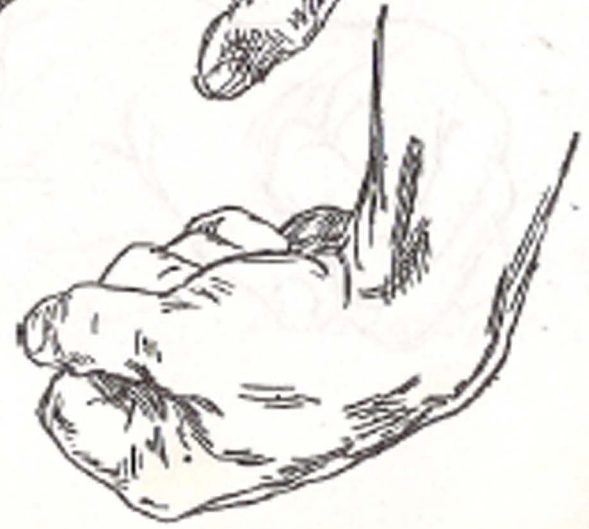
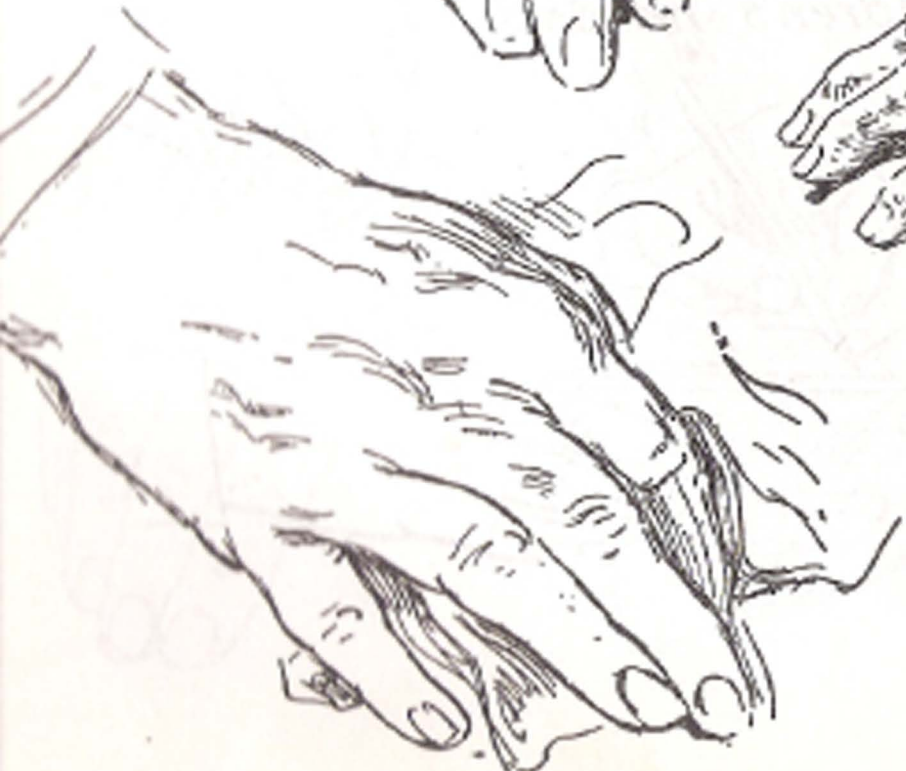
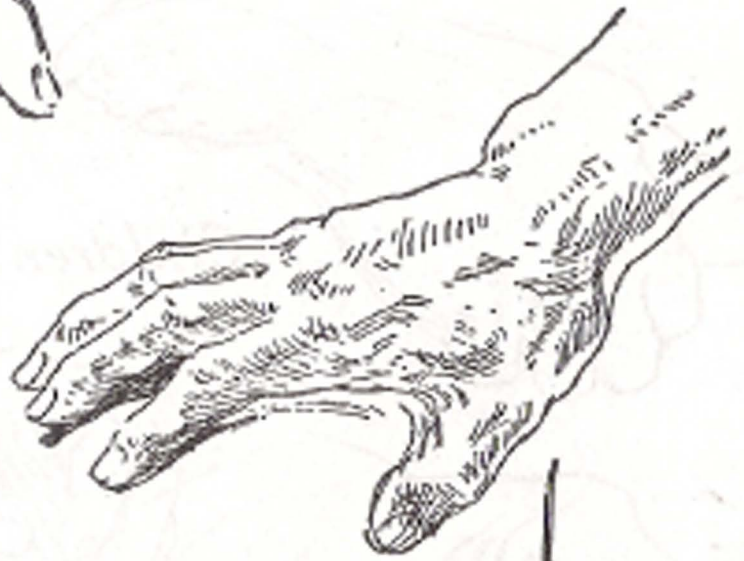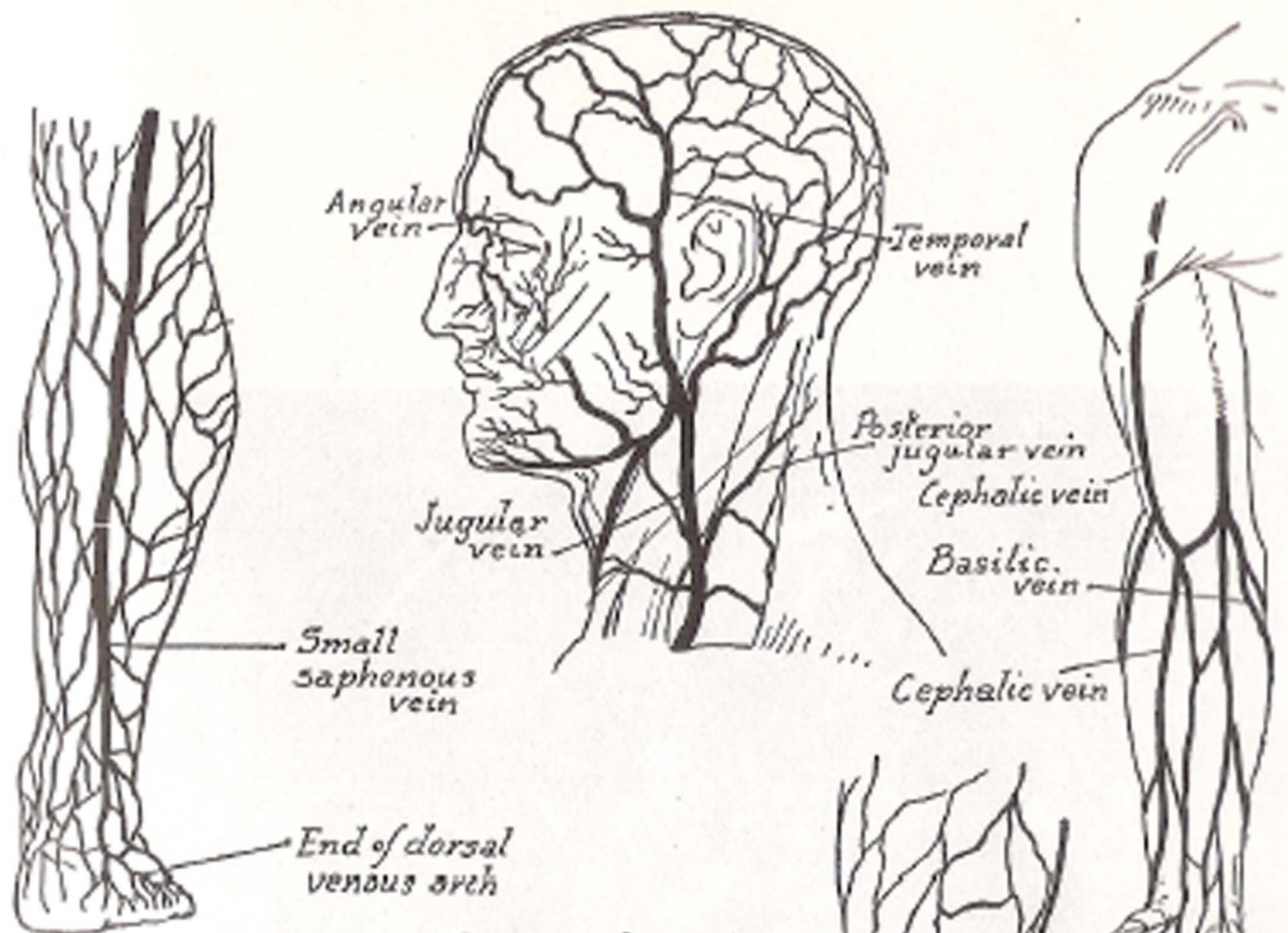


*Children's hands*

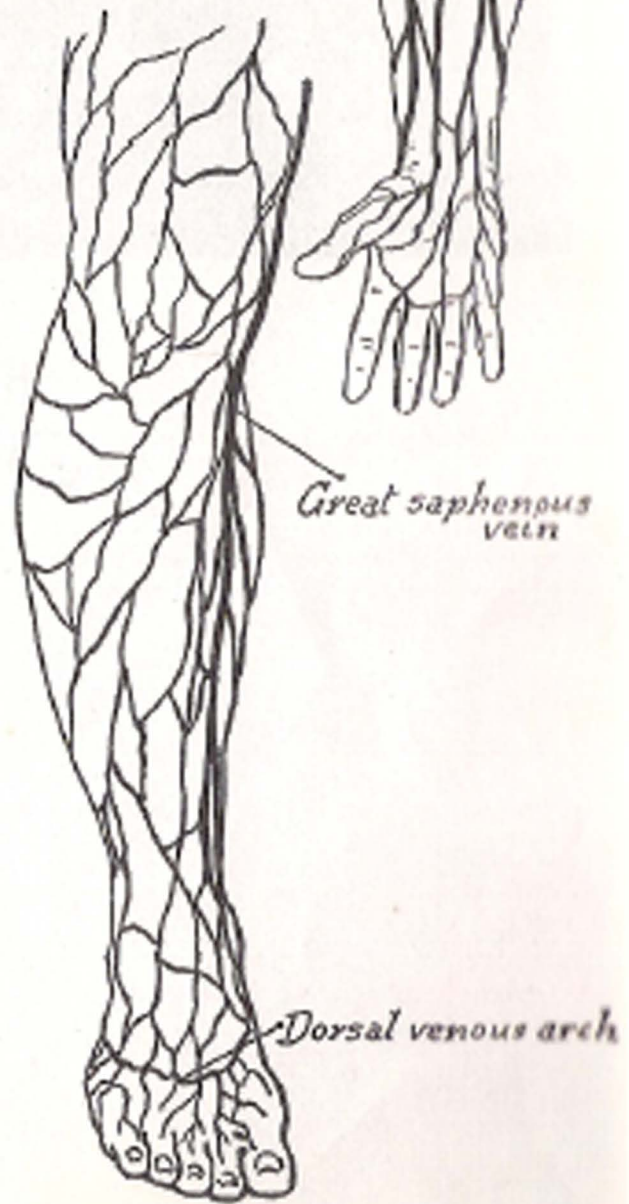
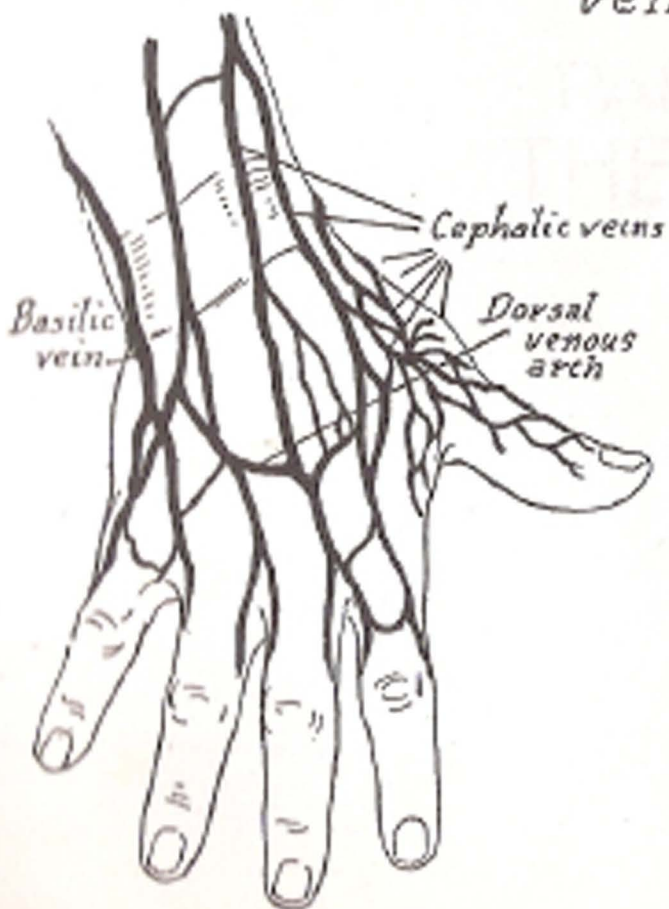


*Types of hands*



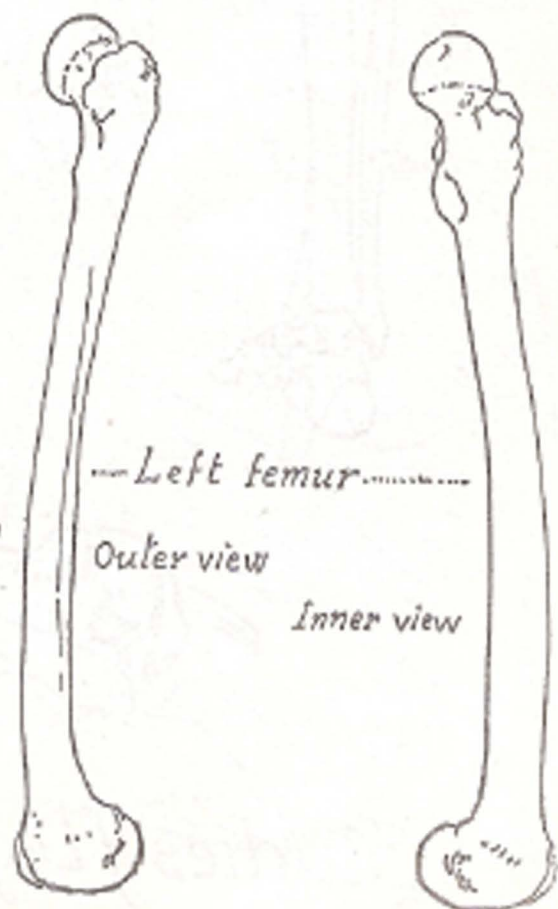
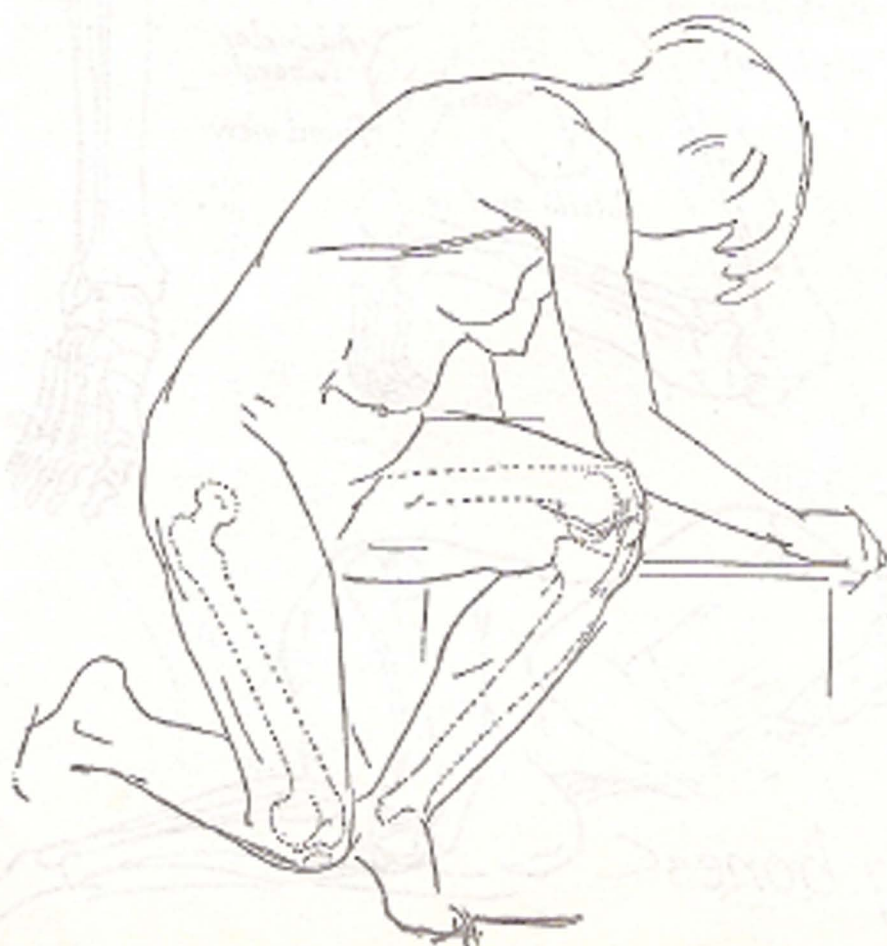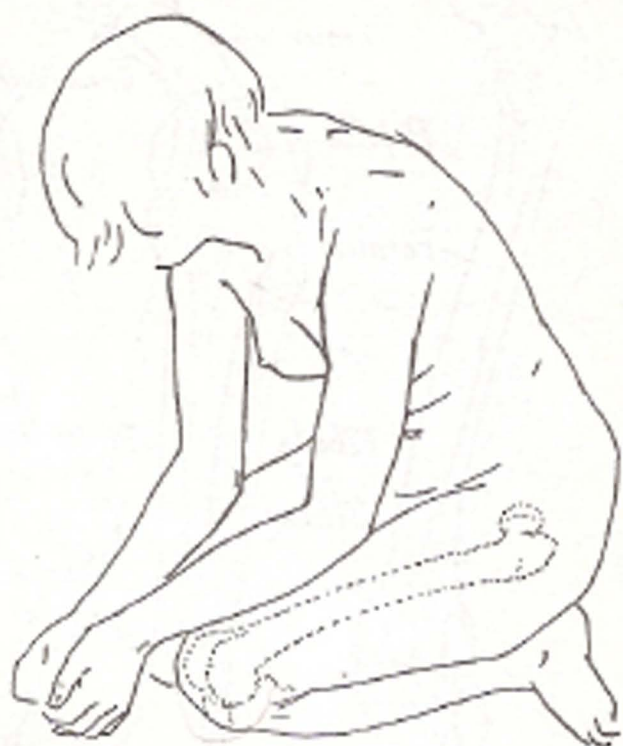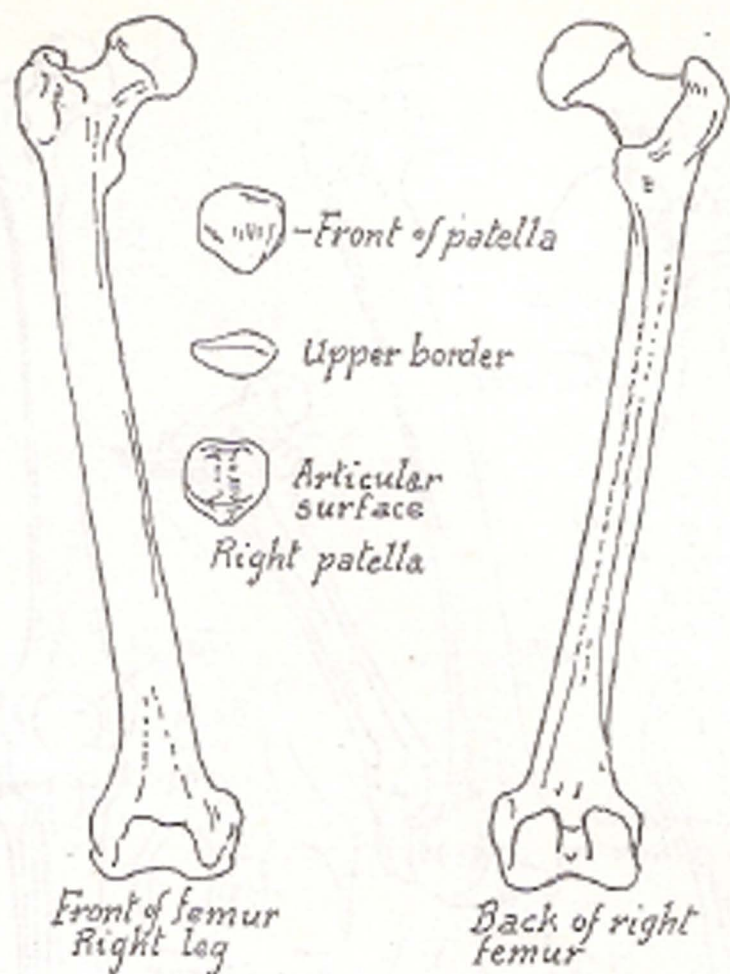


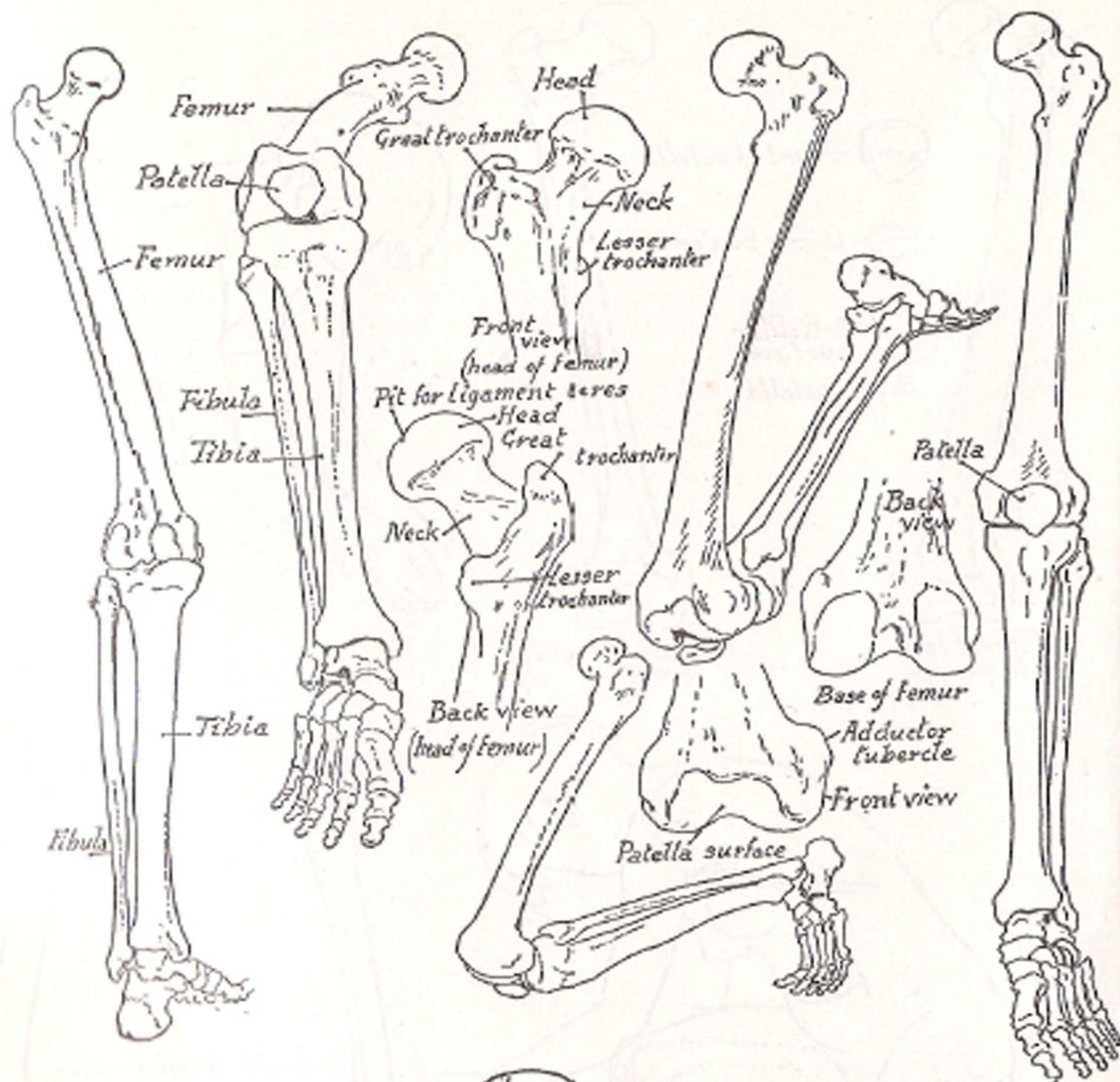
*Superficial veins*



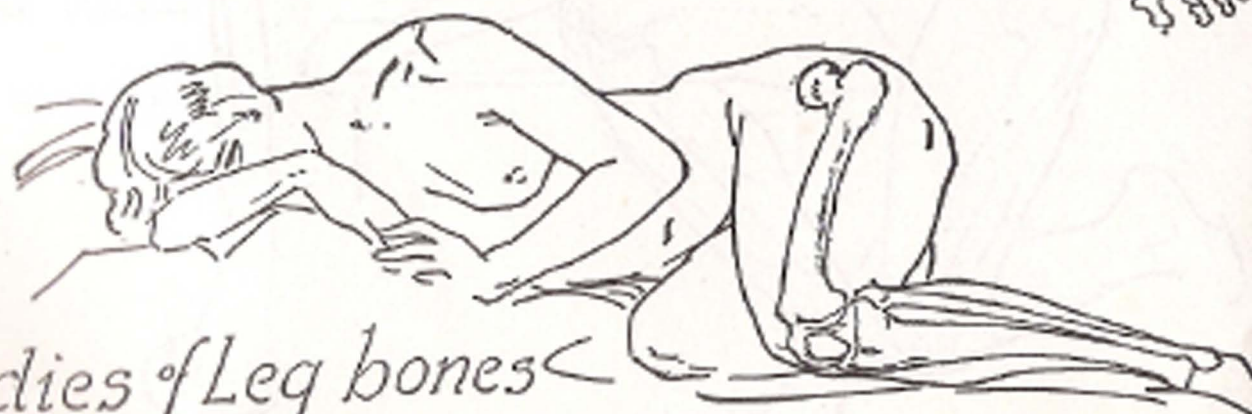


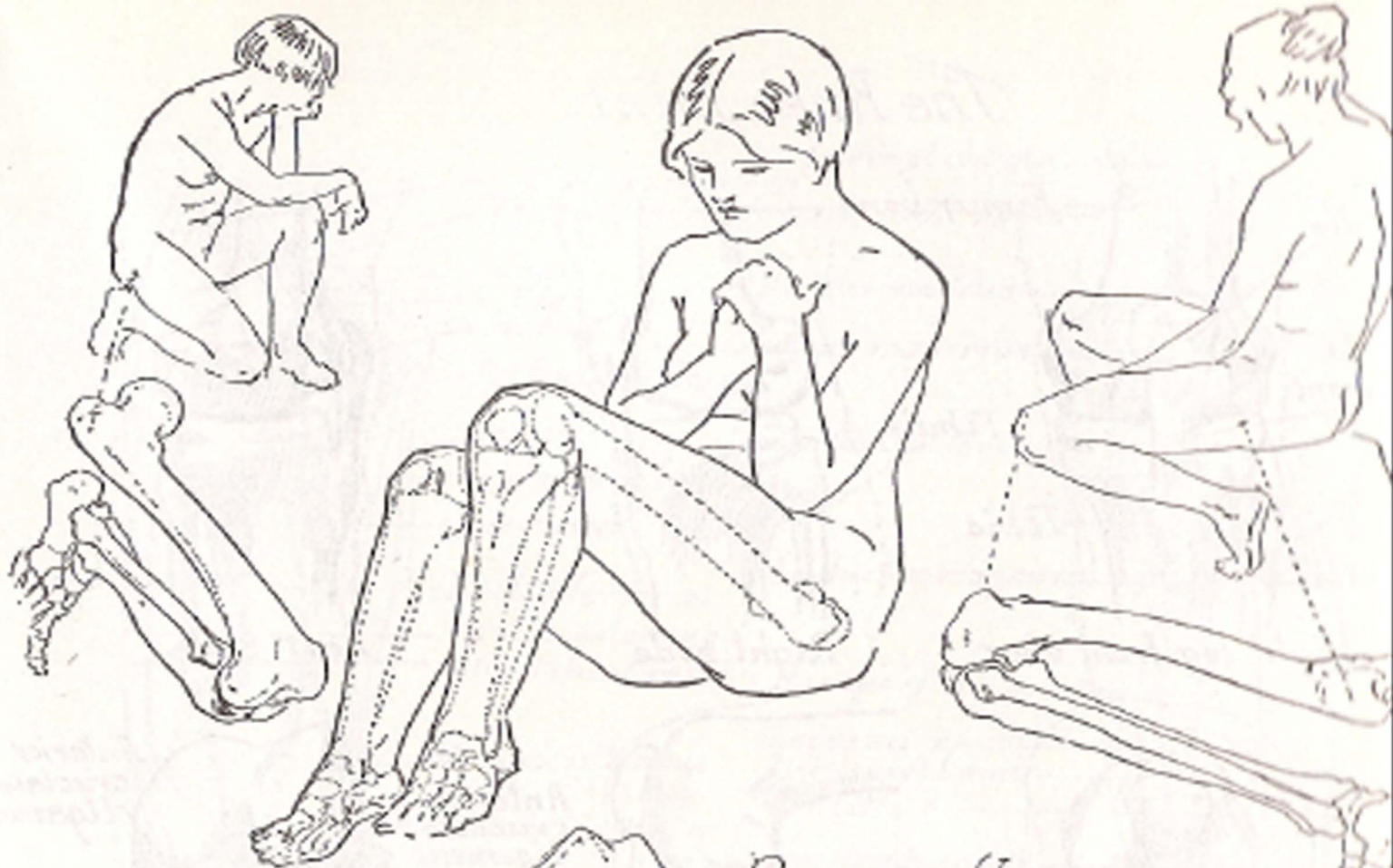
PART VII  
THE LEG



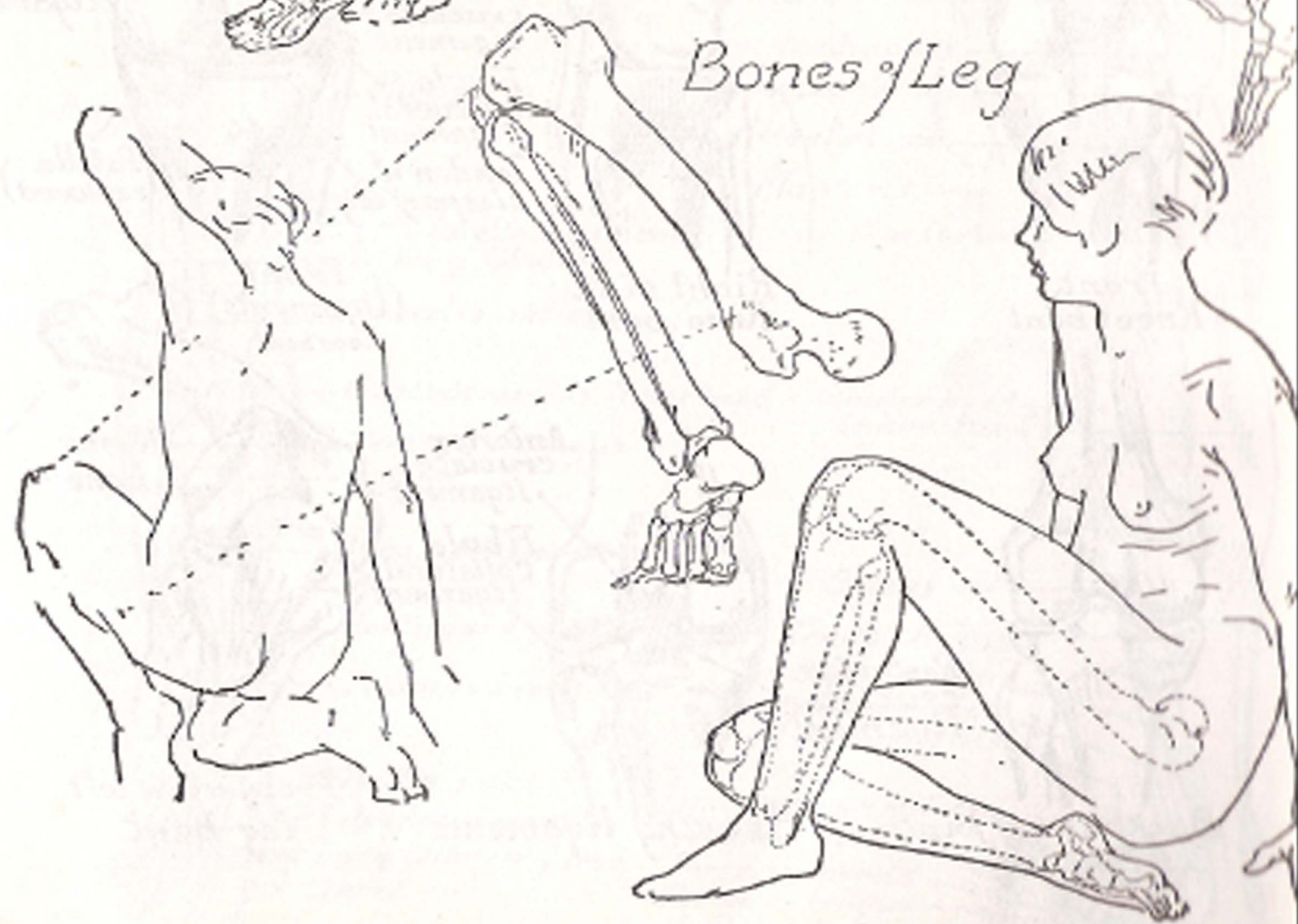


Studies of Leg bones

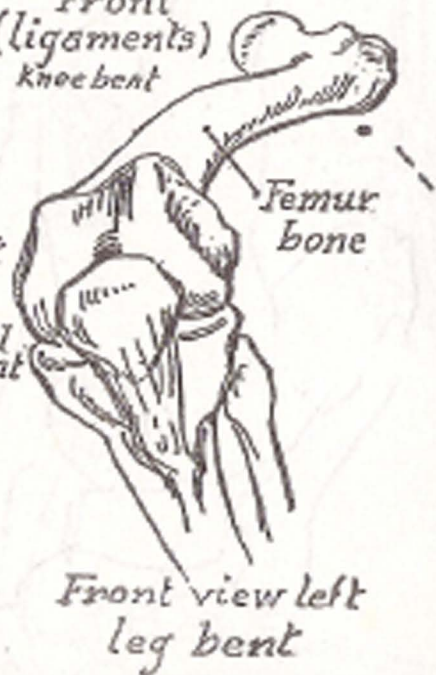
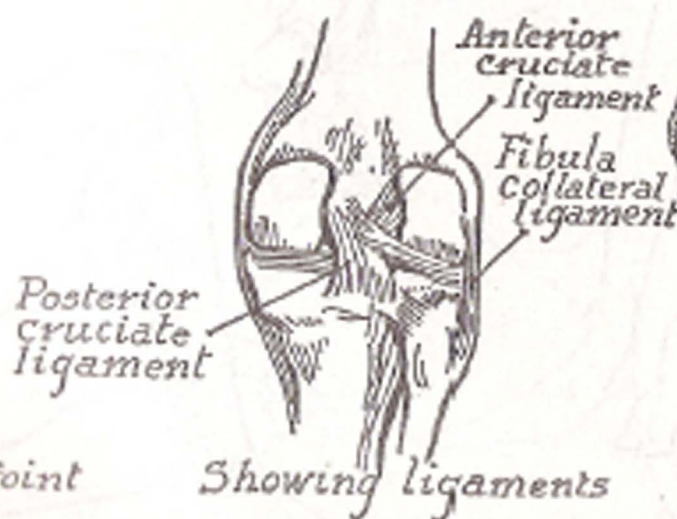
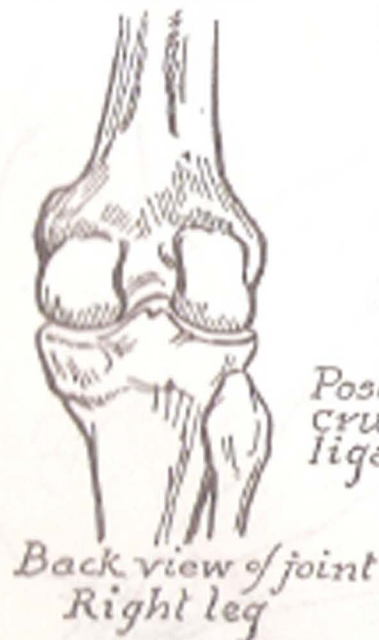
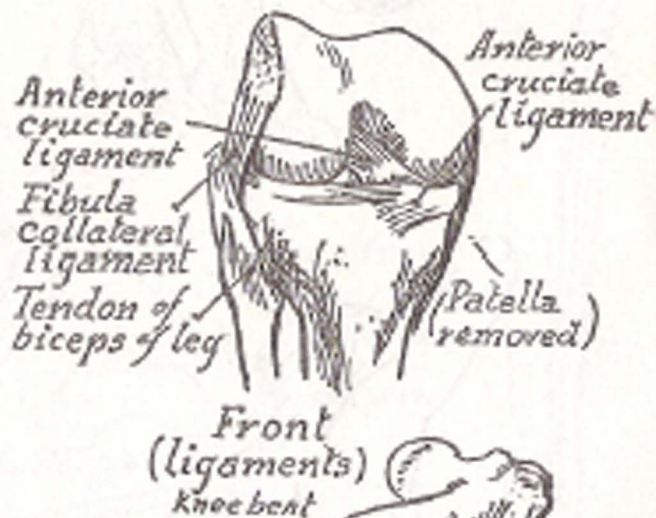
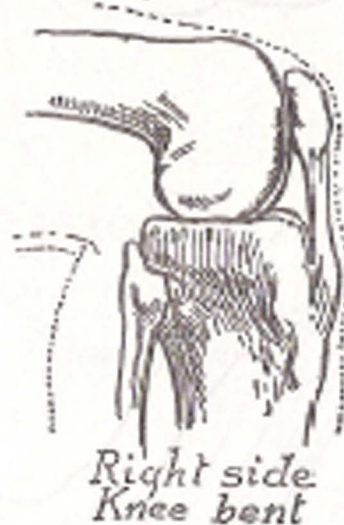
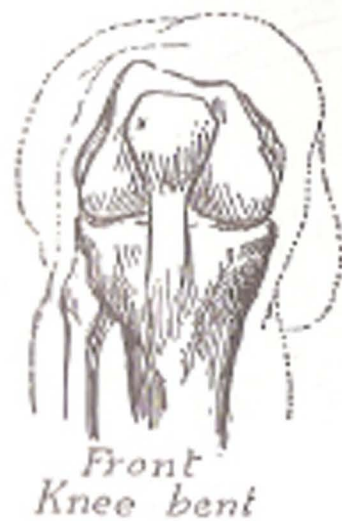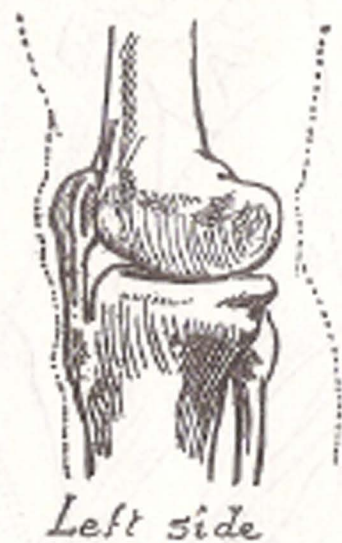
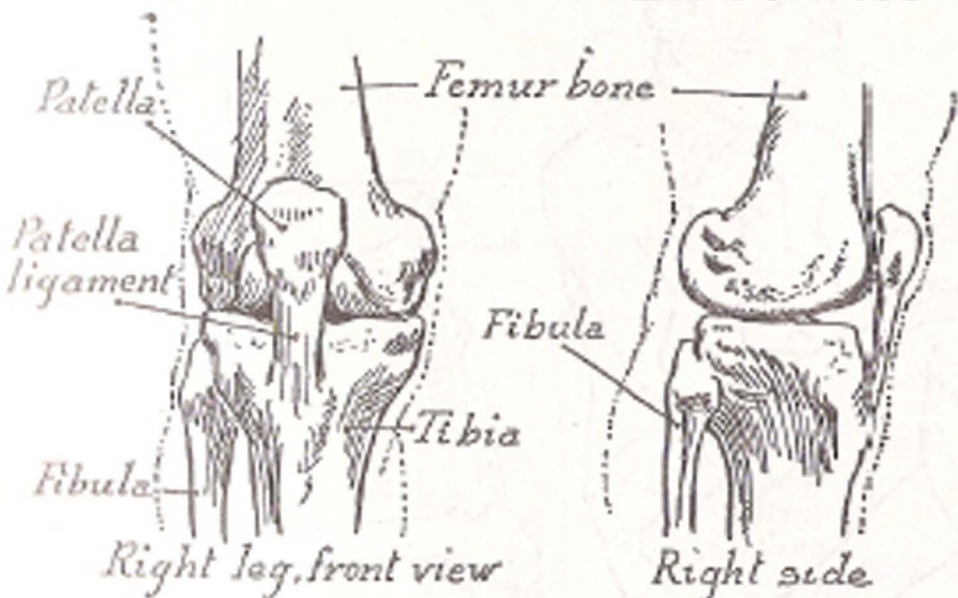




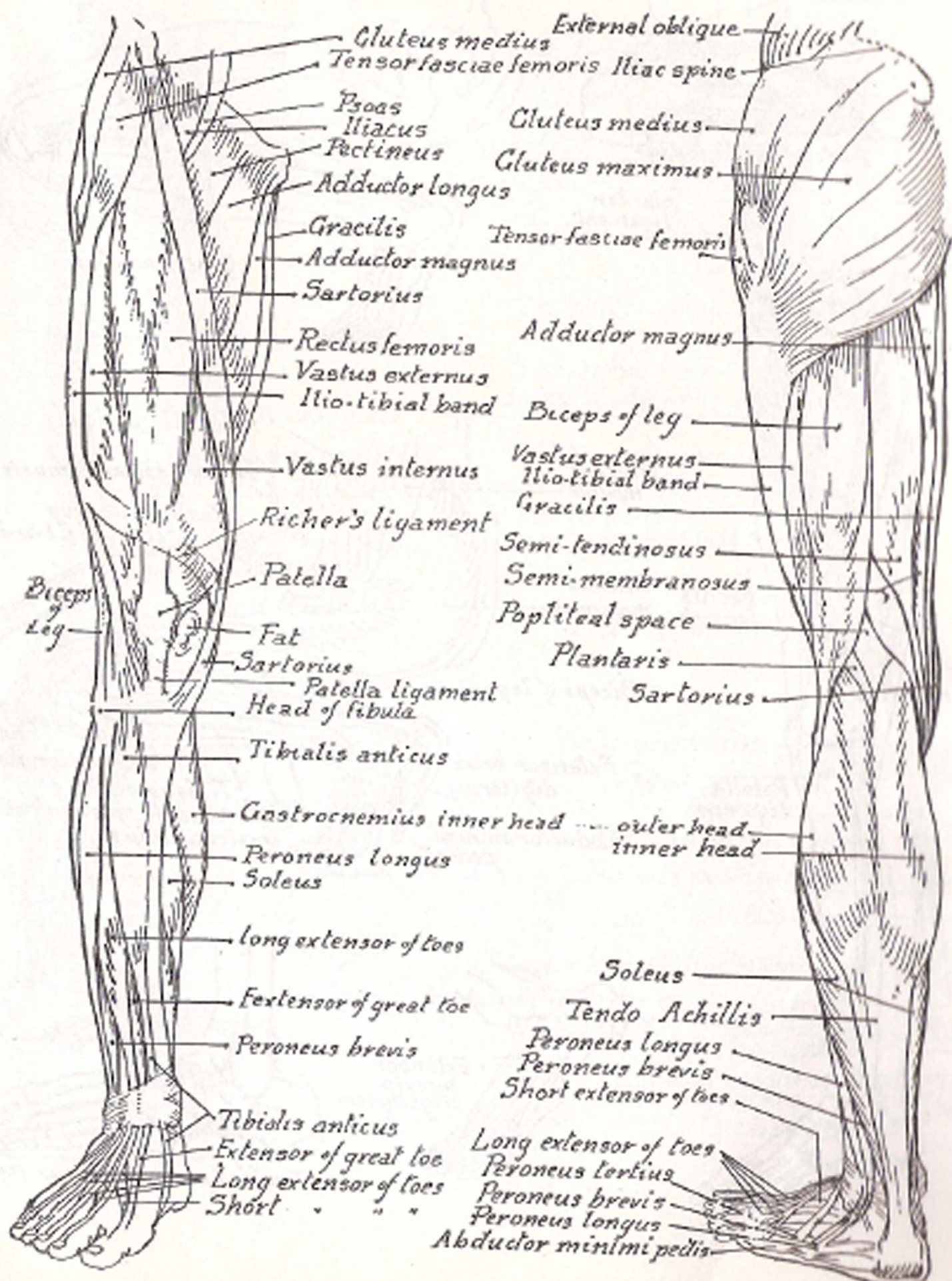
*Bones of Leg*

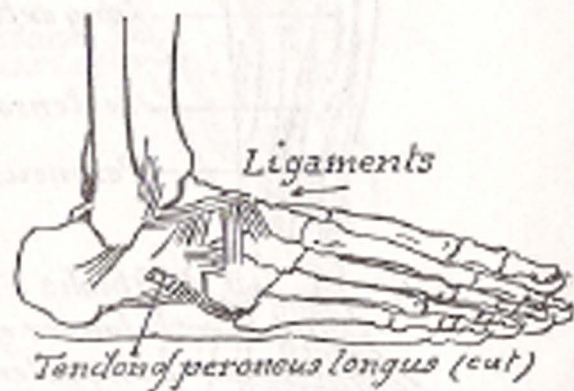
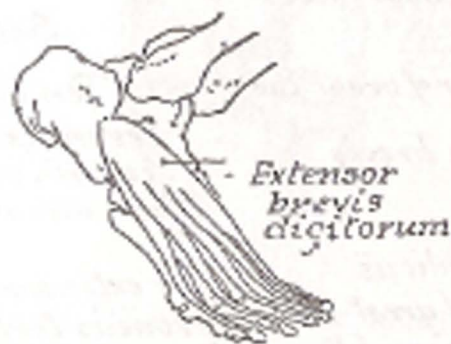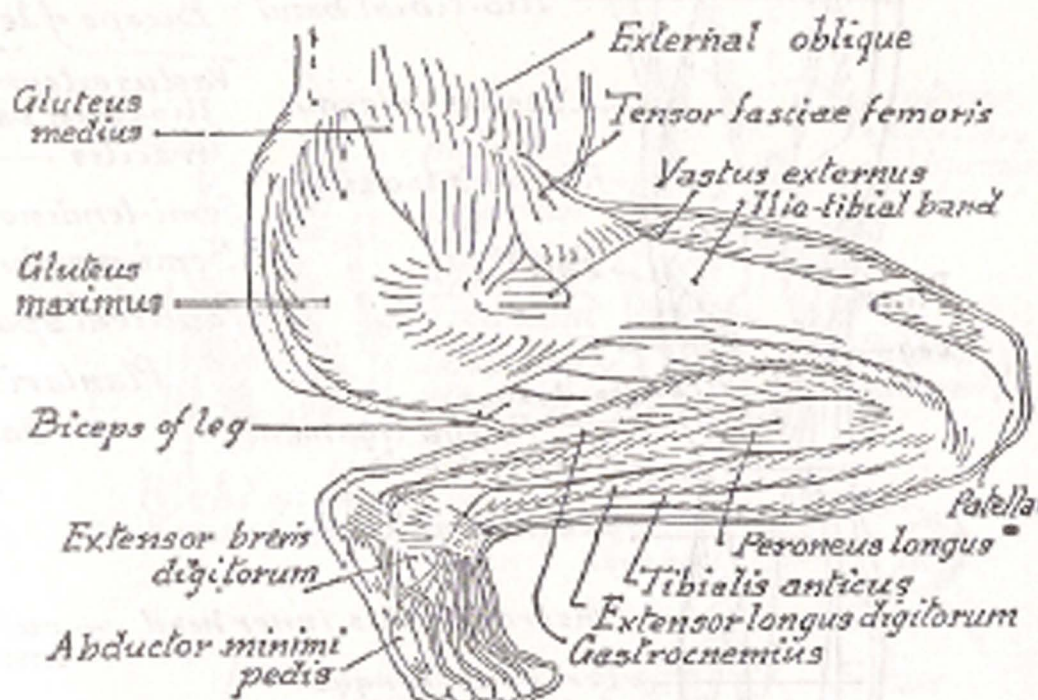
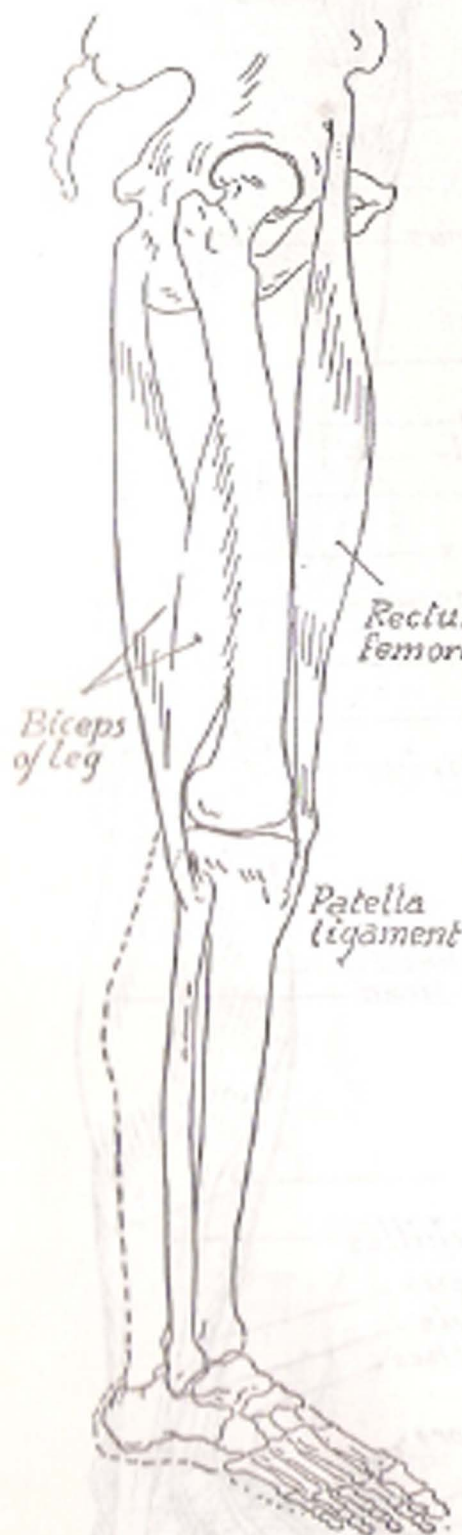
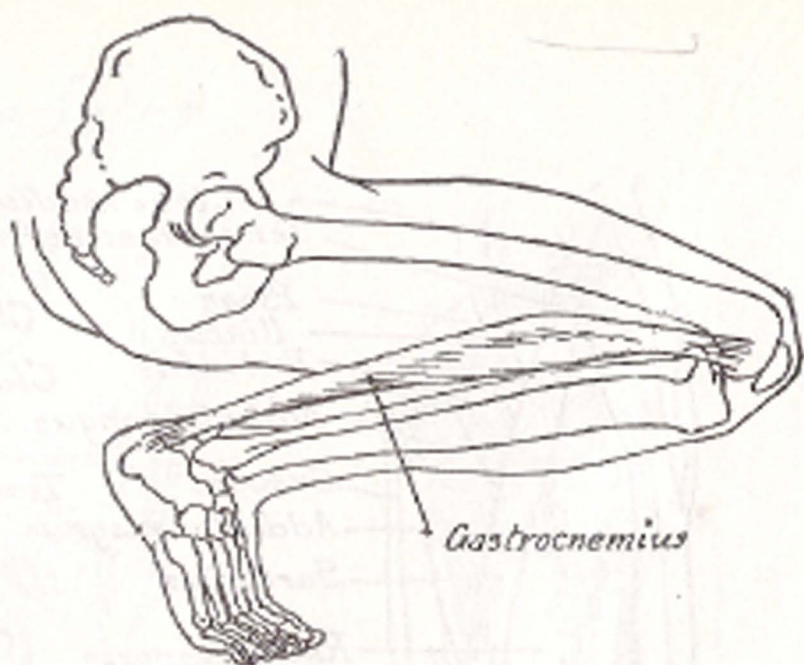
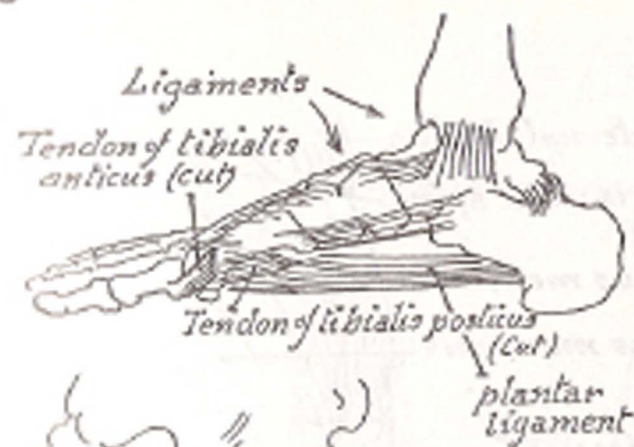


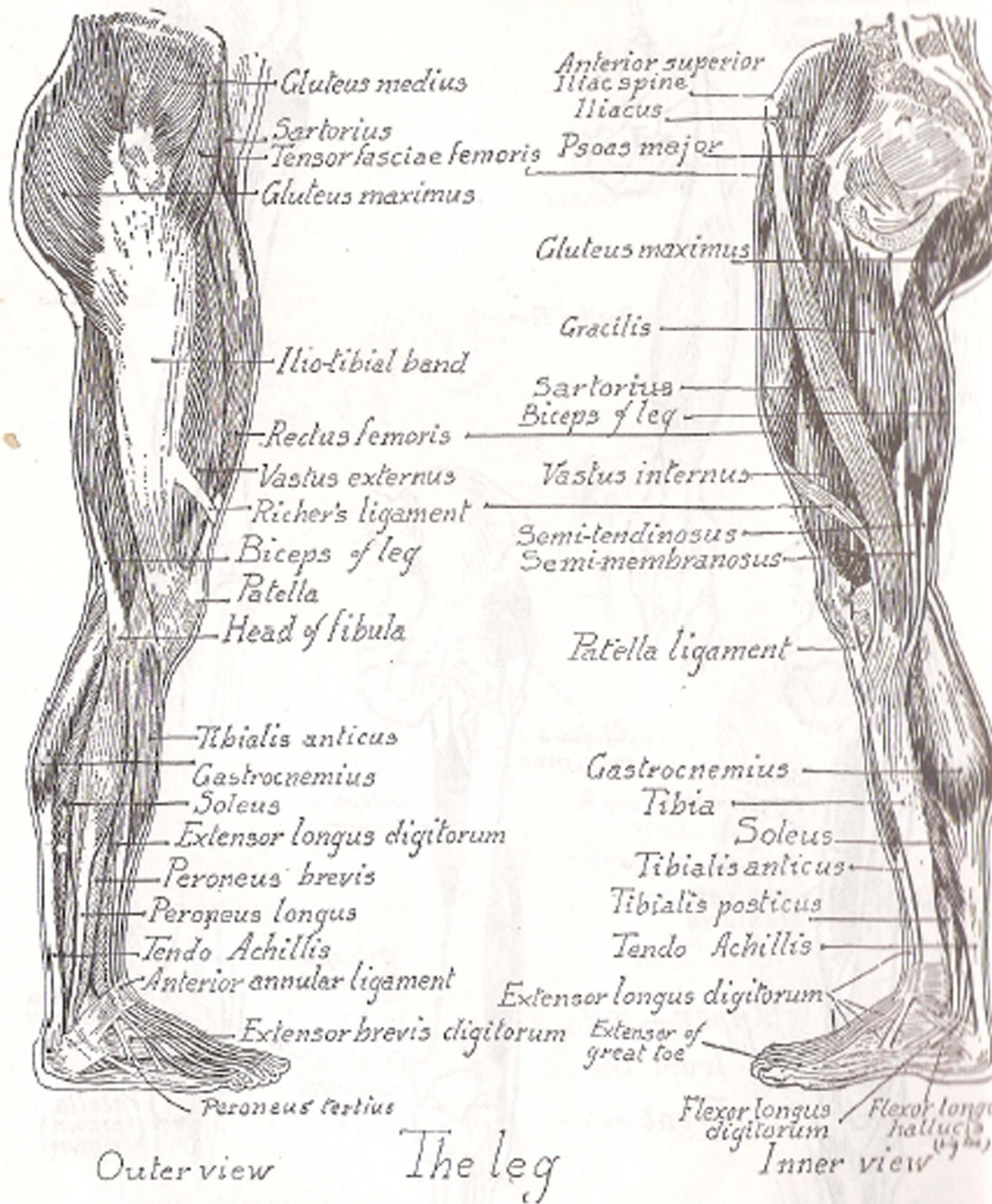
# The Knee Joint

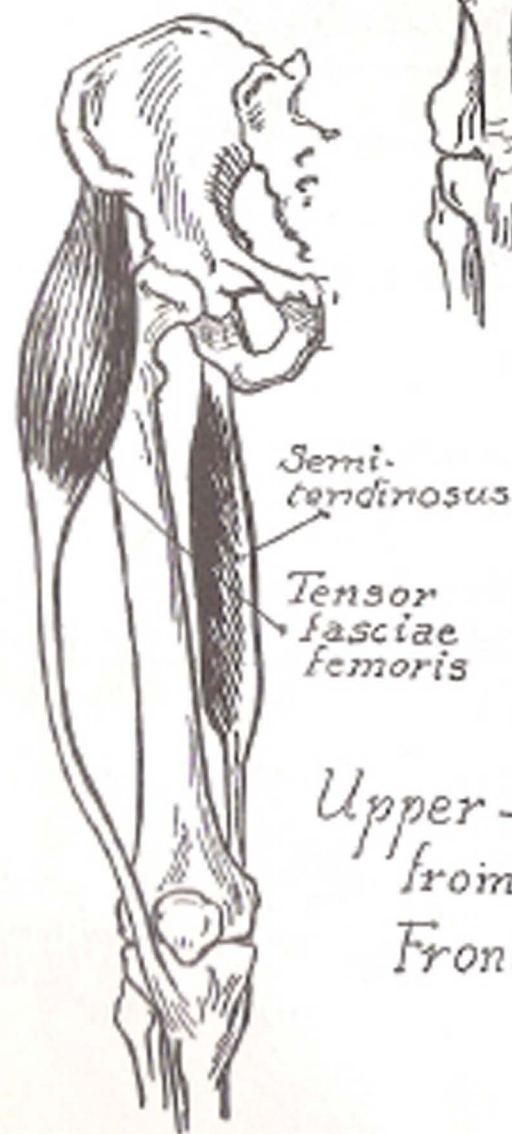
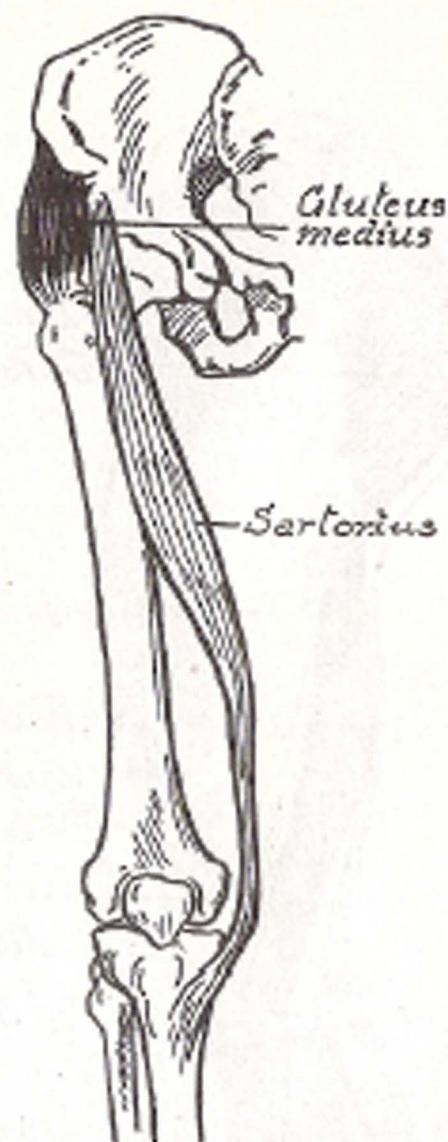
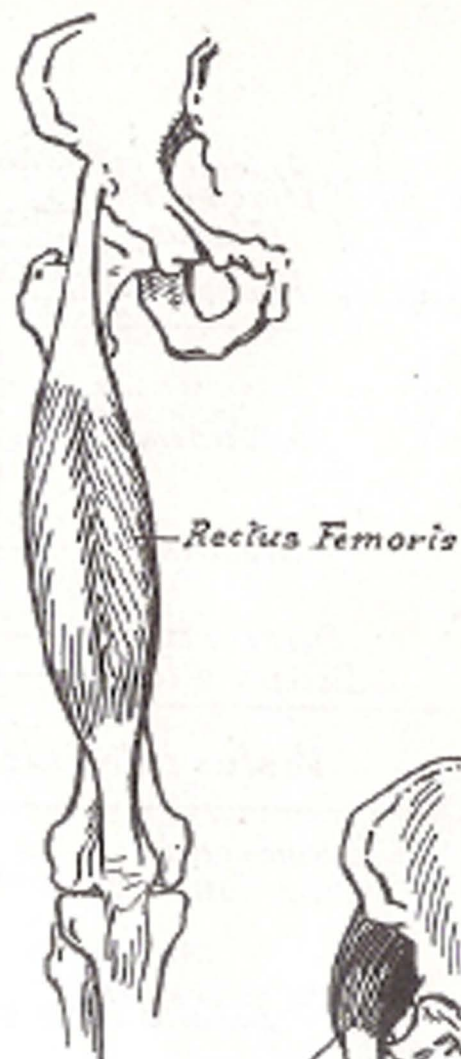
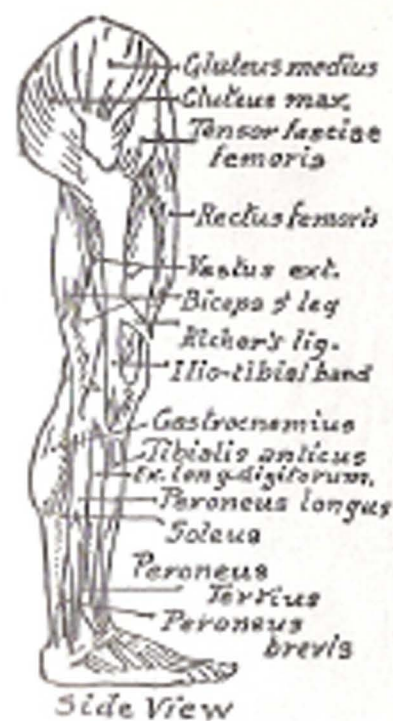



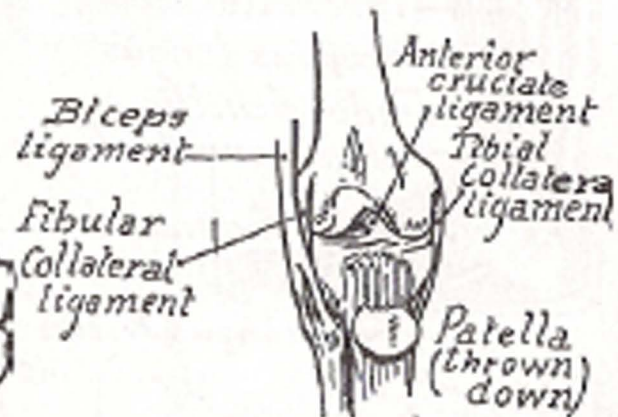
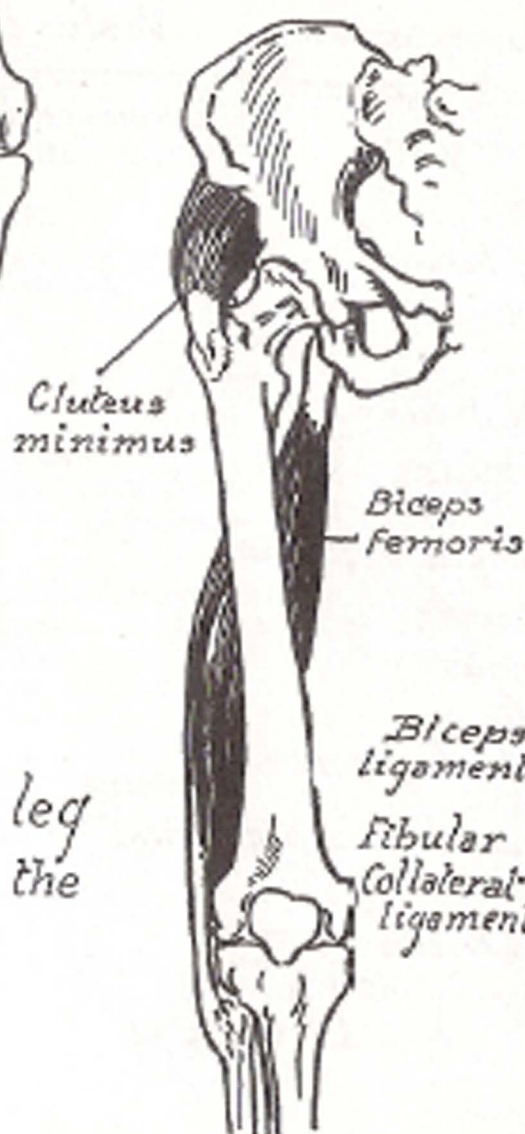


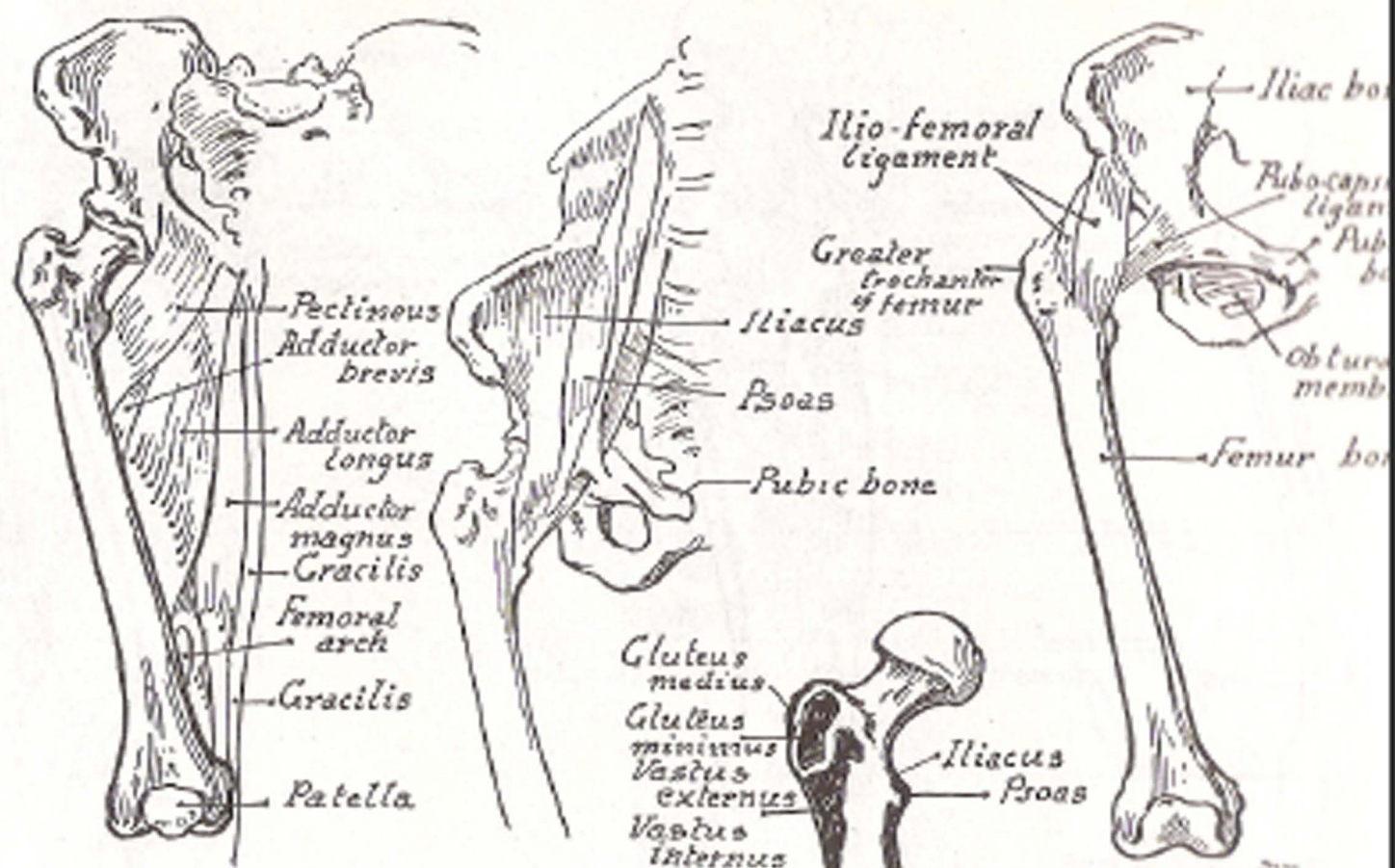




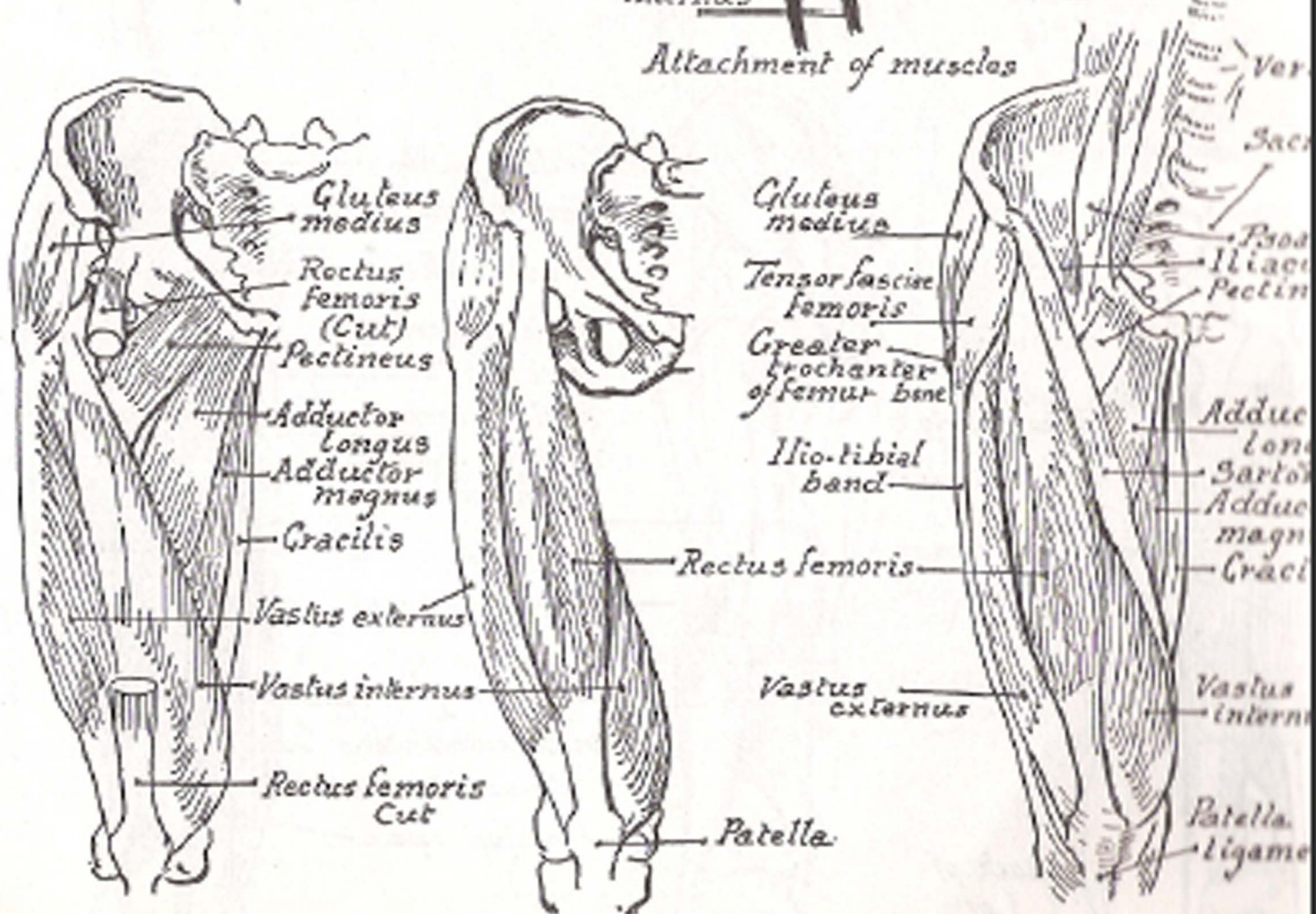


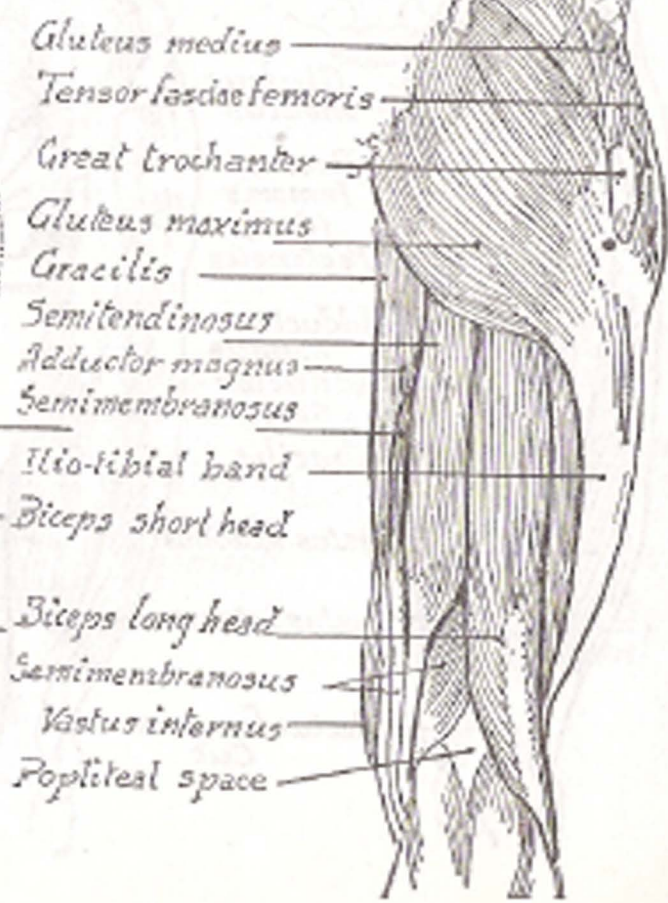
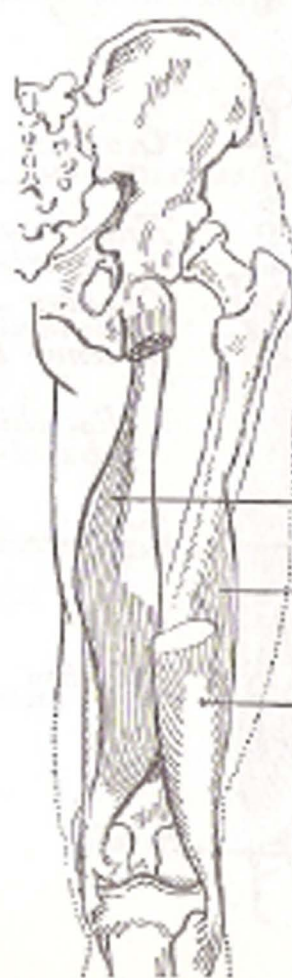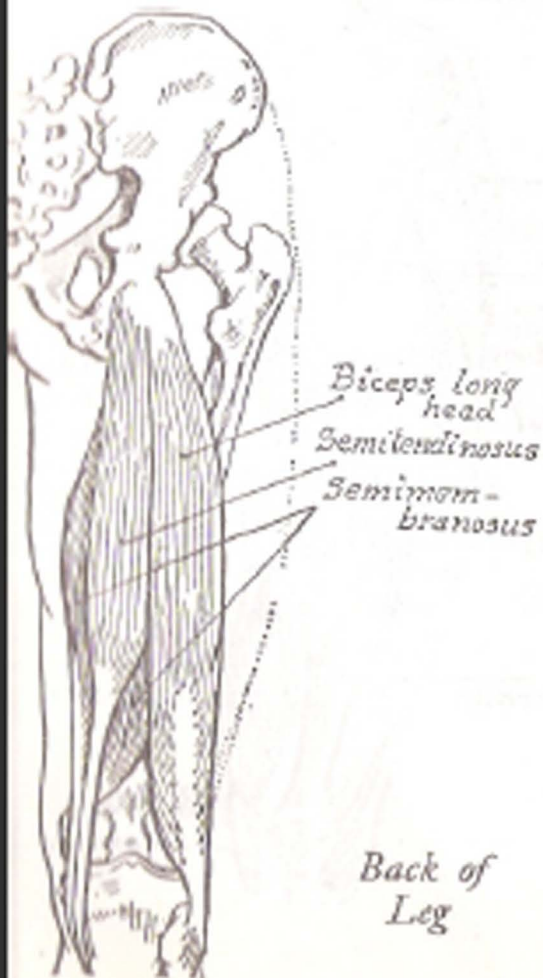
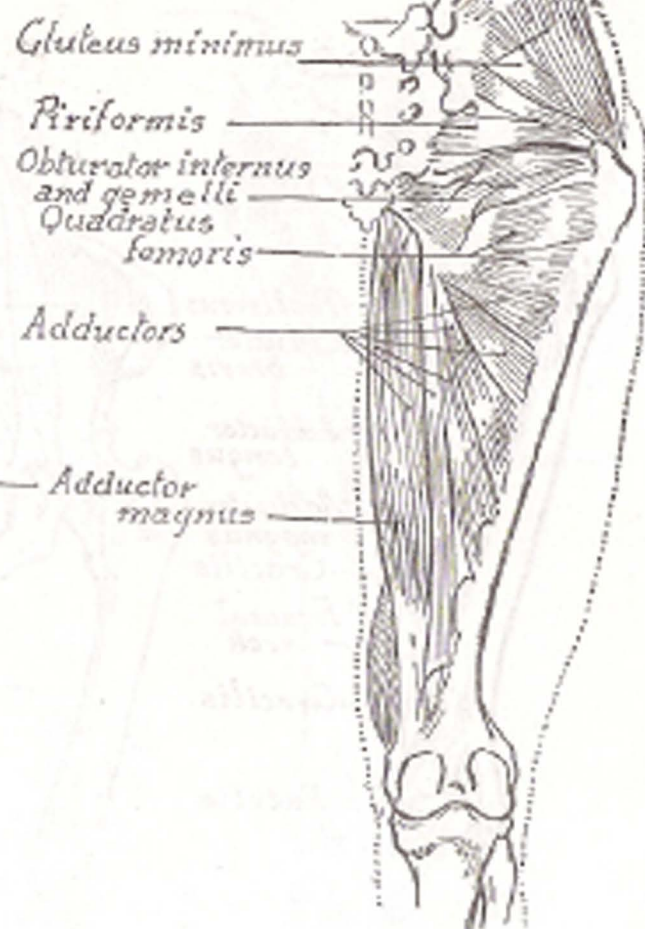
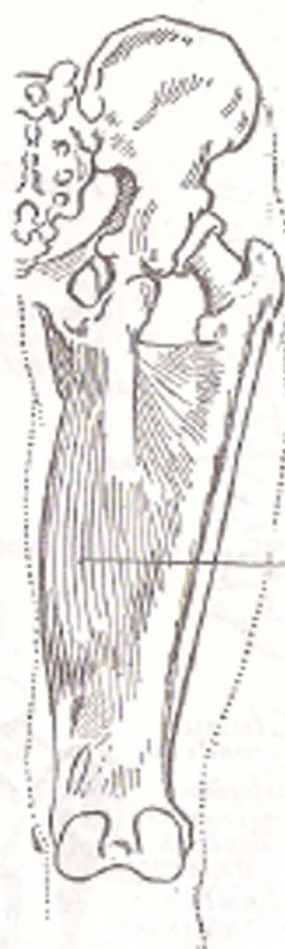
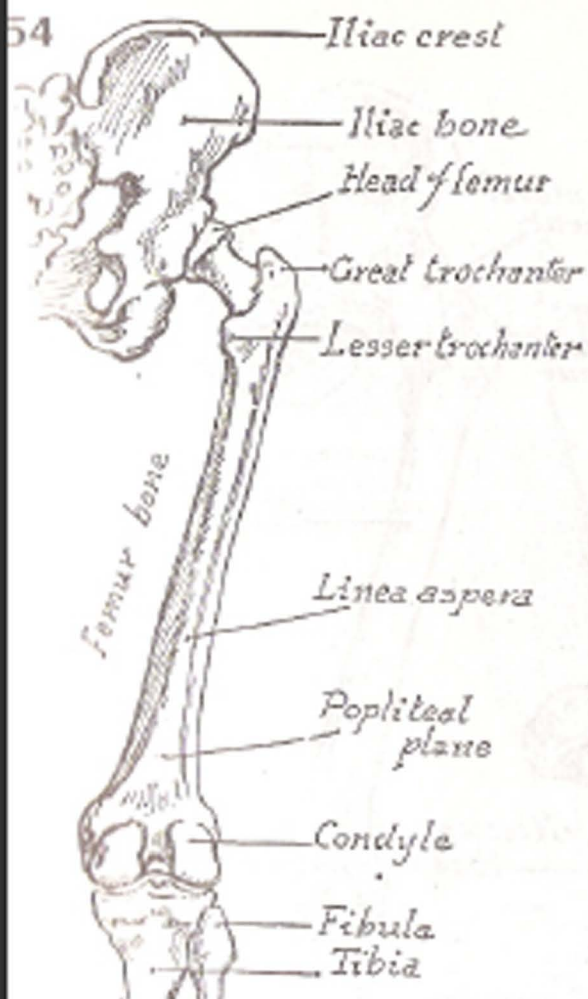
Upper-leg  
from the  
Front

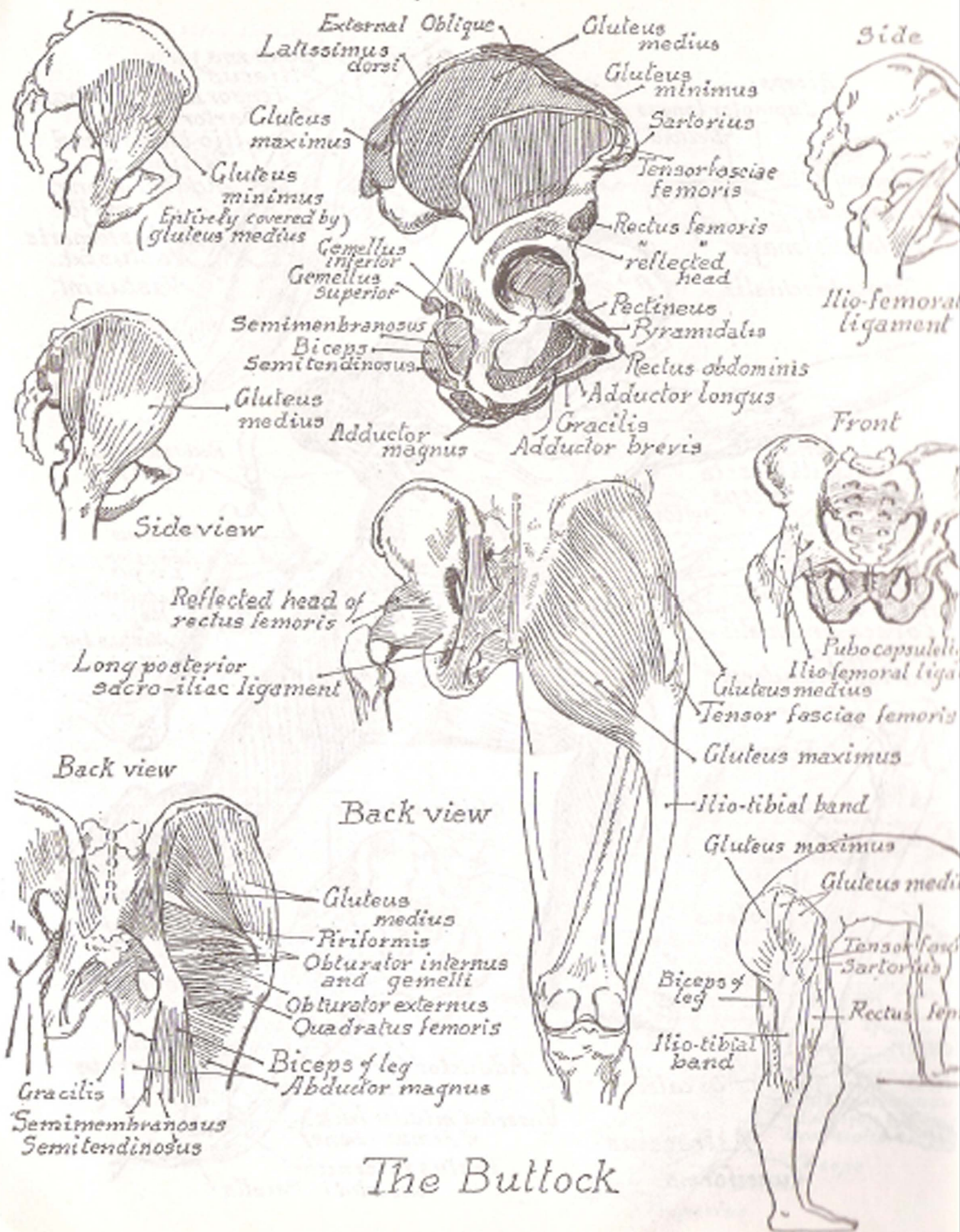


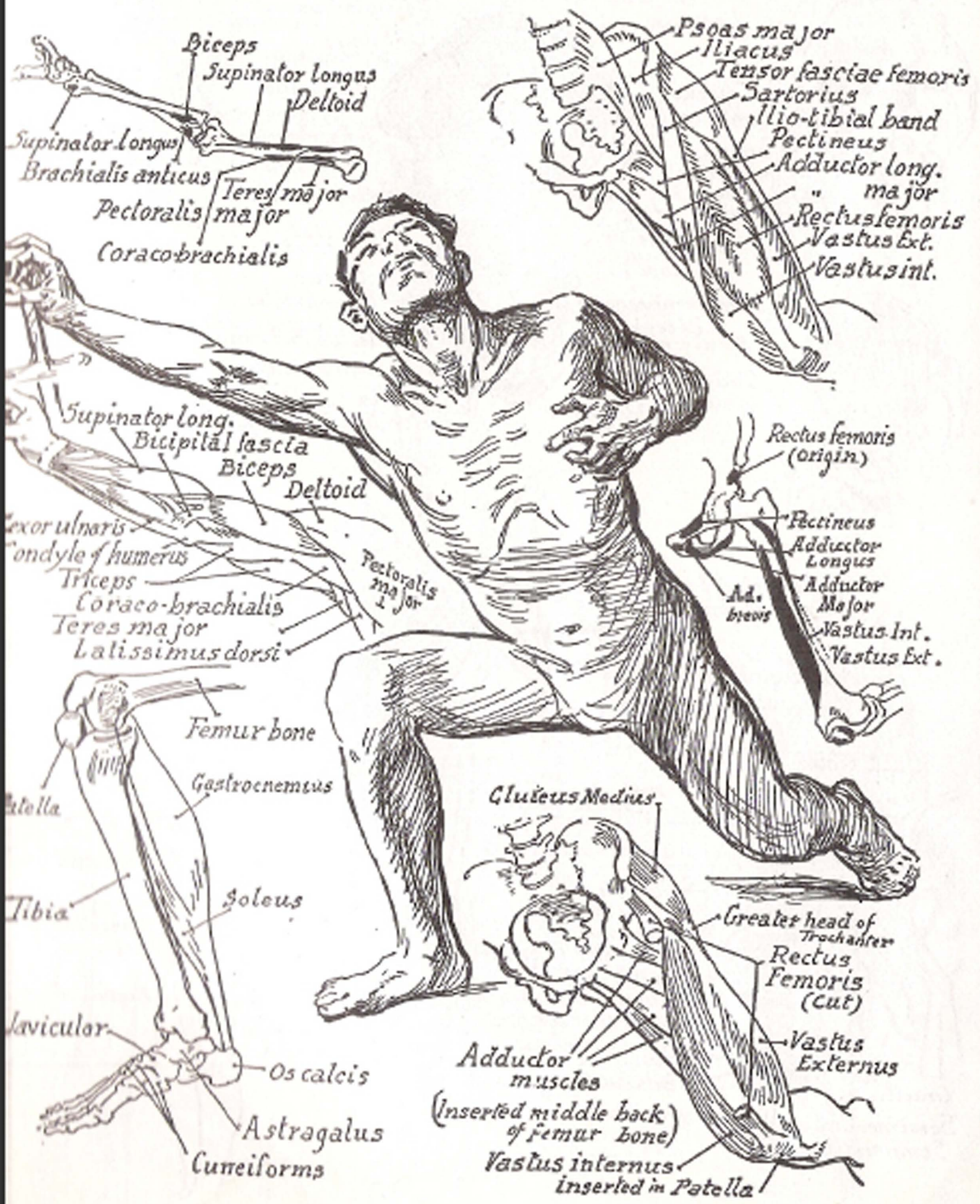

Attachment of muscles

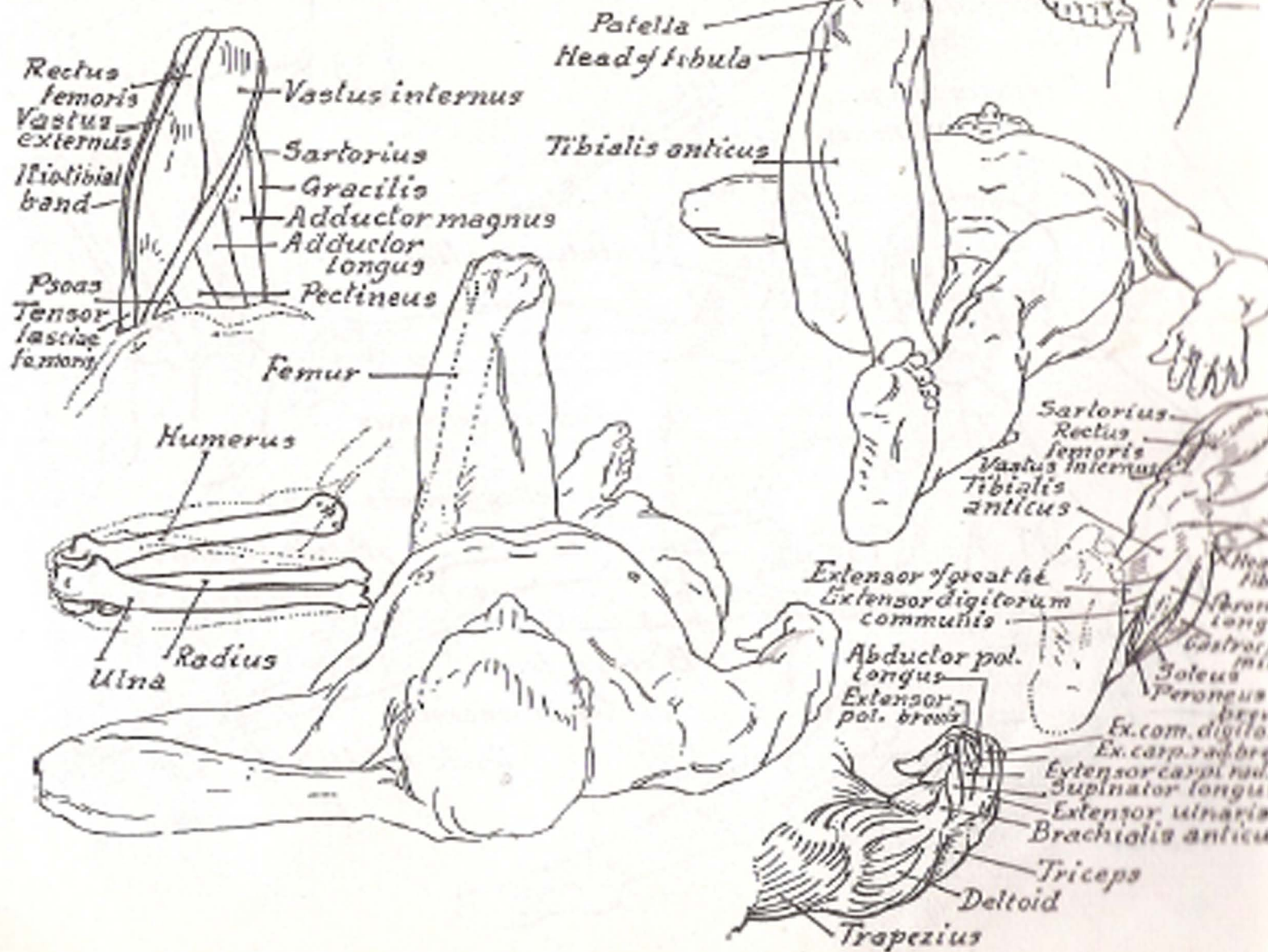
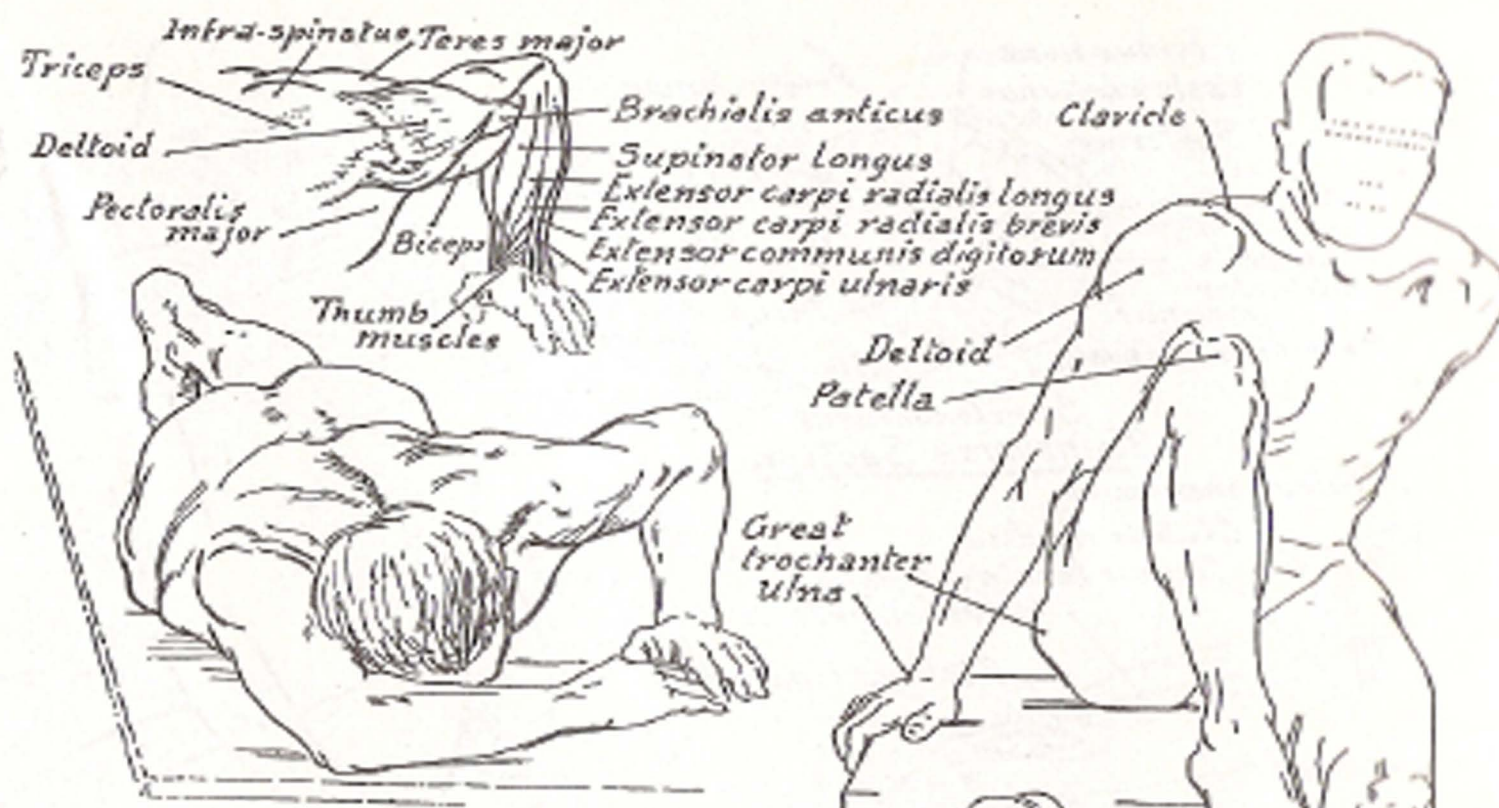


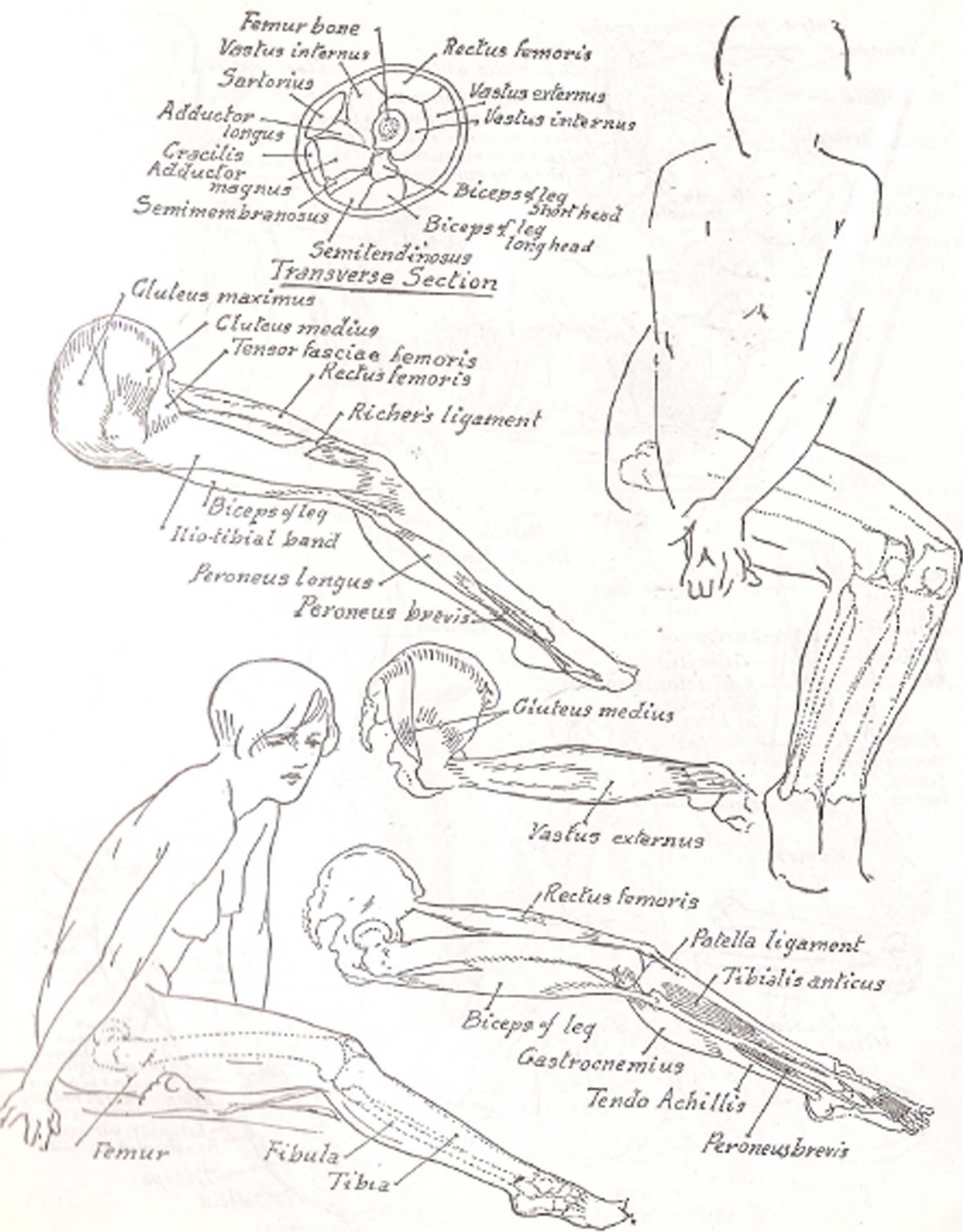


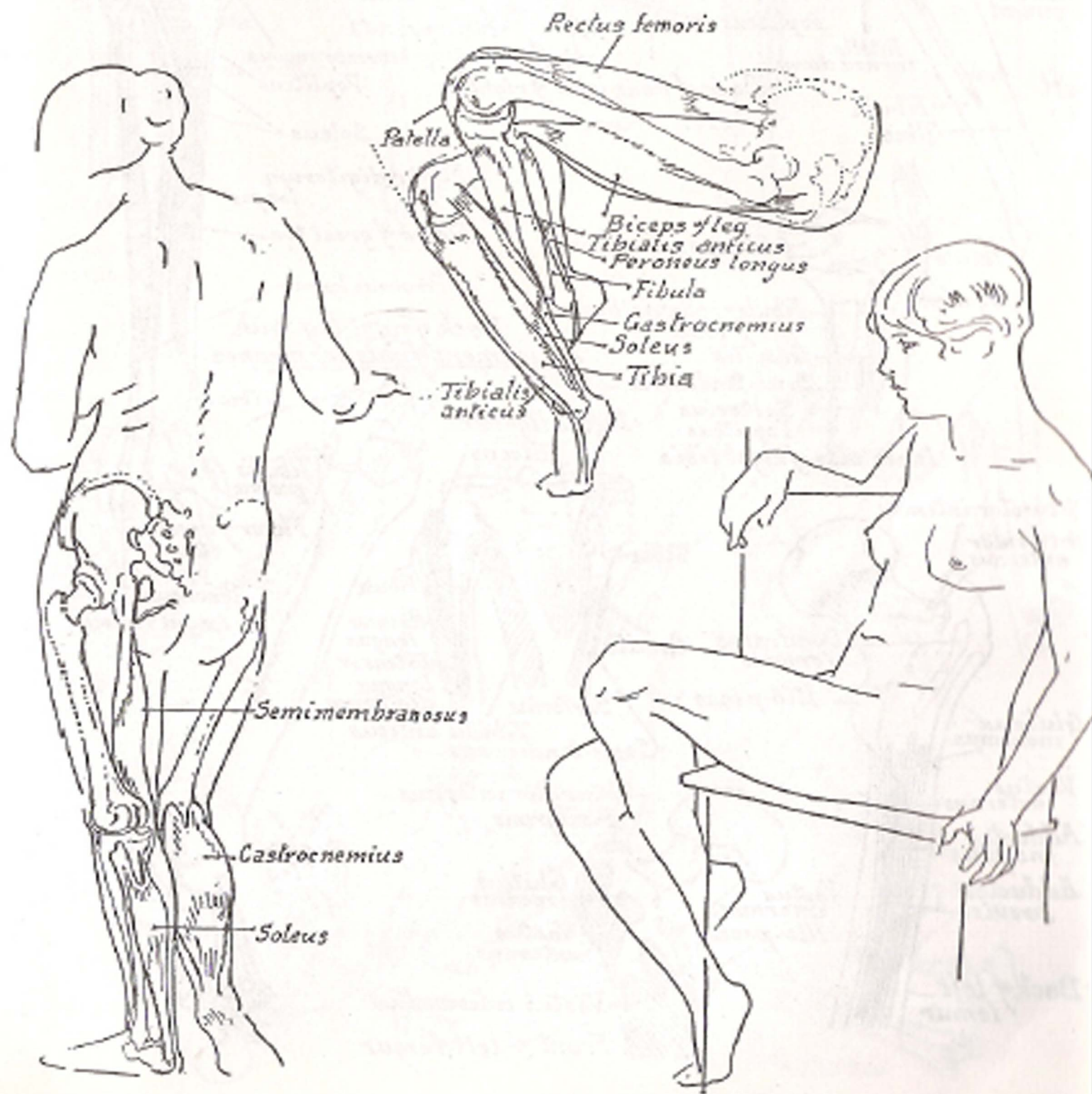
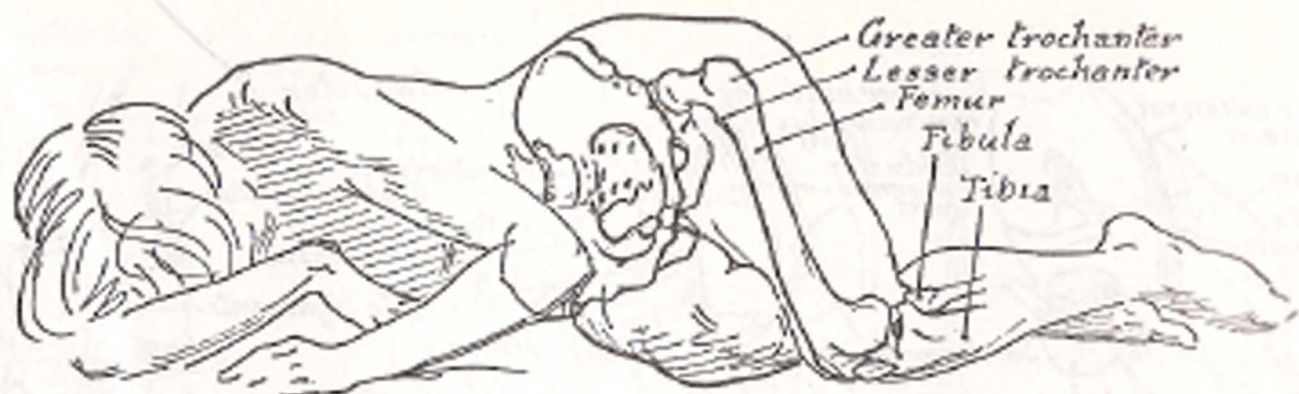


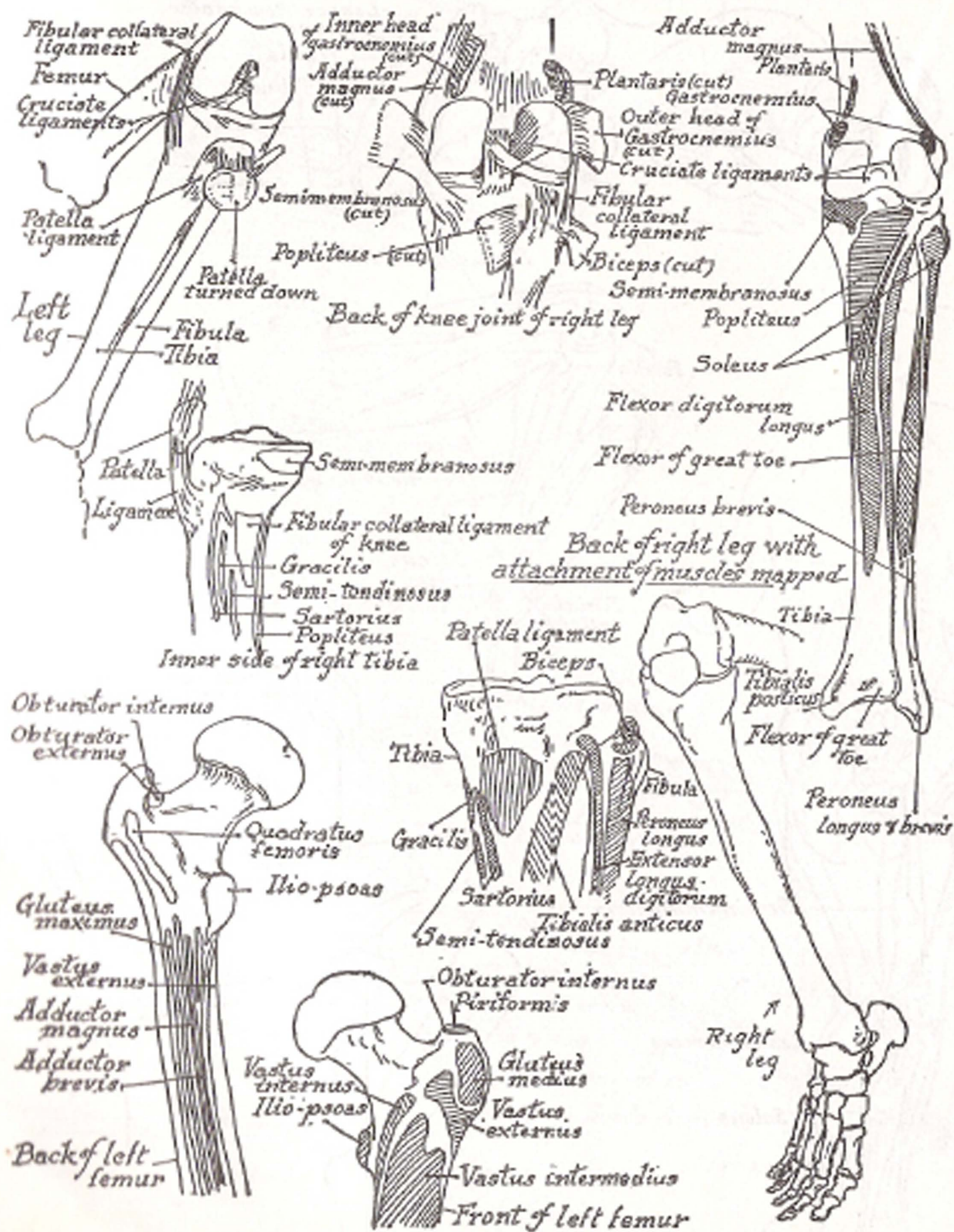


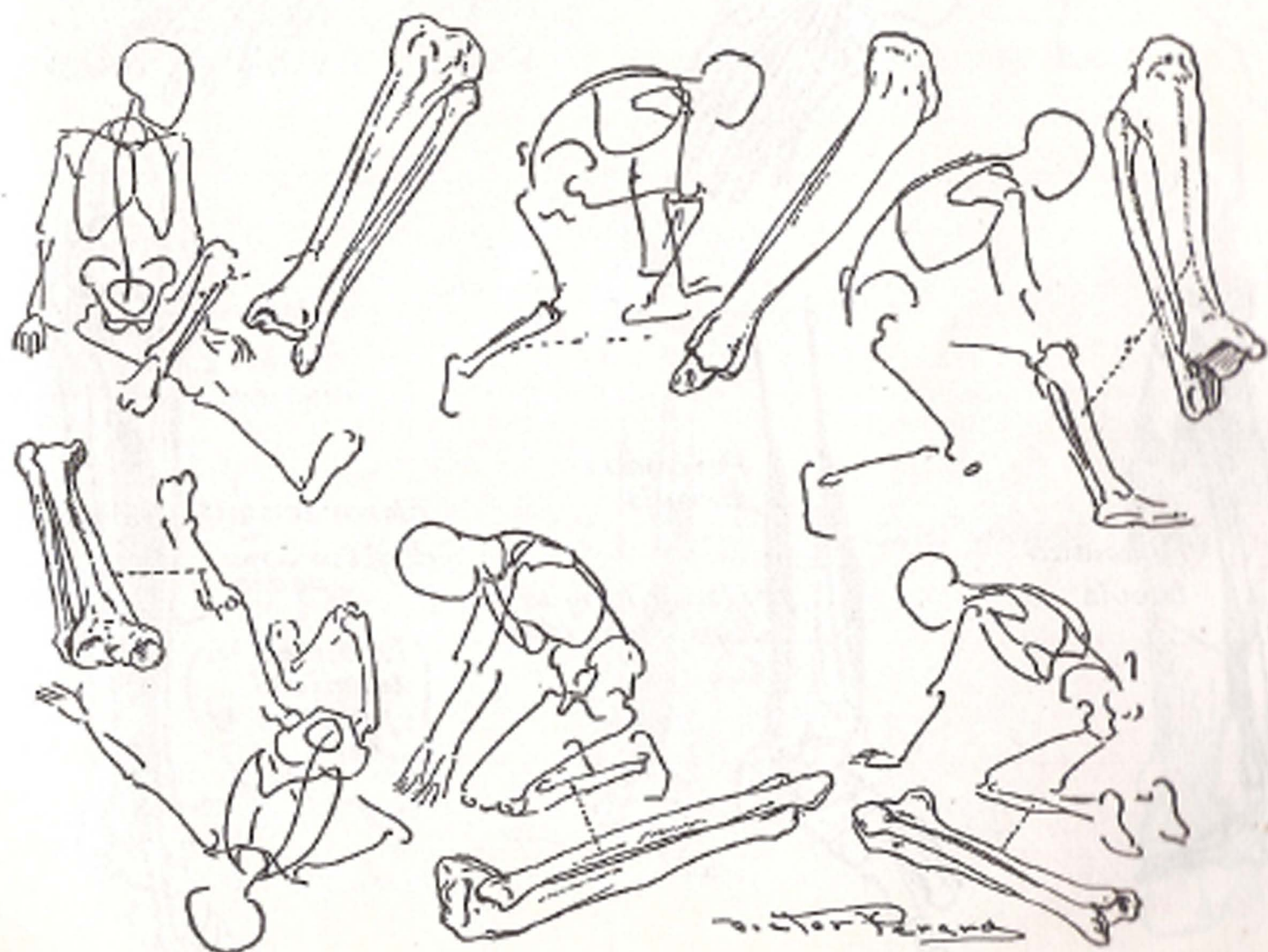
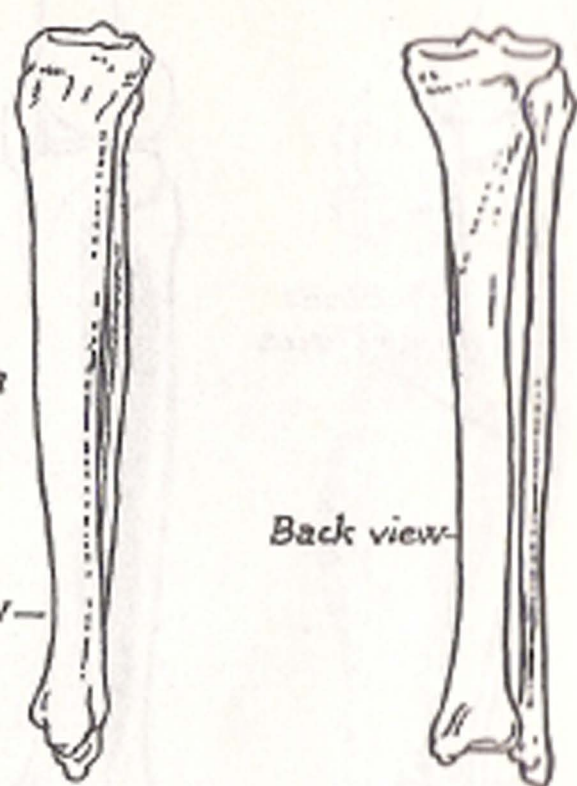
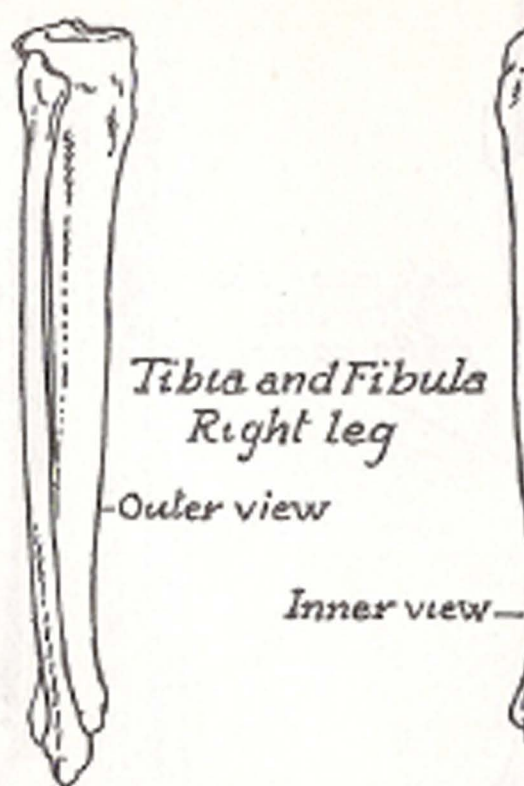
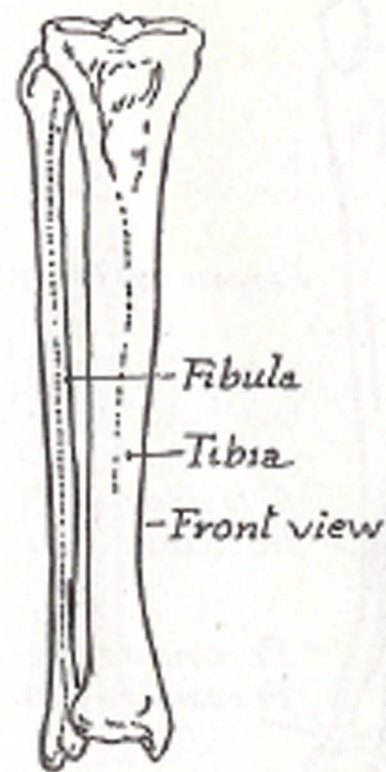


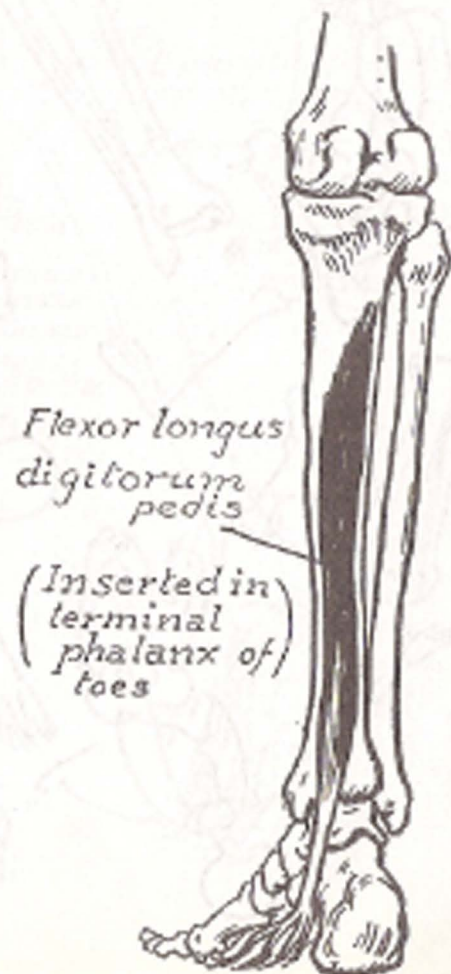
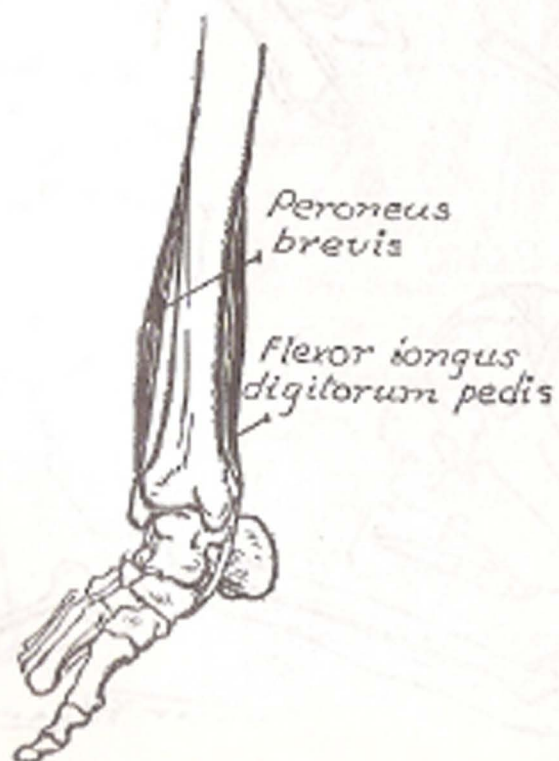
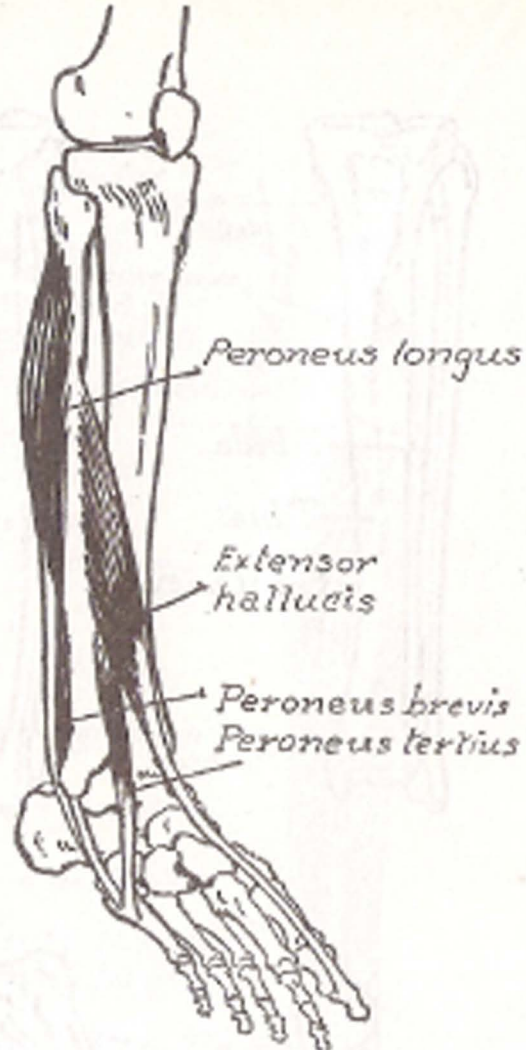
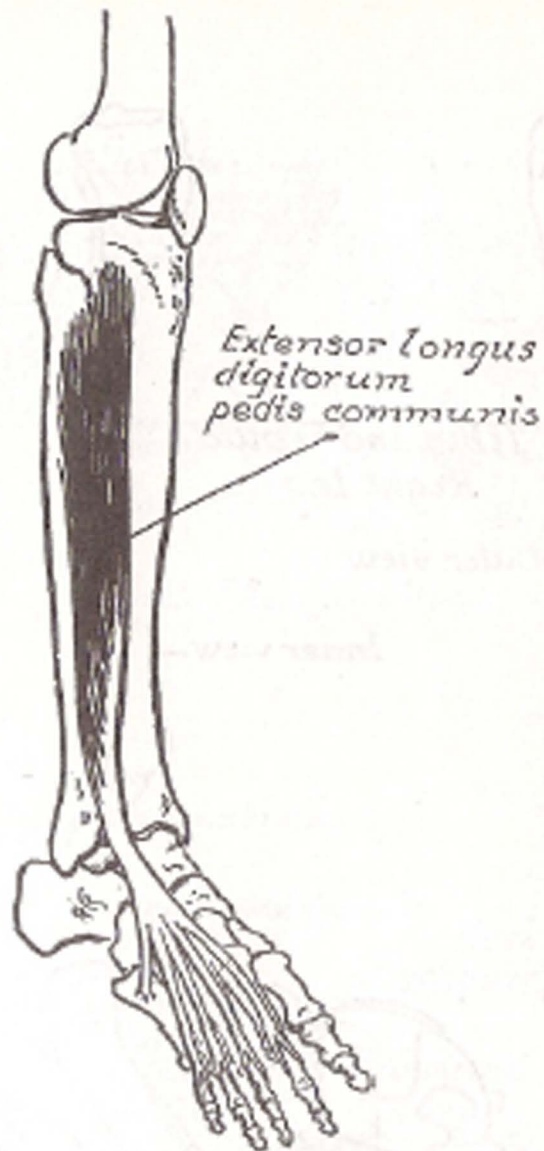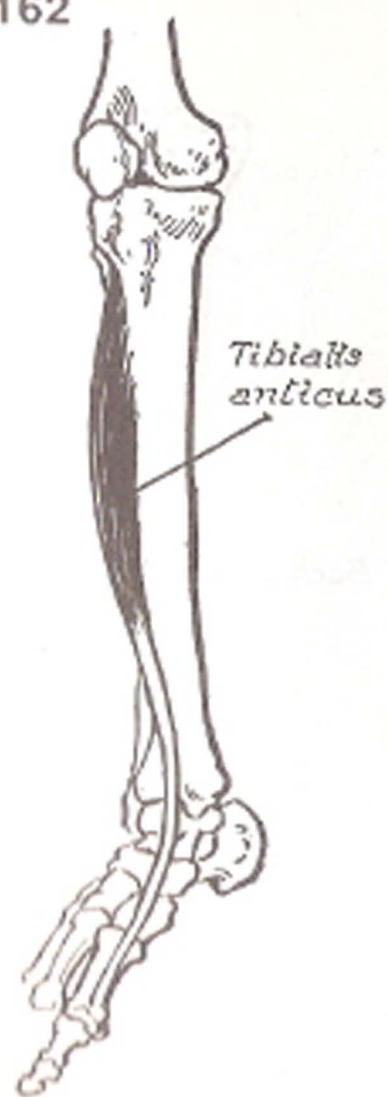


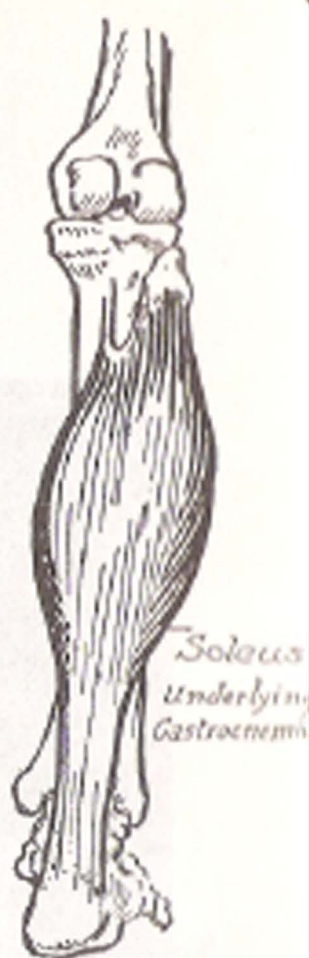
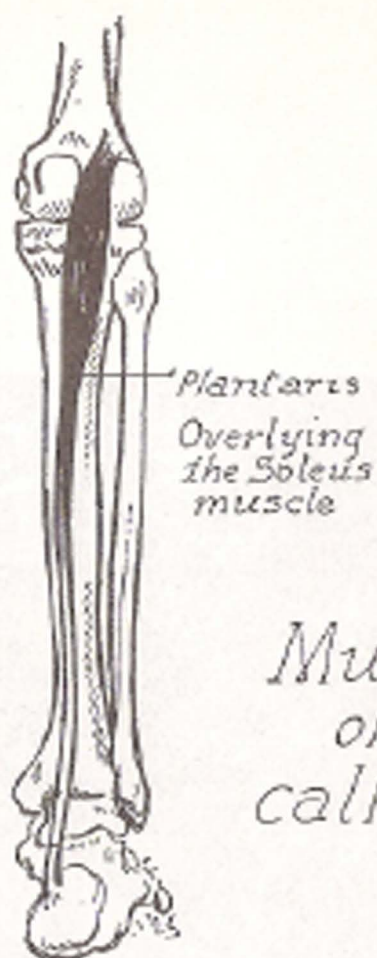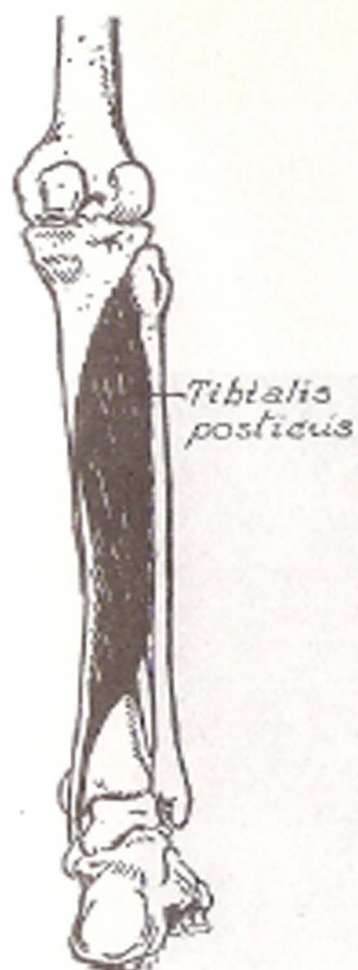




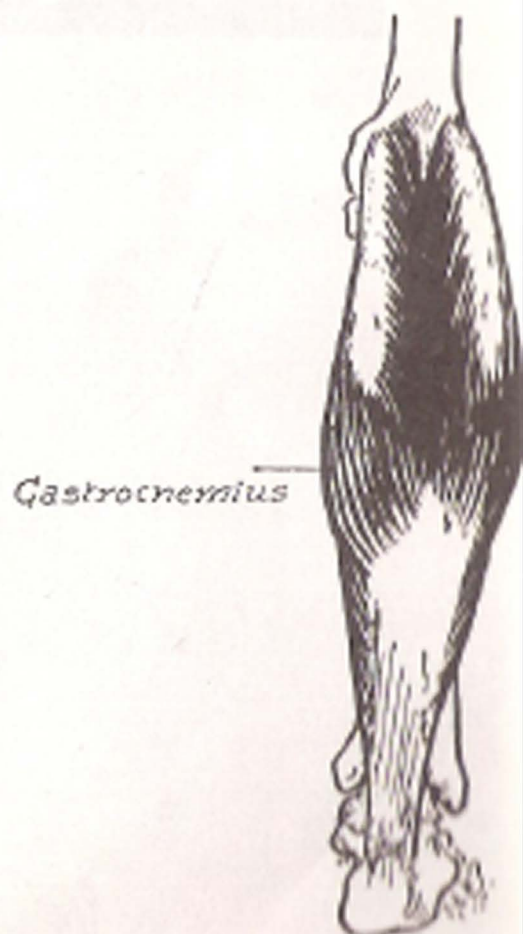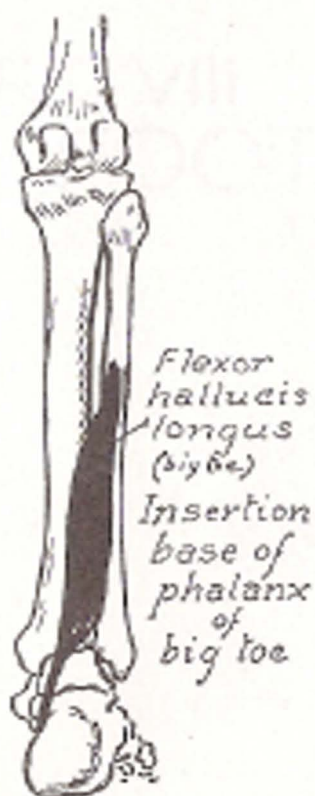
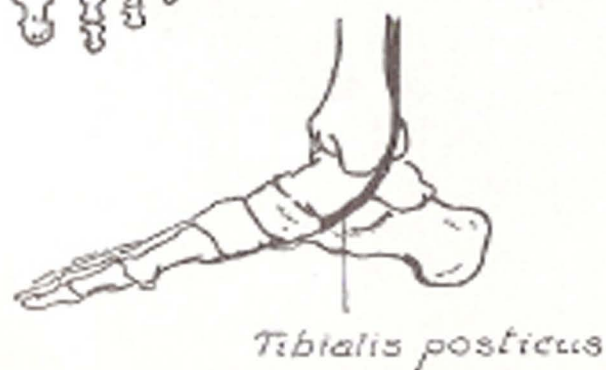
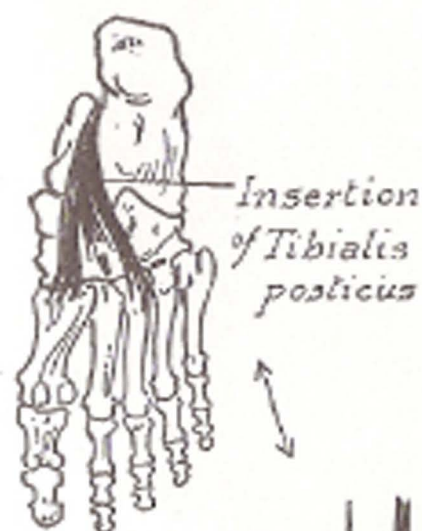








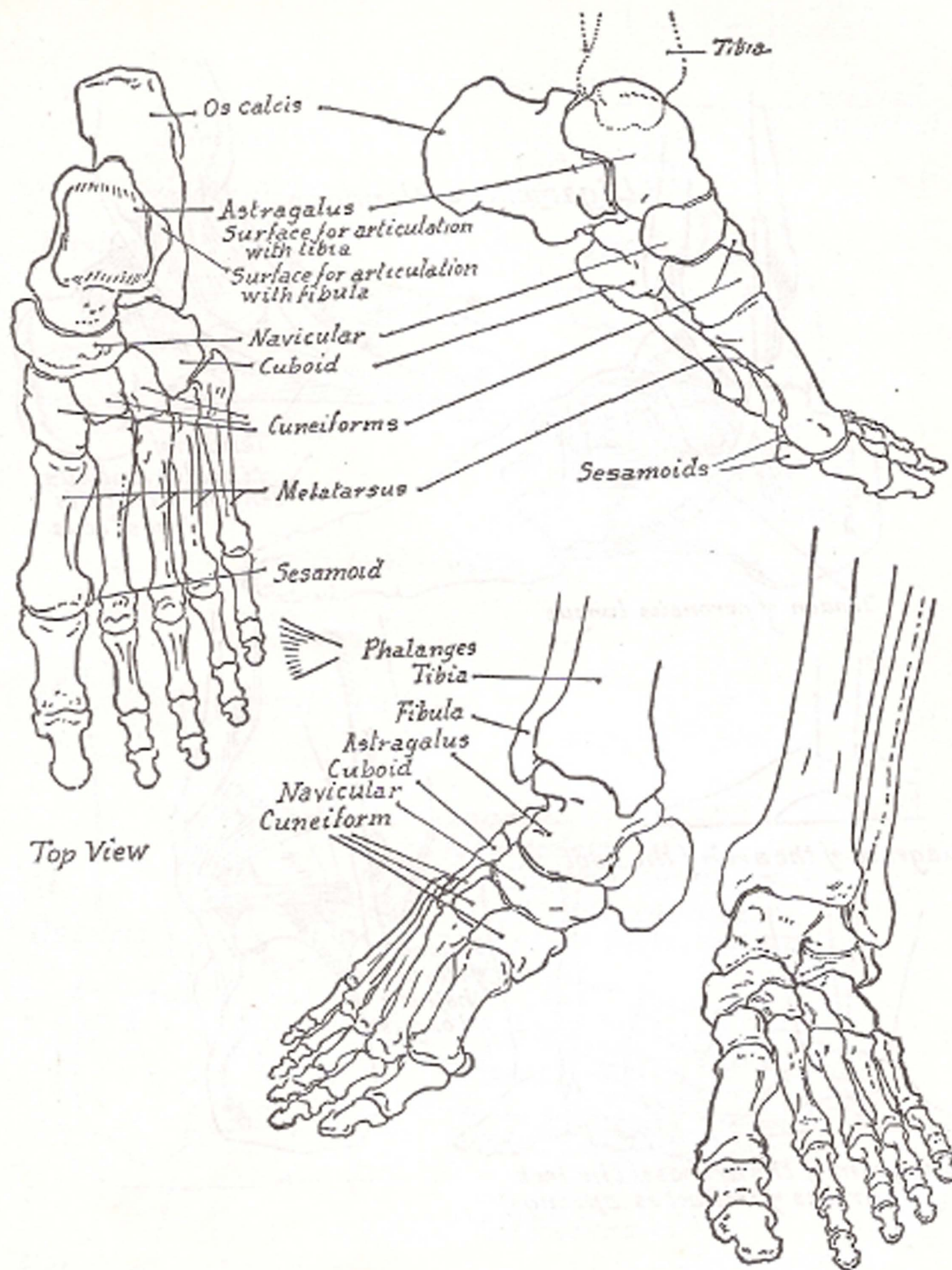
Muscles  
of the  
calf of leg

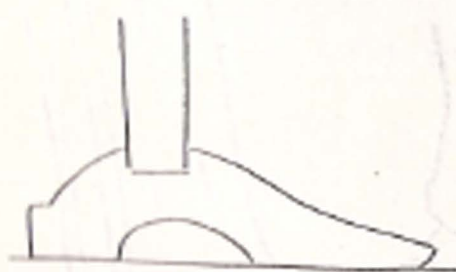
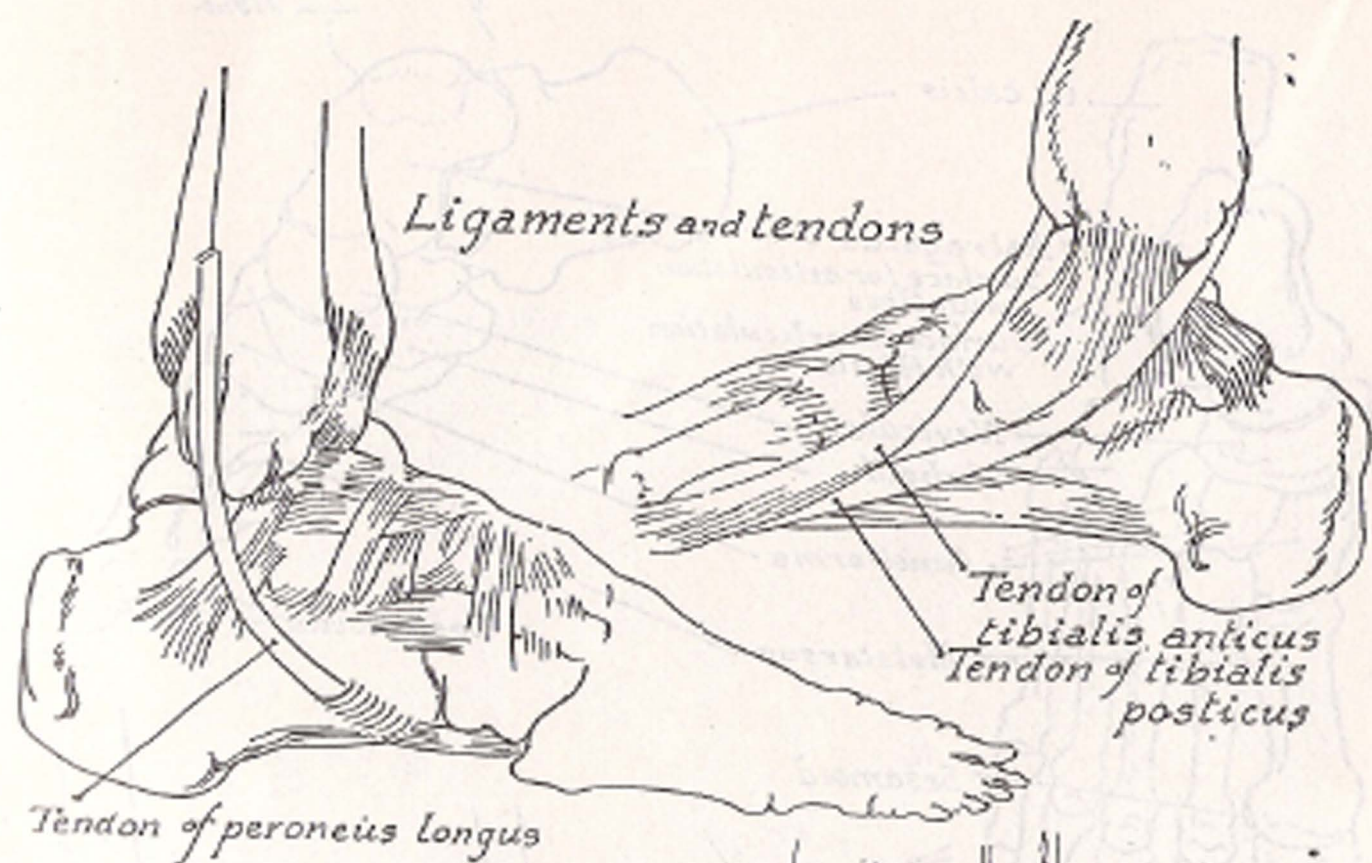




PART VIII  
THE FOOT



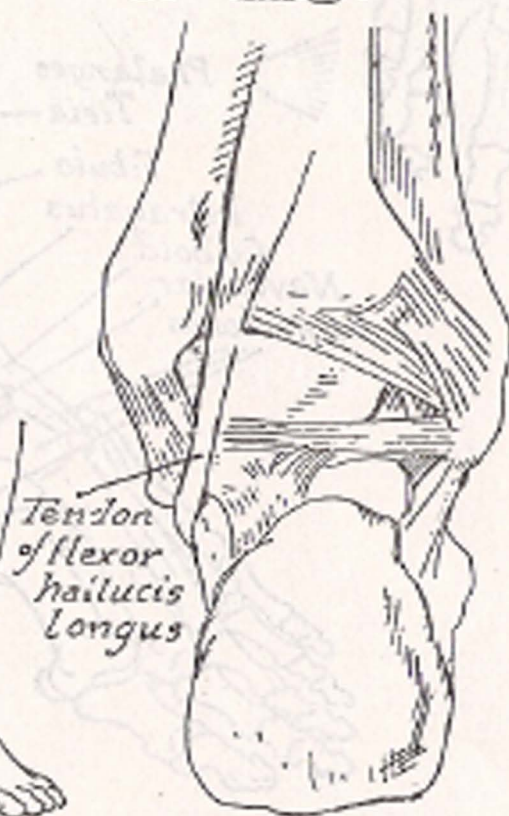


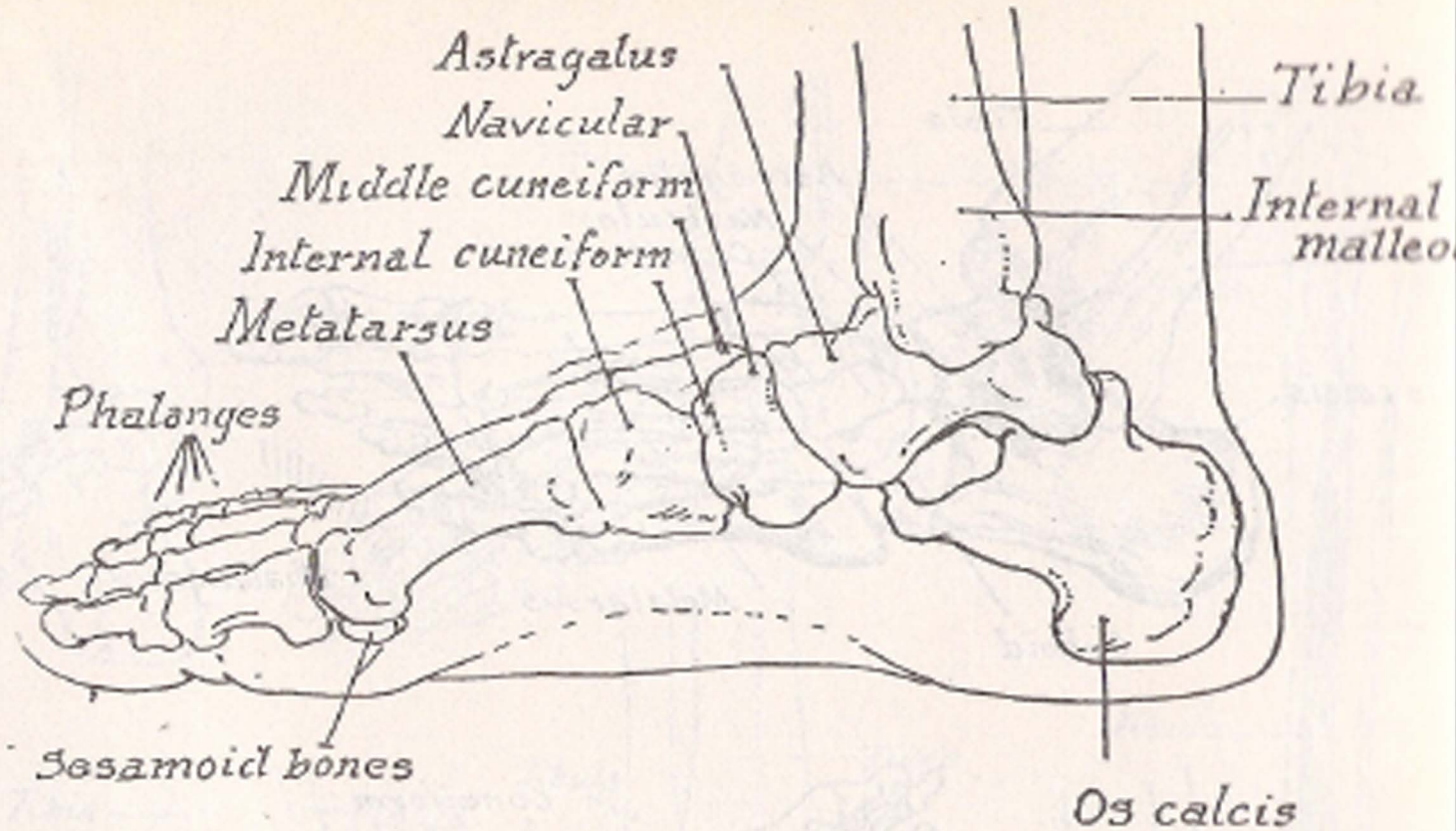


*Diagram of the arch of the foot*

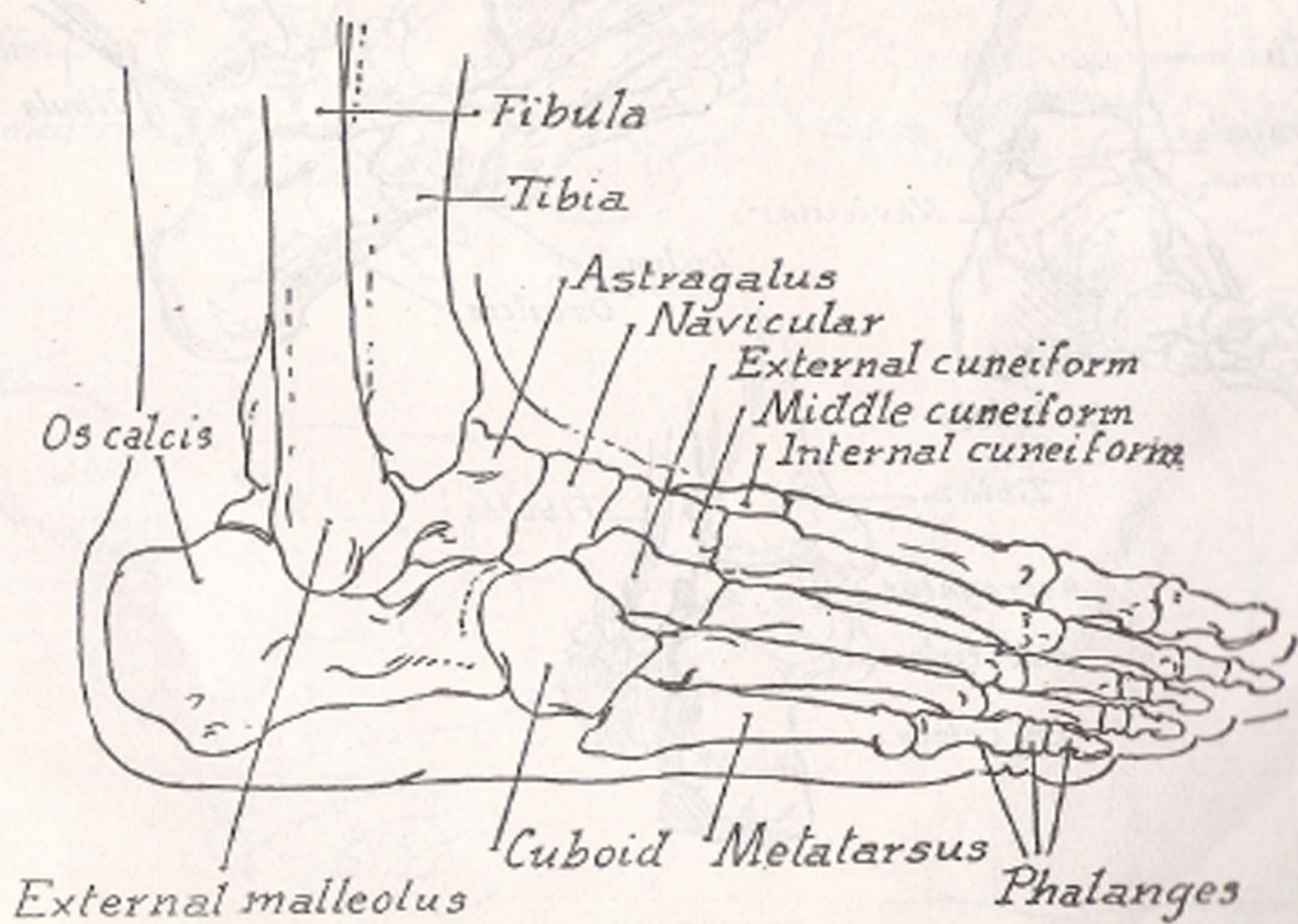


*Diagram of the arches of the feet*  
*(The arches of feet act as springs)*

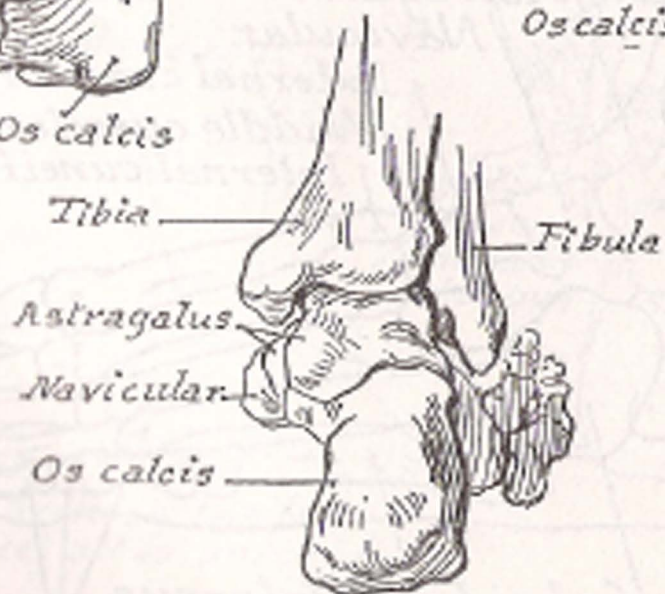
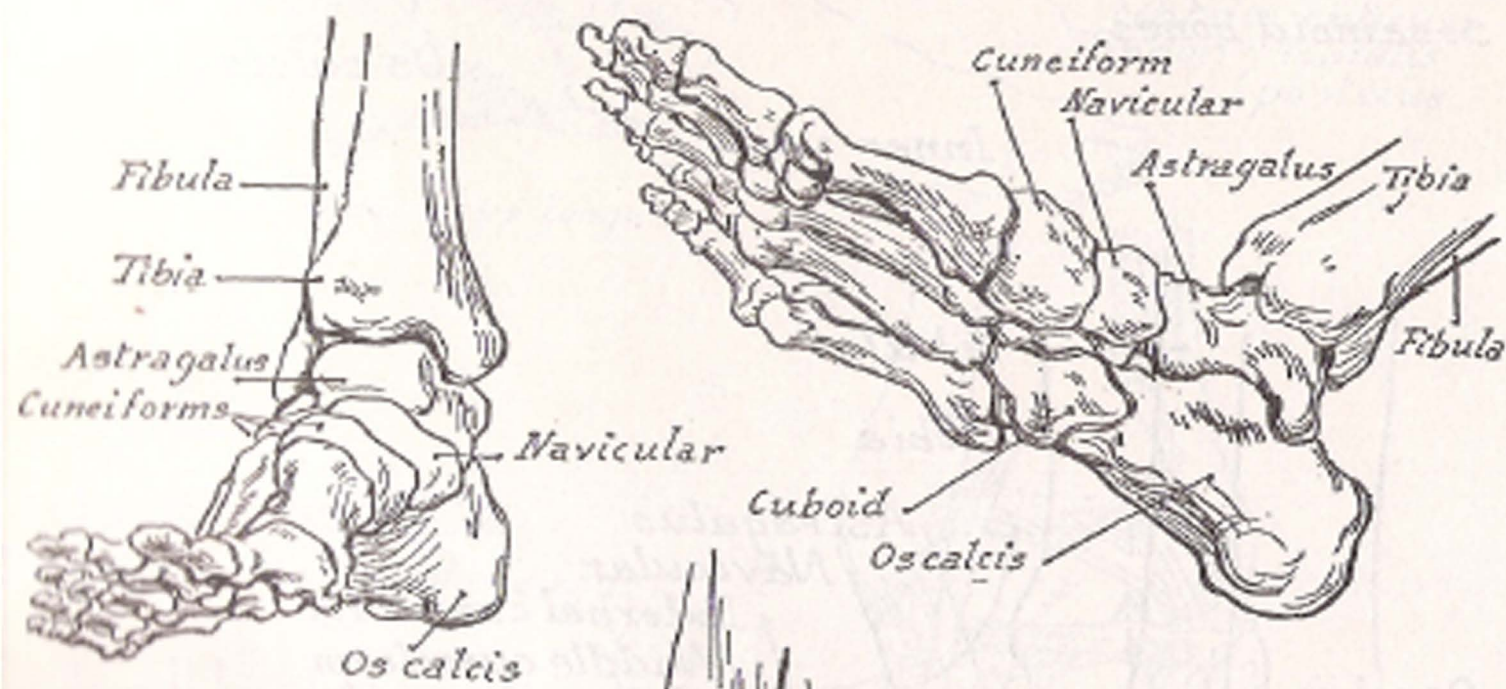
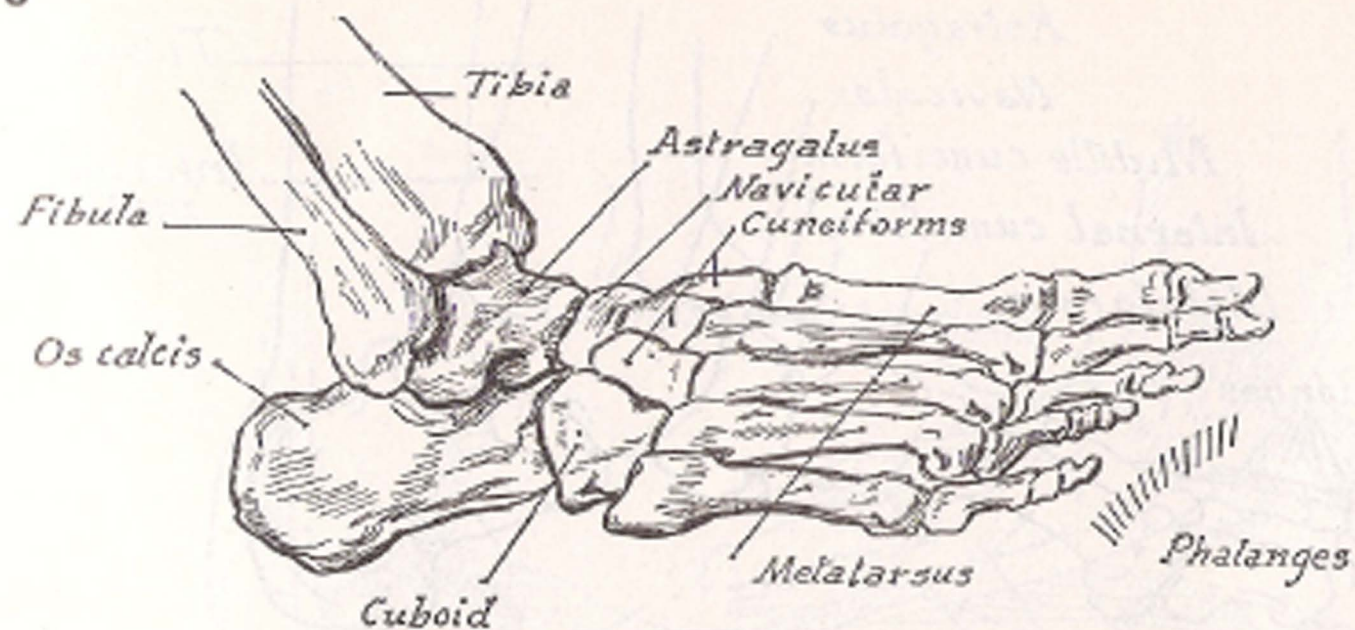


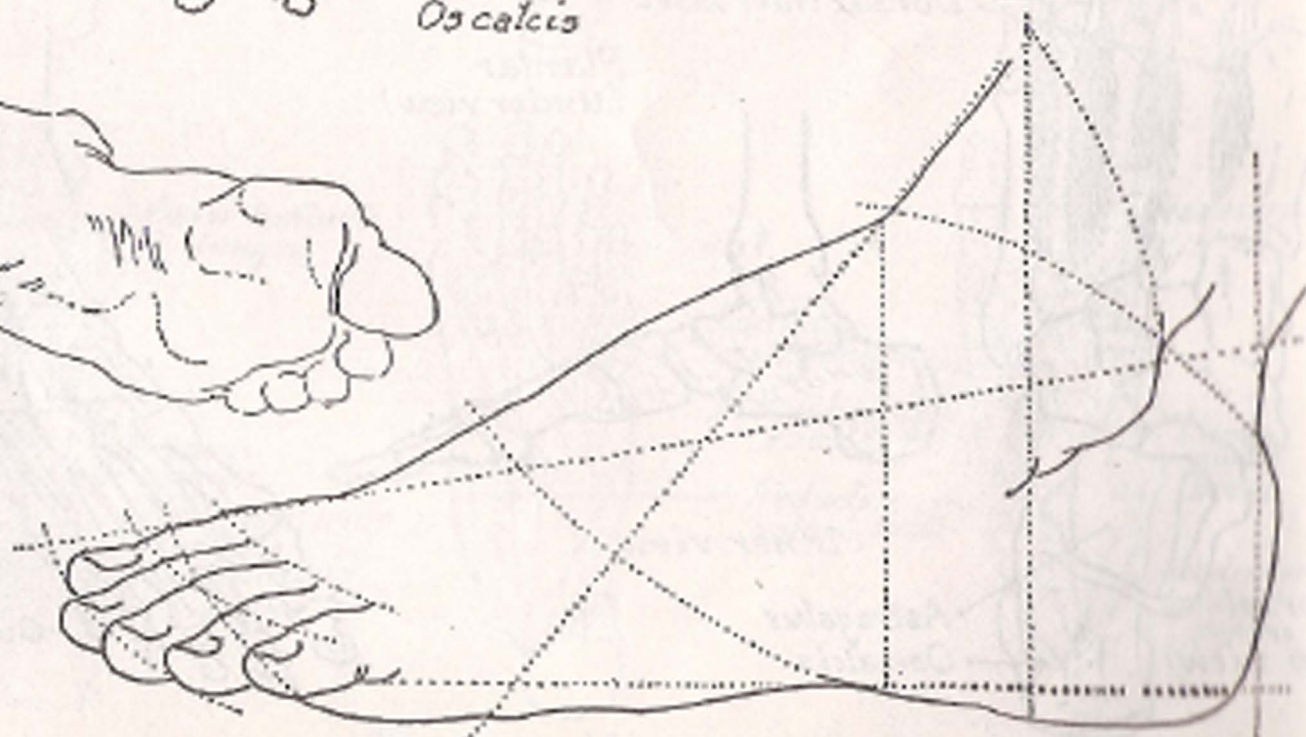
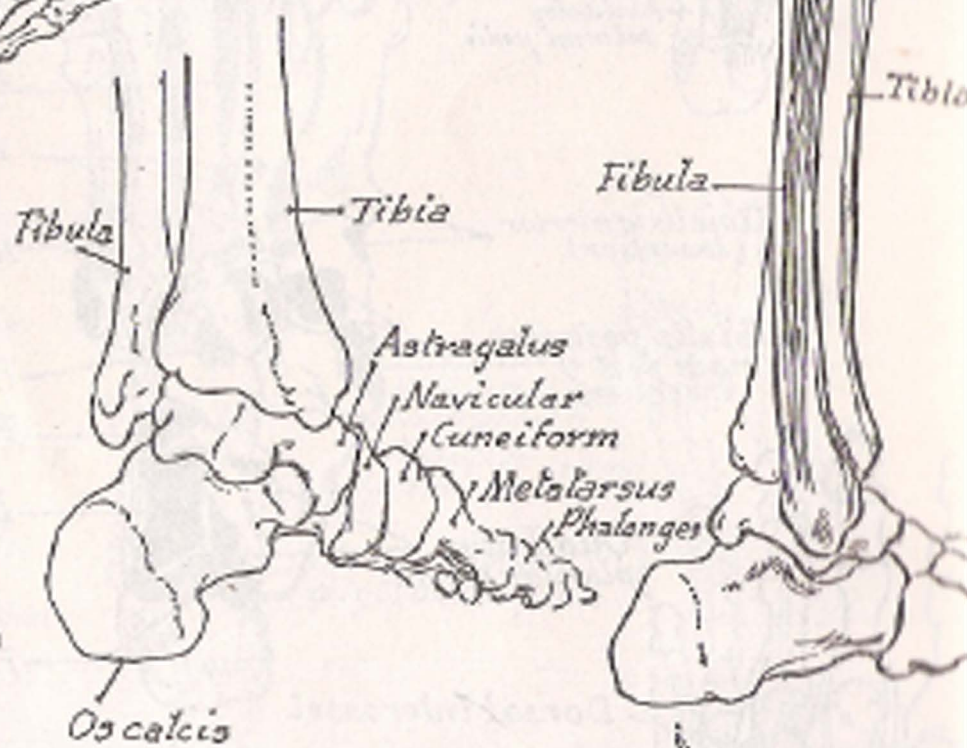
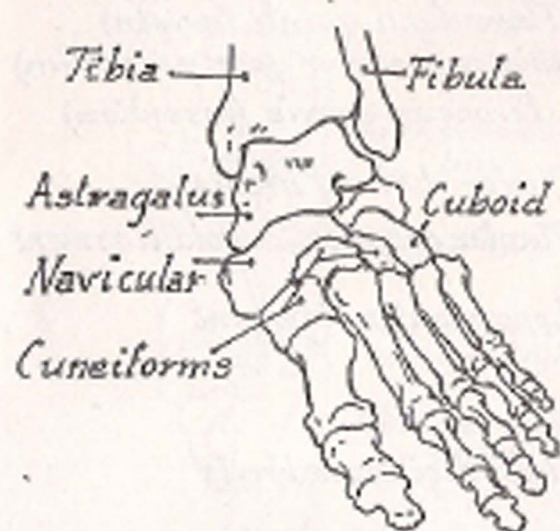
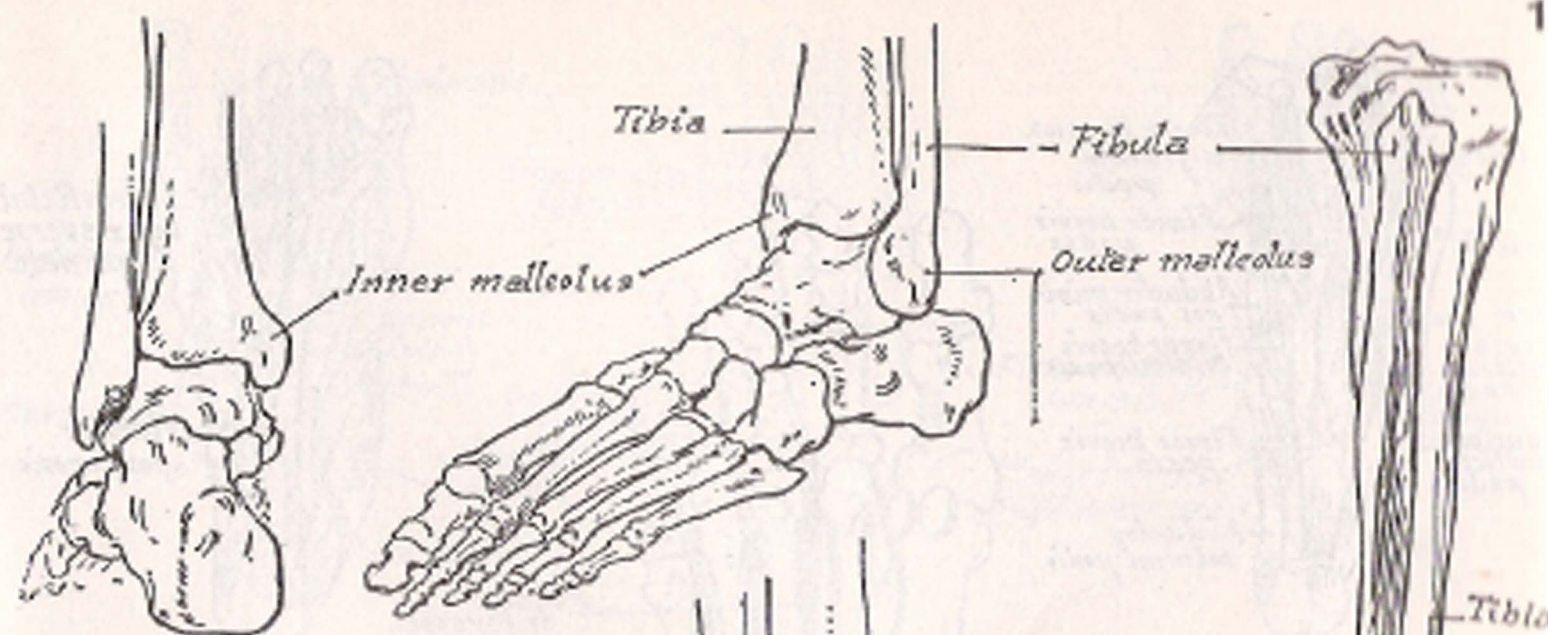


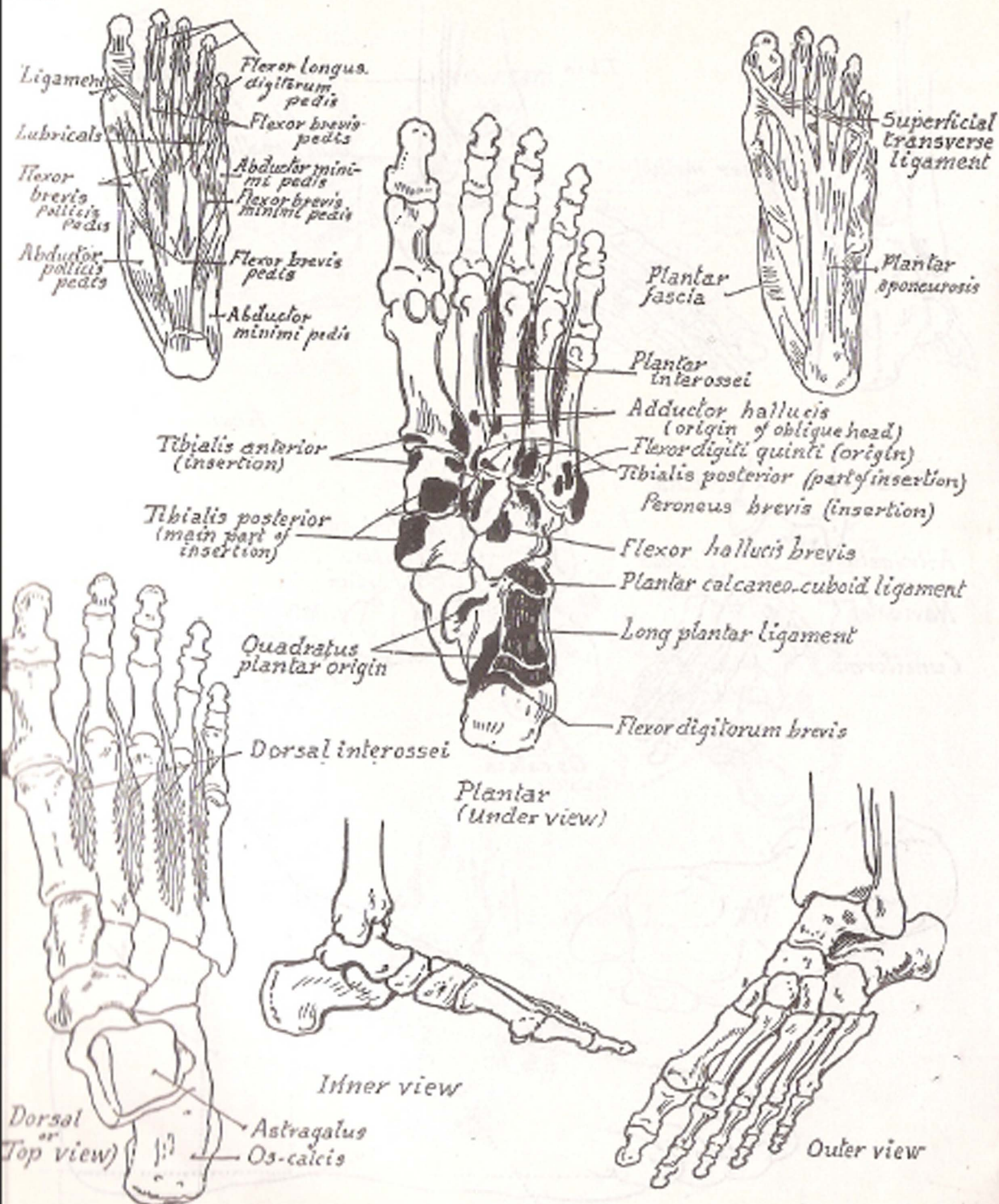
*Inner view*

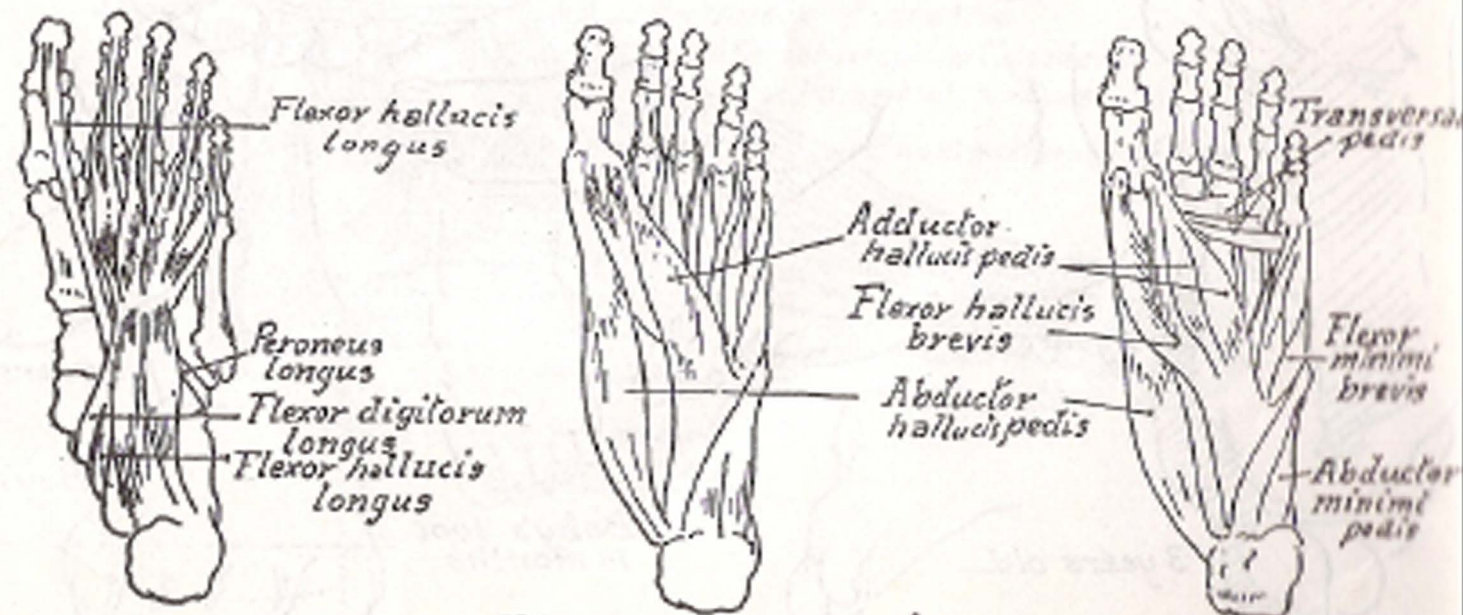
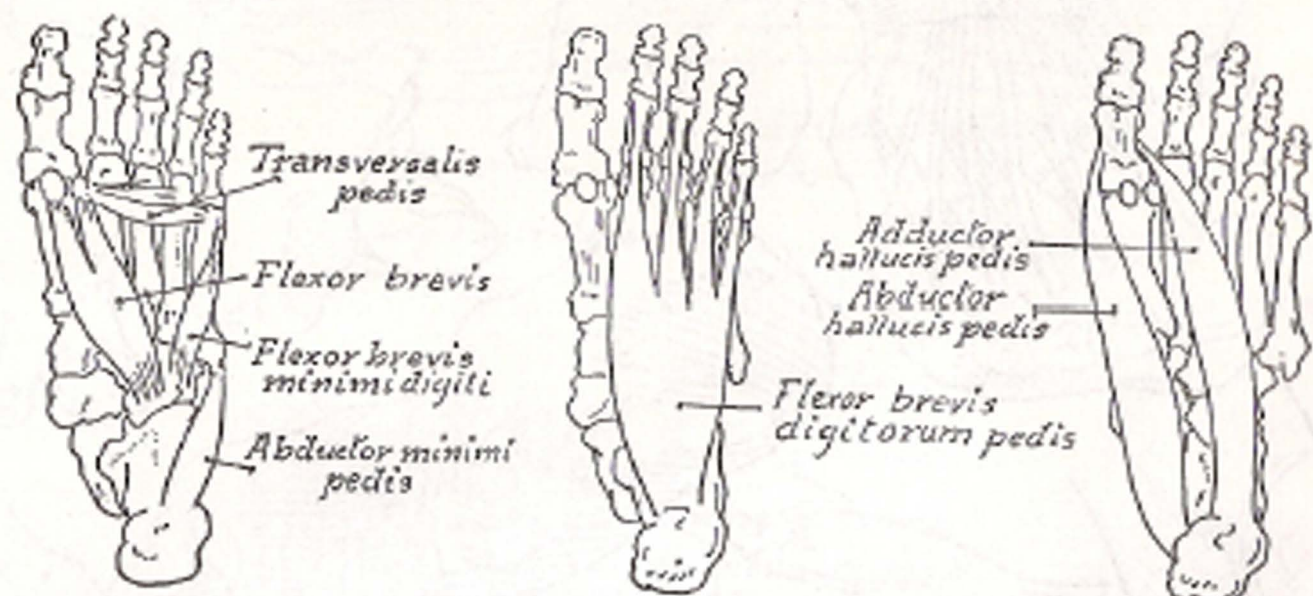
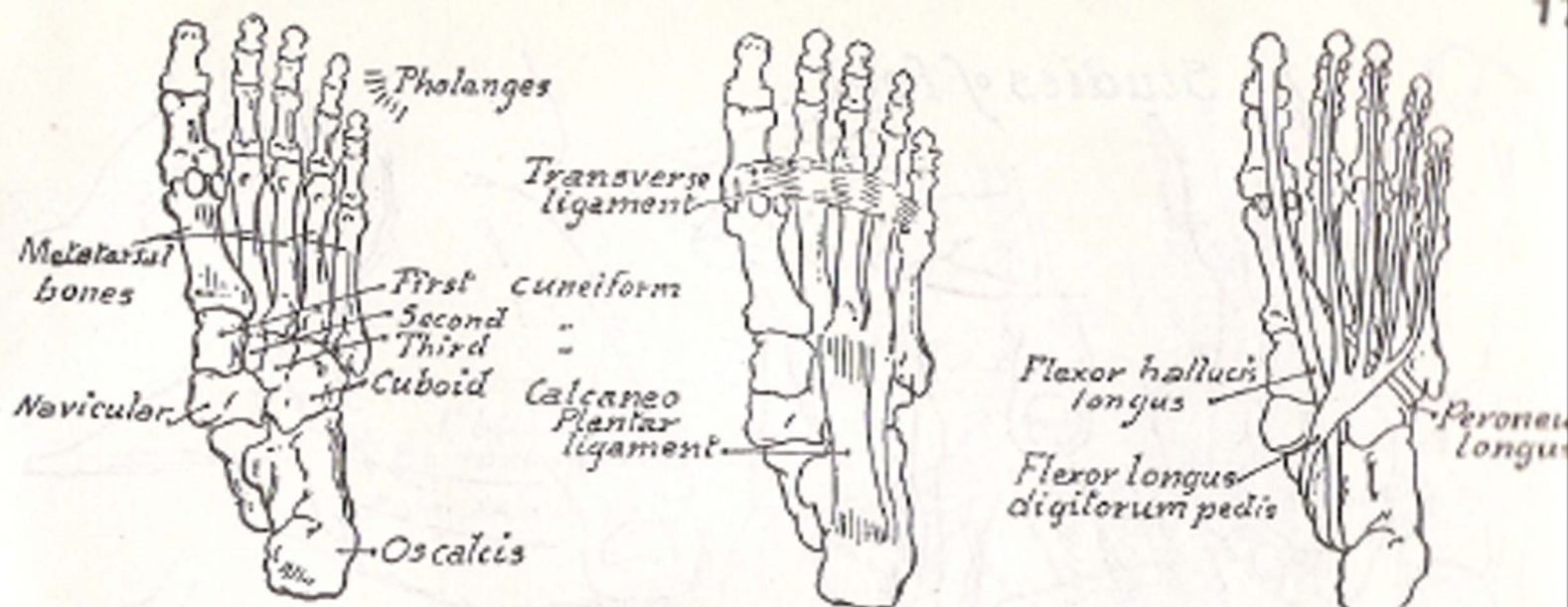


*Outer view*

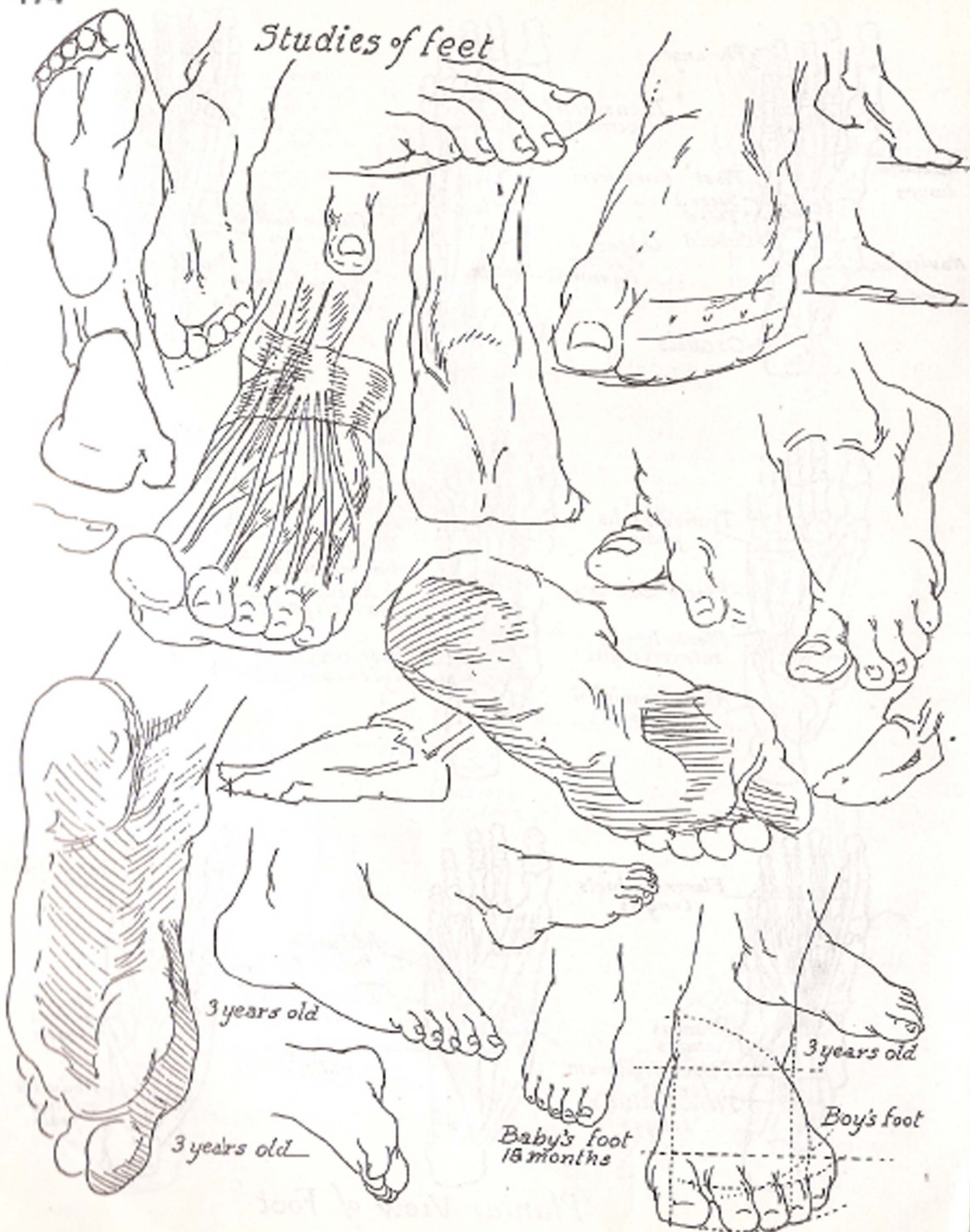



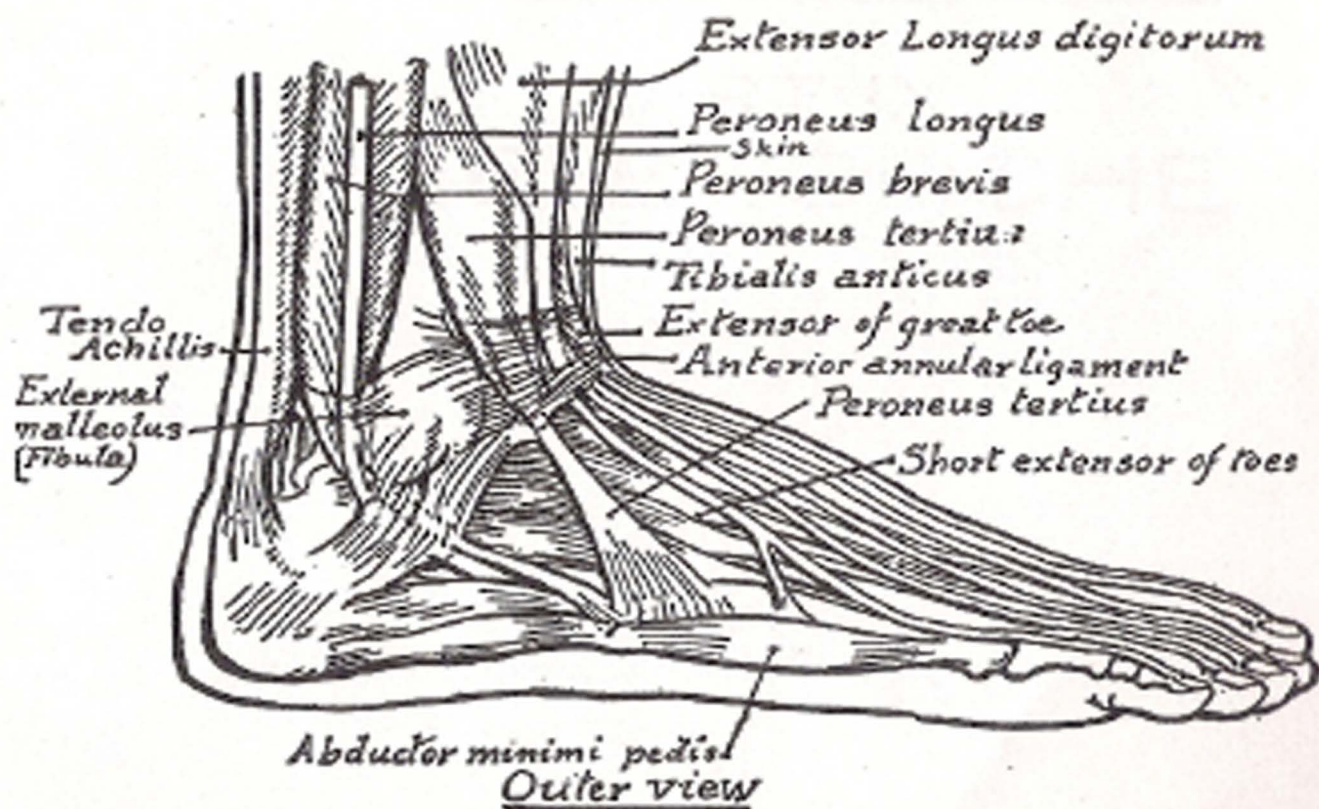
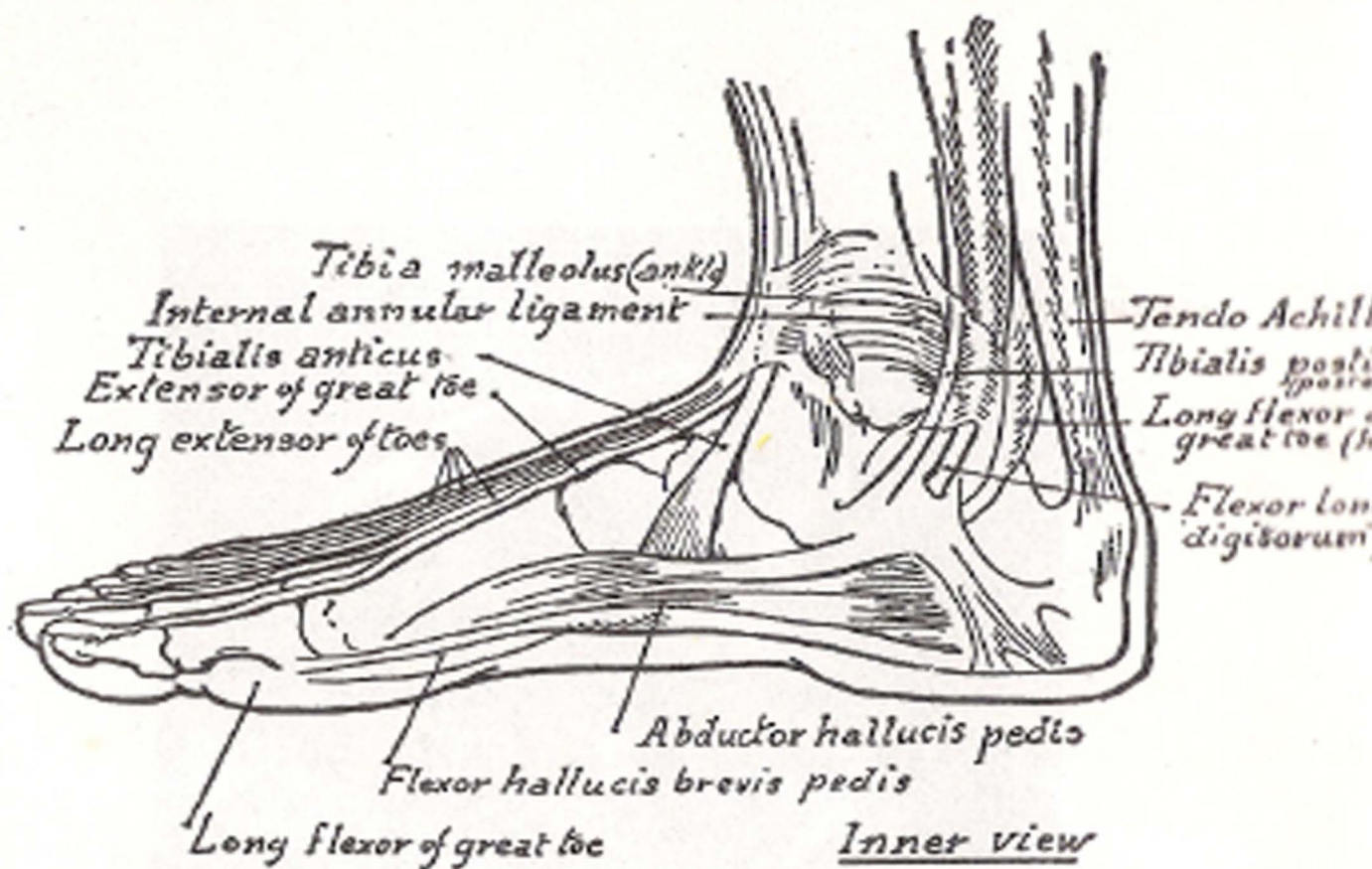




Plantar View of Foot


*Studies of feet*

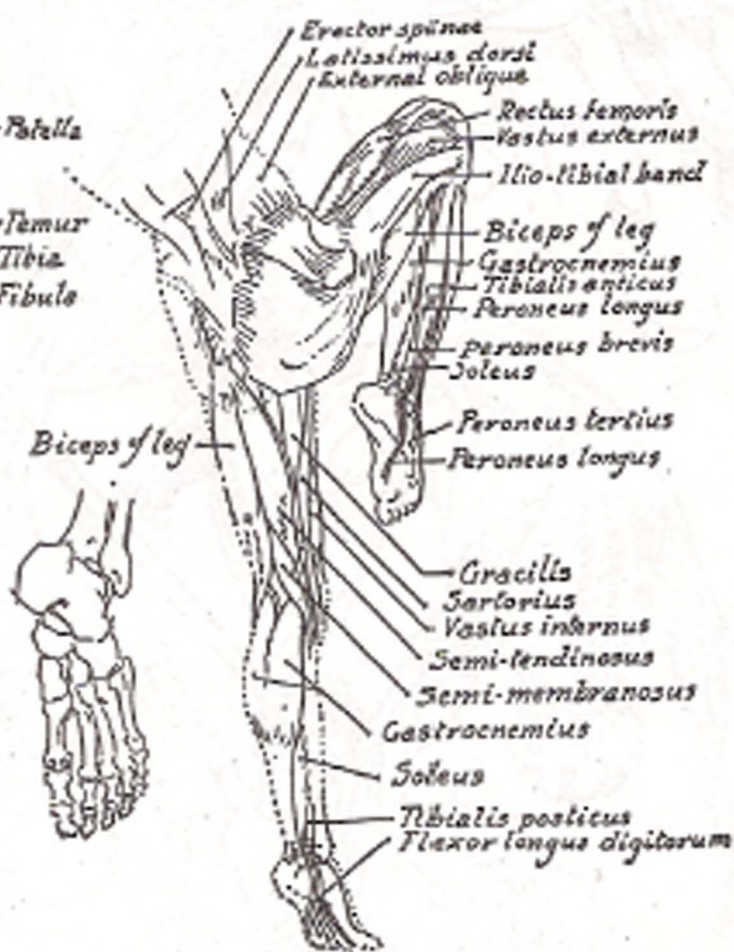
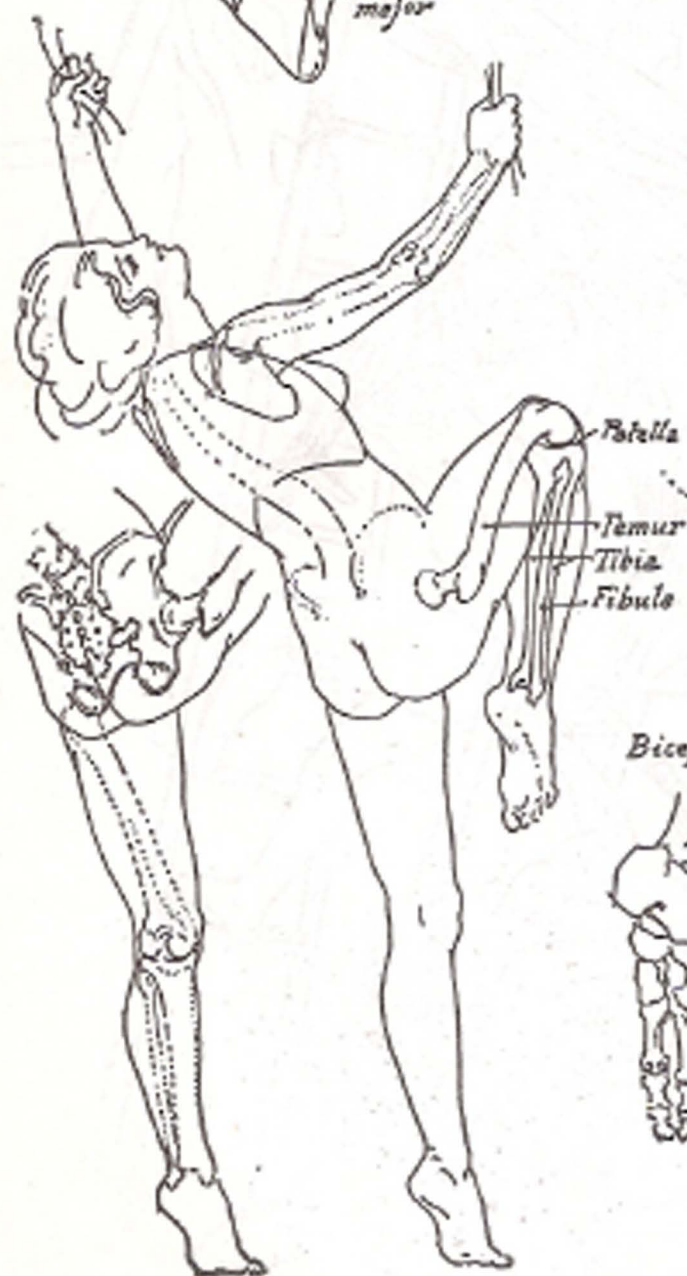
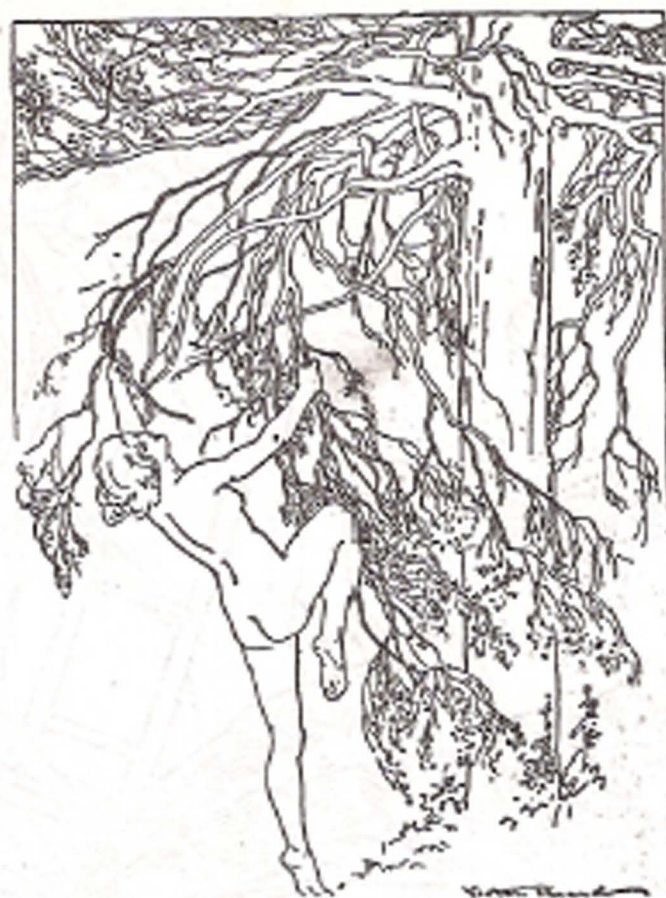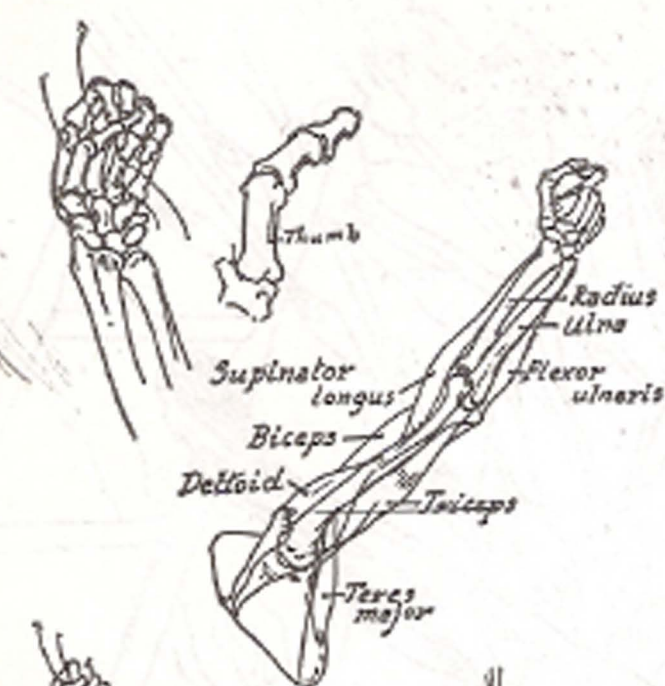







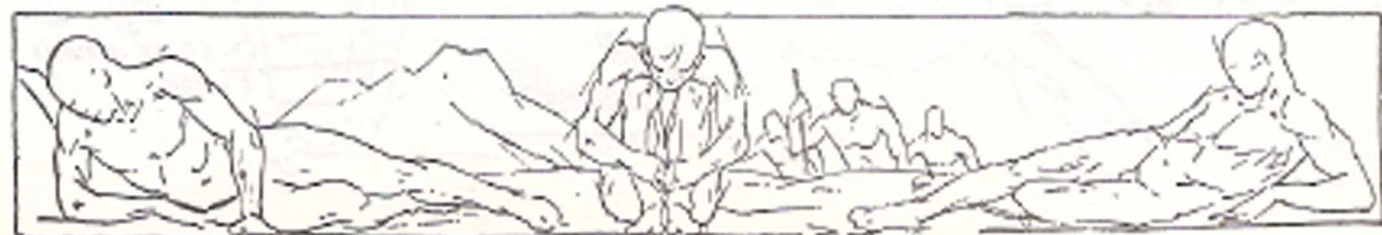PART IX  
THE ECORCHE

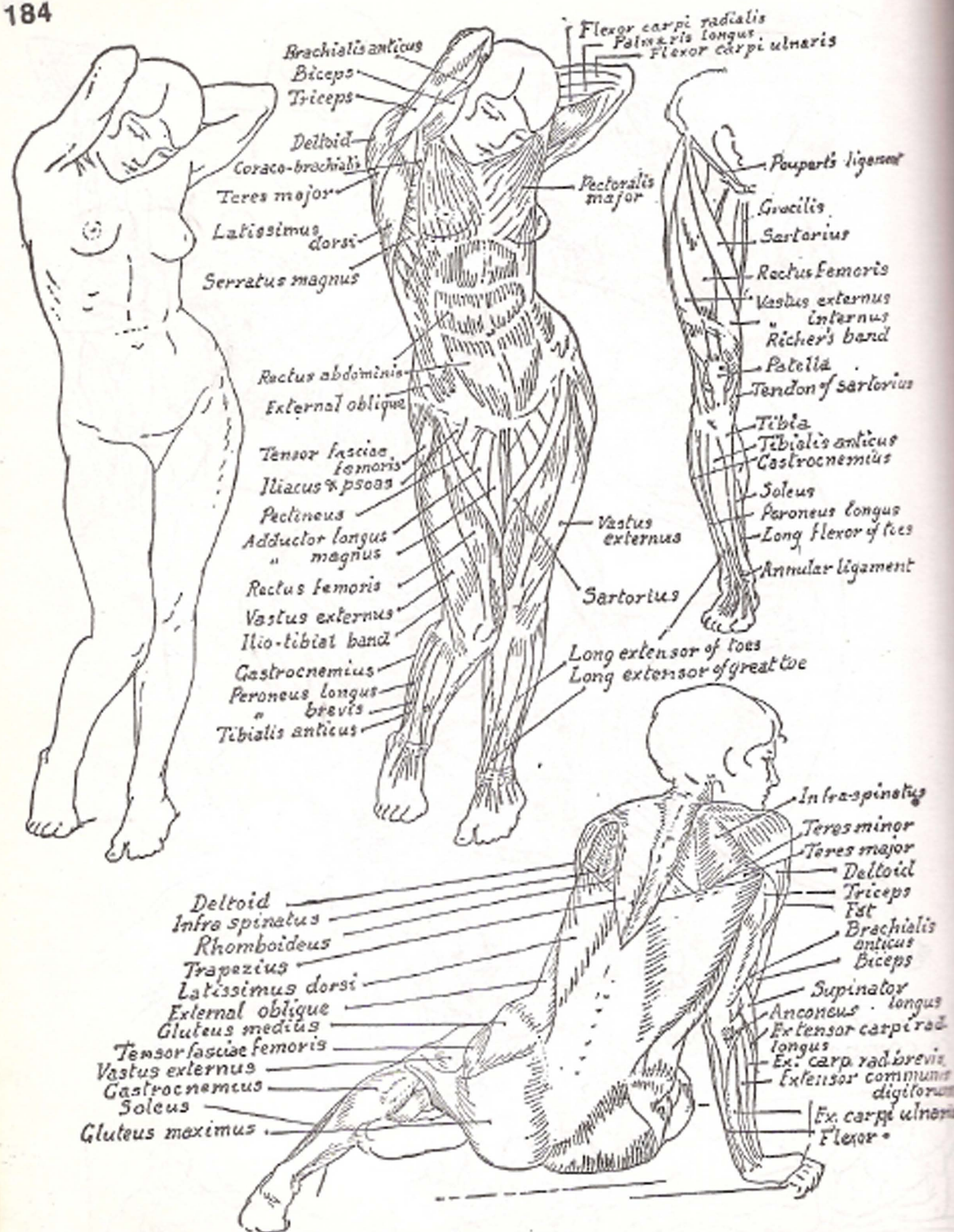


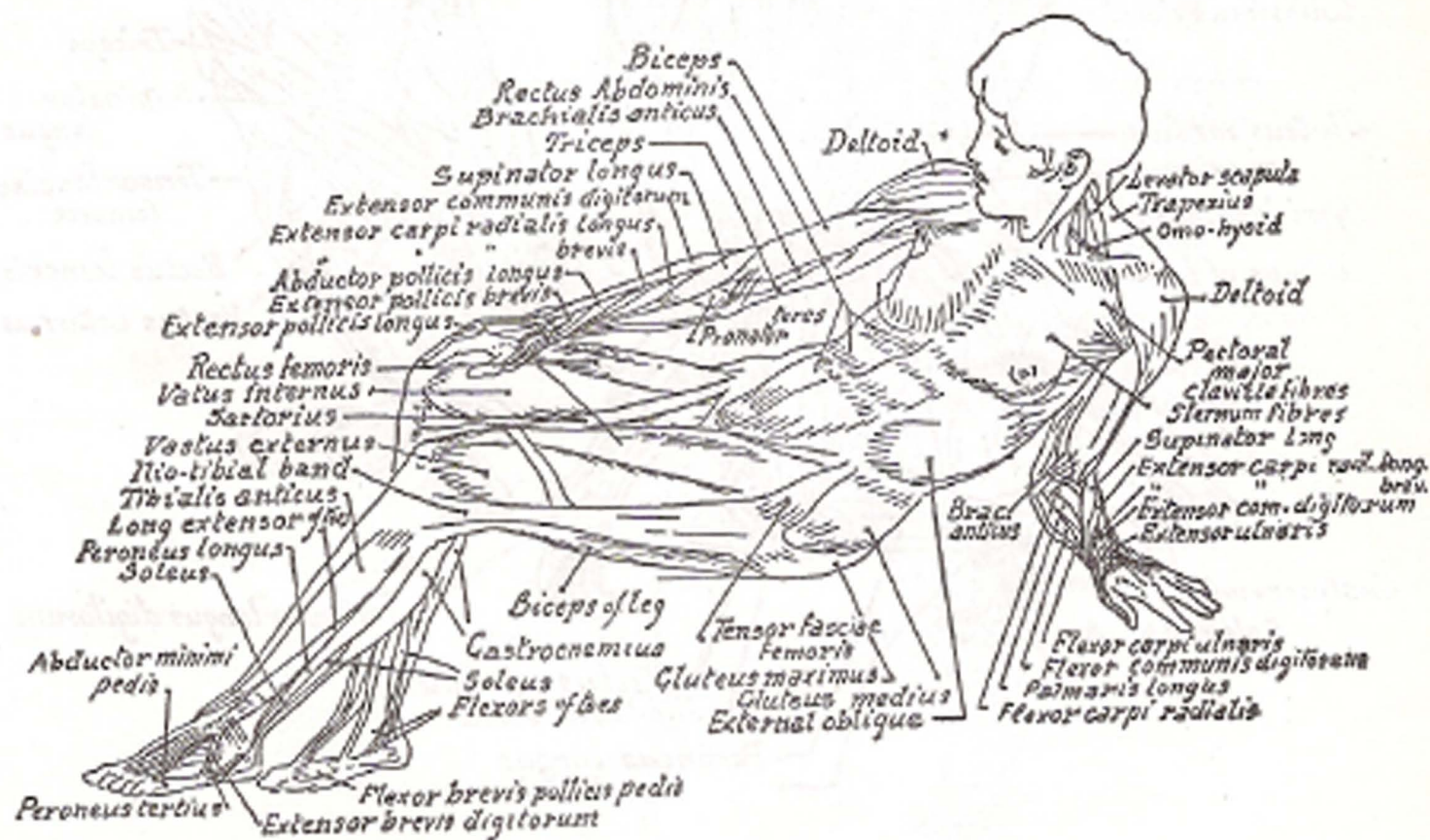
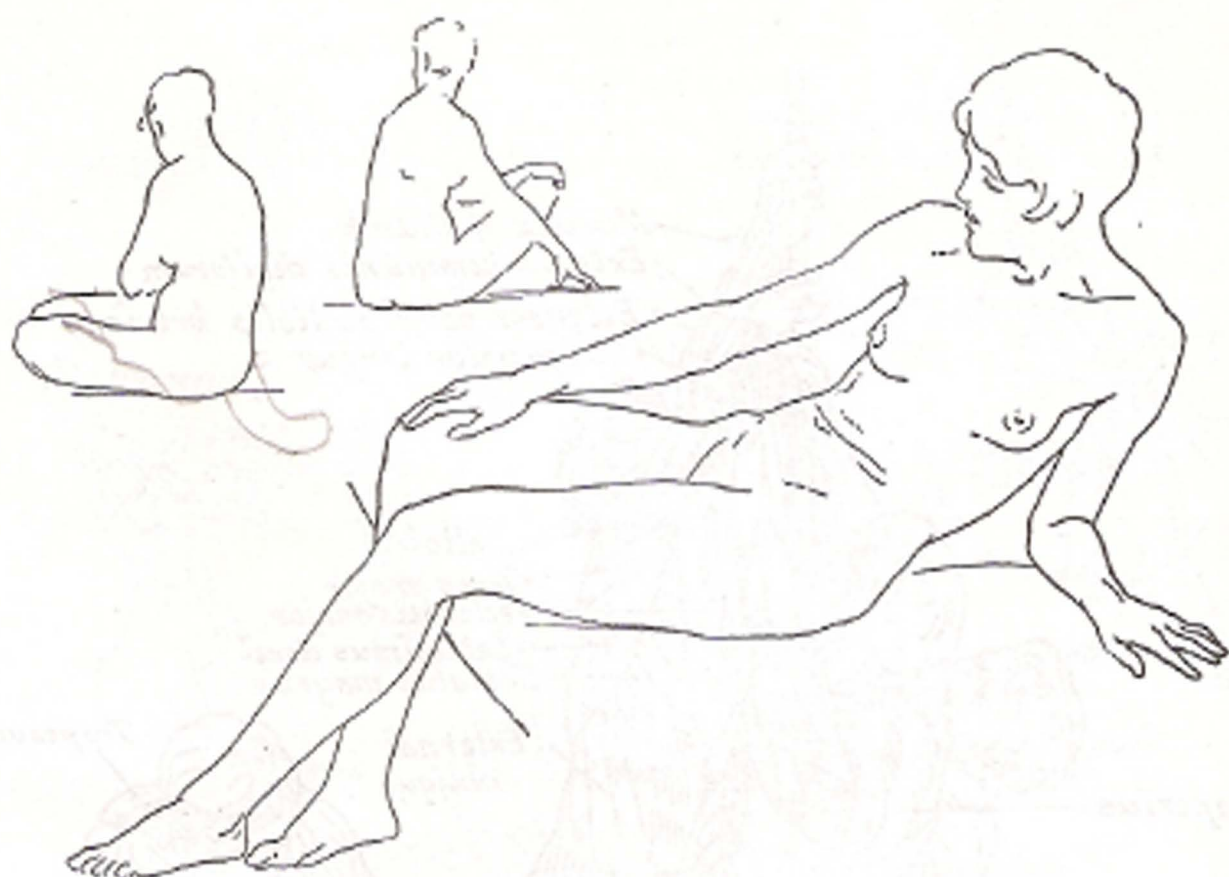


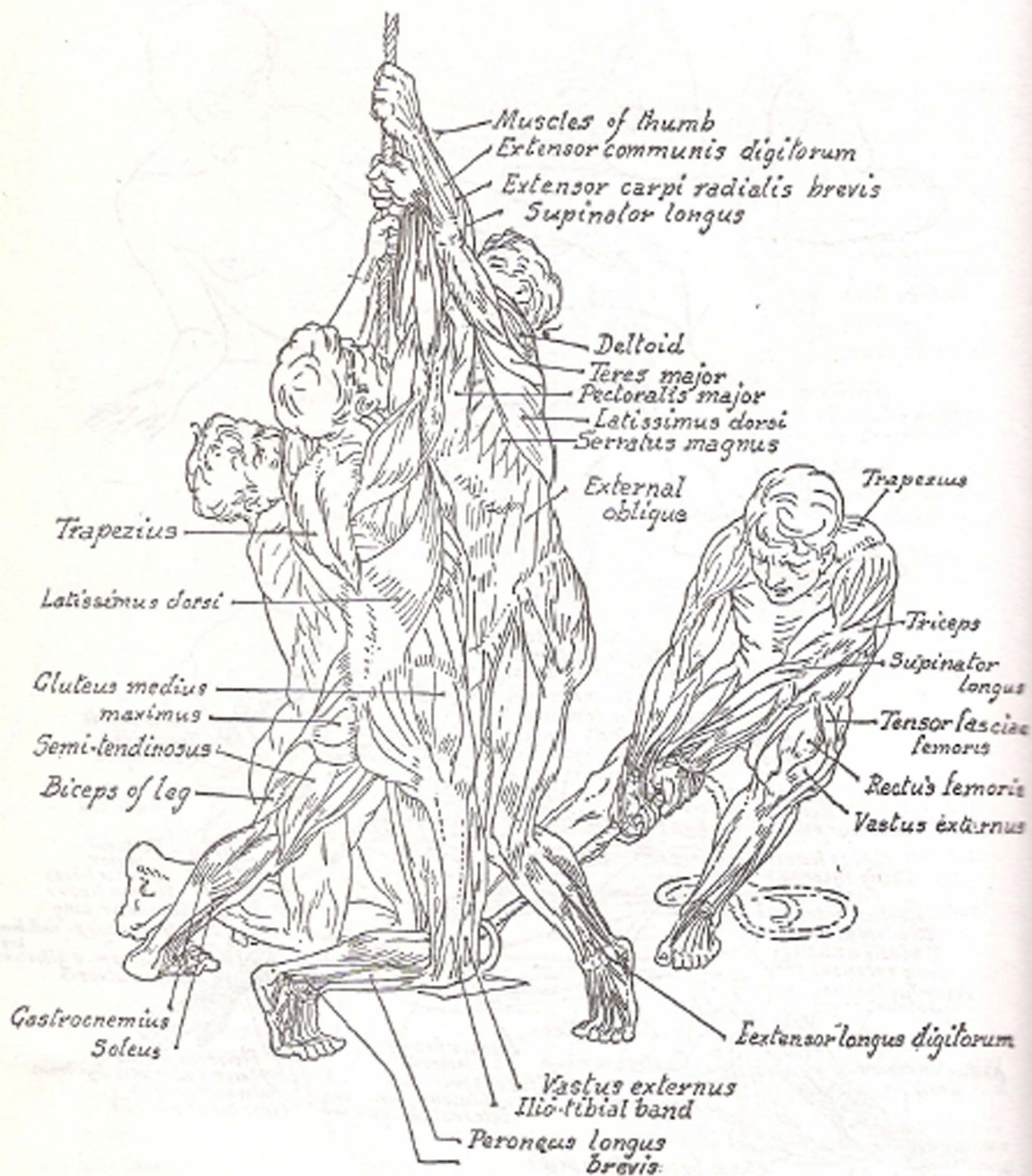


*Application of anatomy  
to composition*

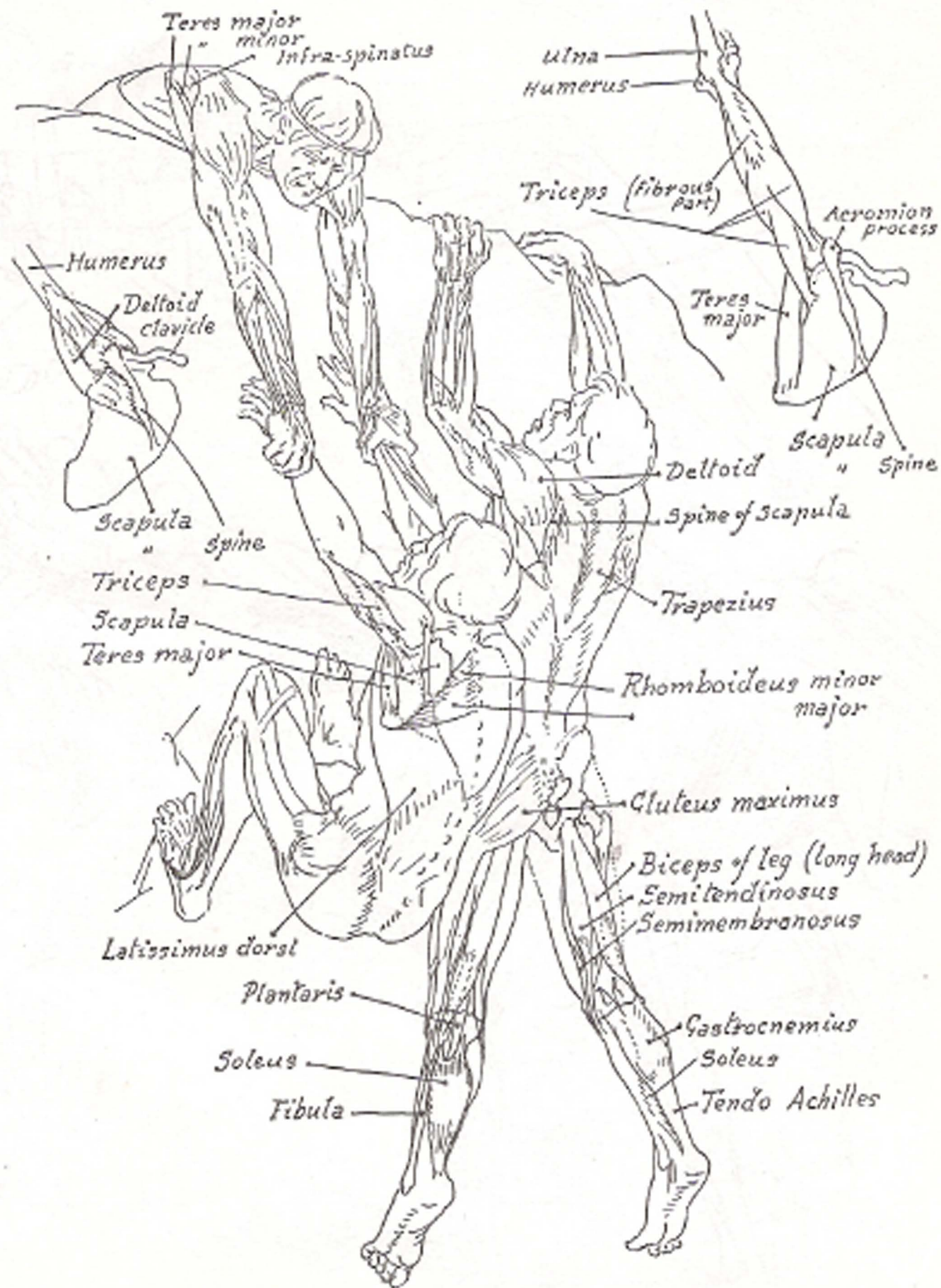





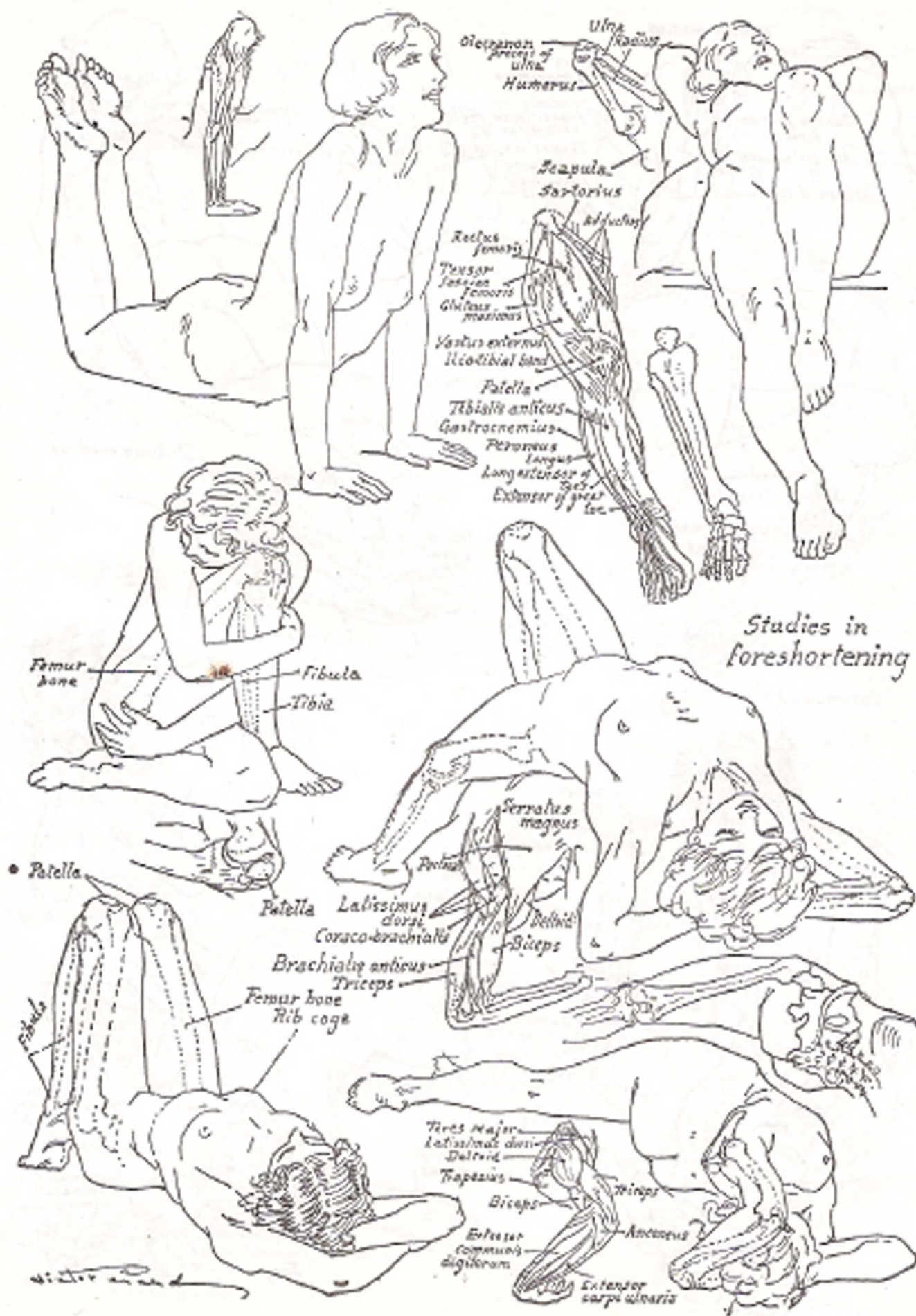


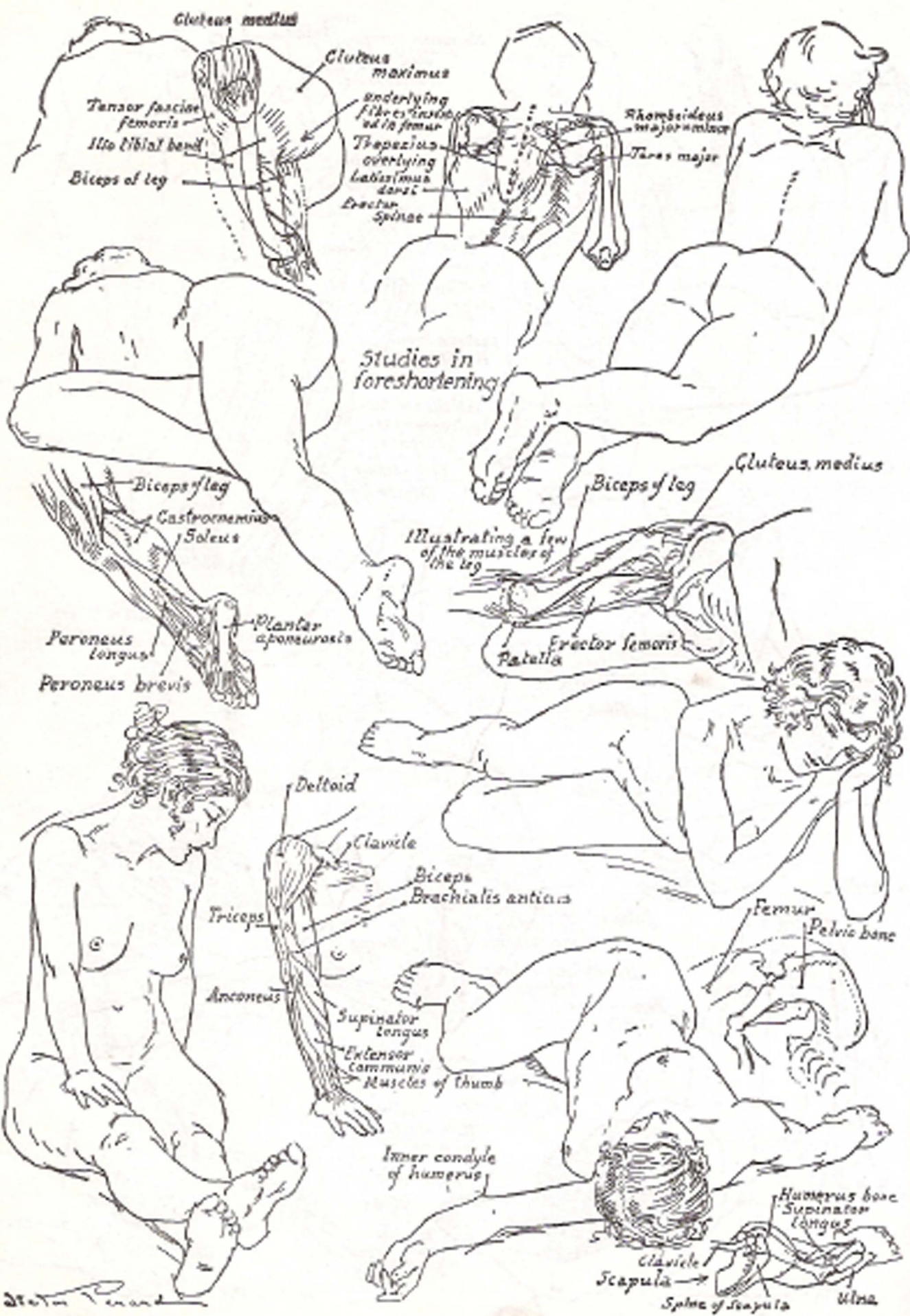


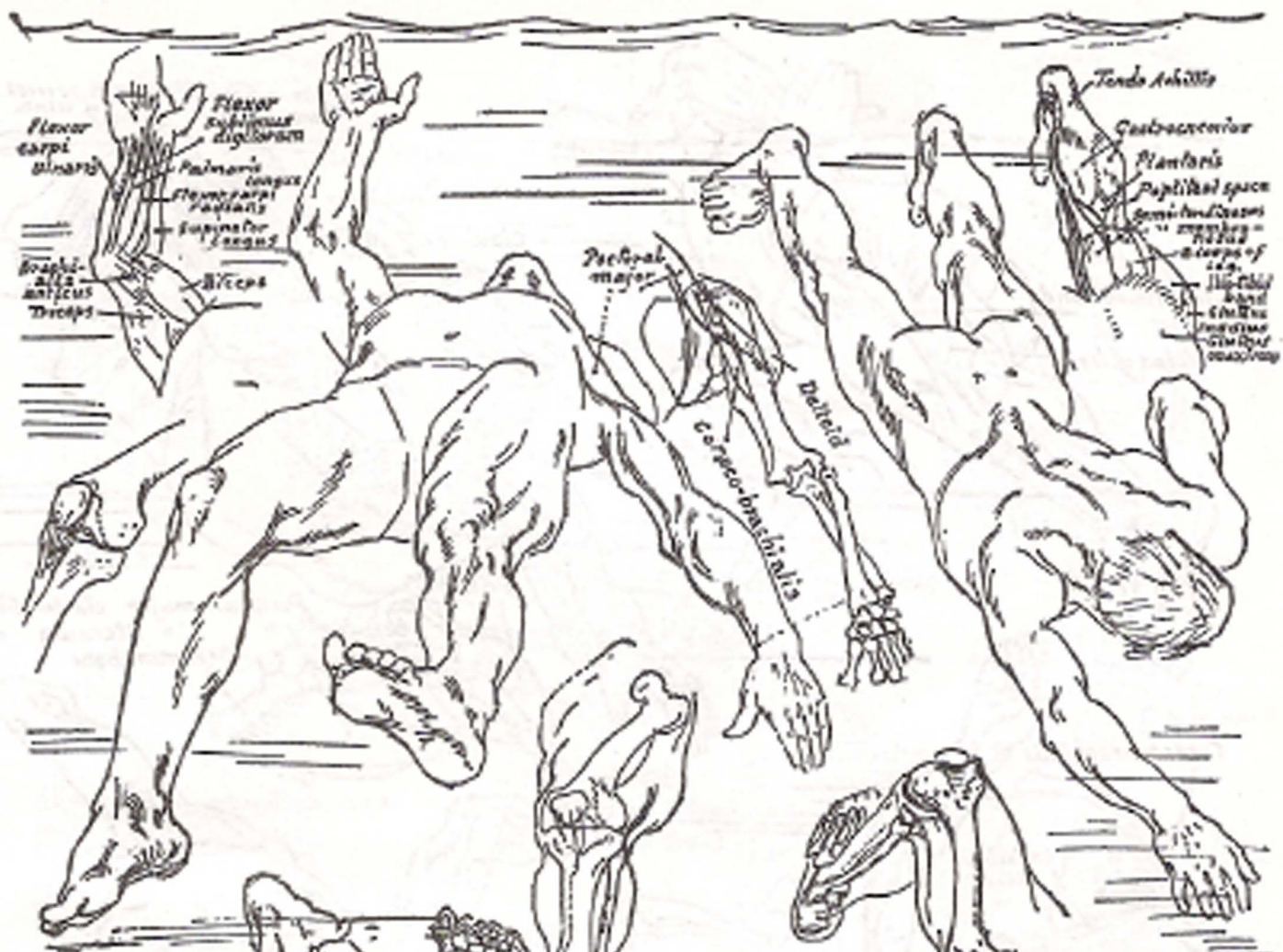




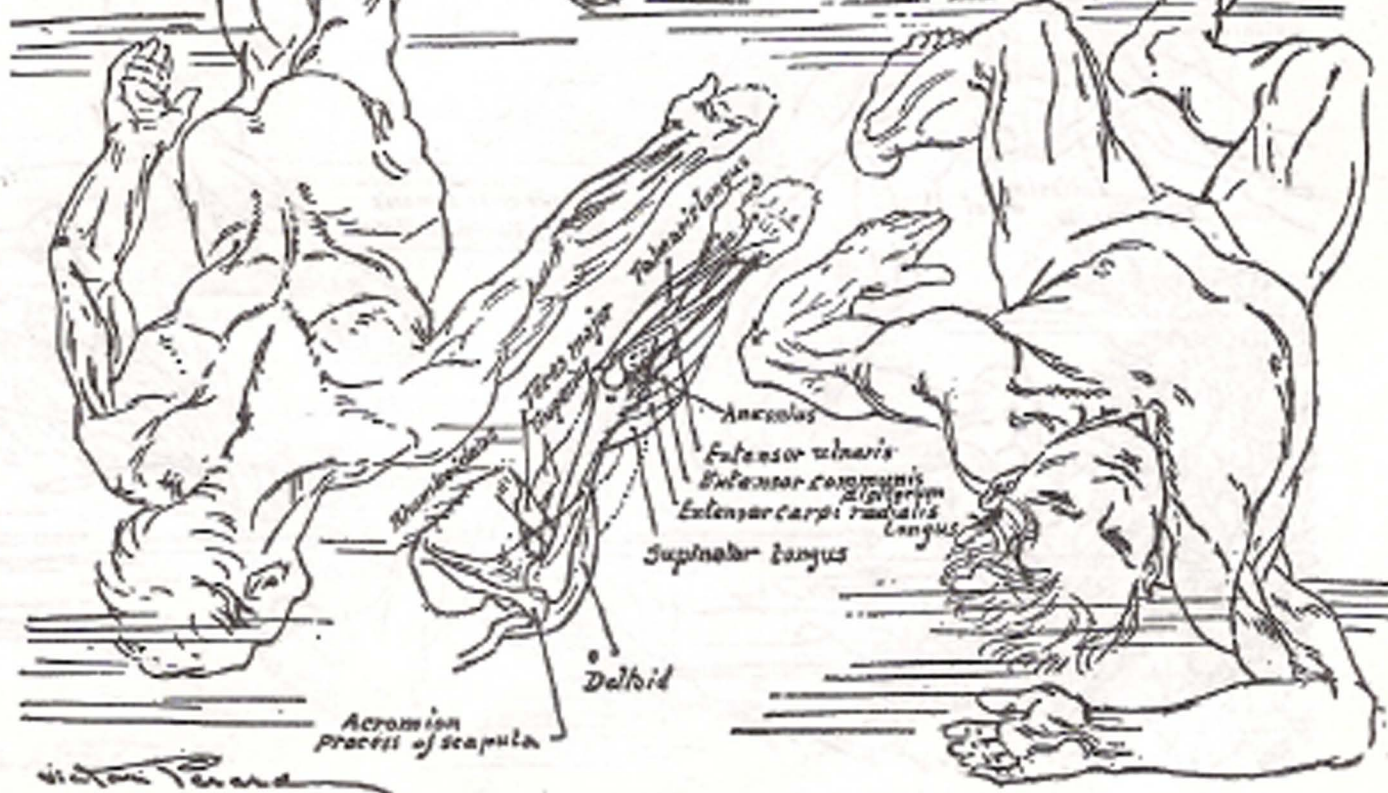







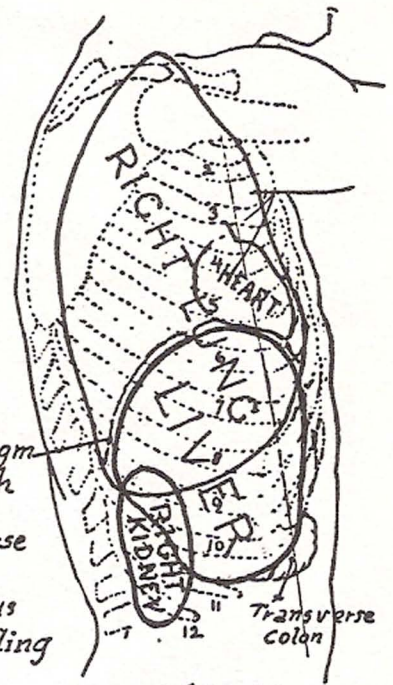
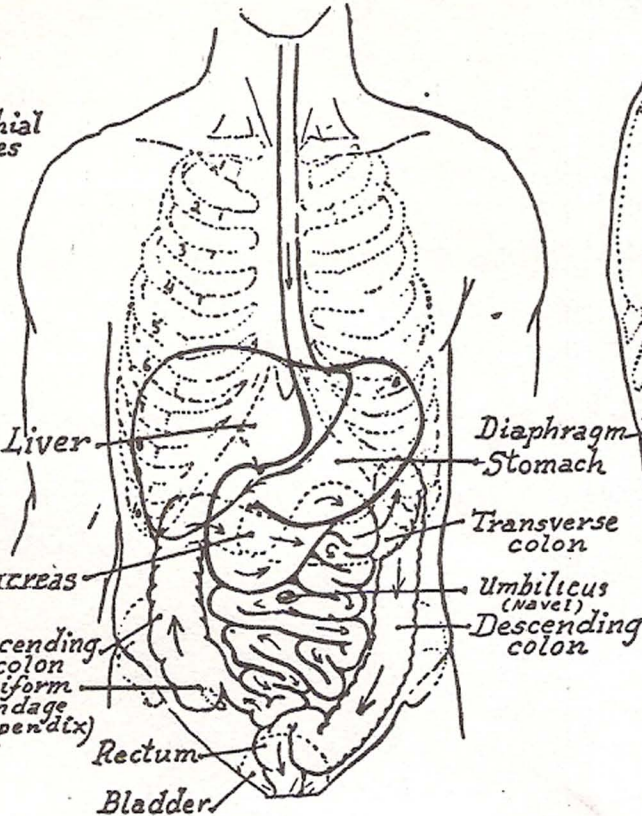
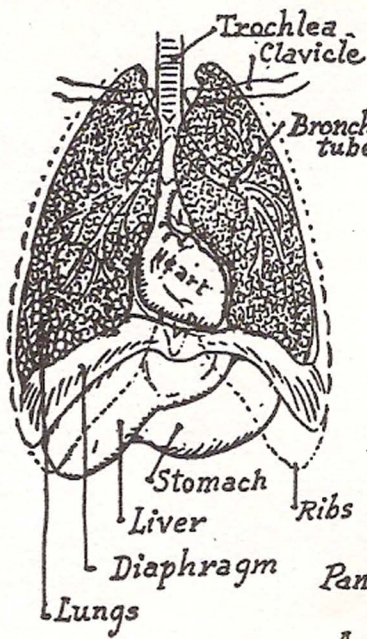


Studies in foreshortening

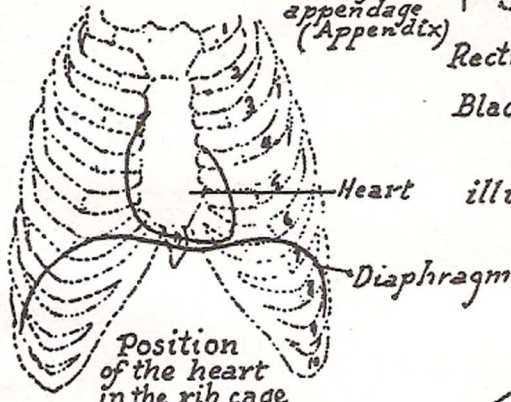


Victor Tenard



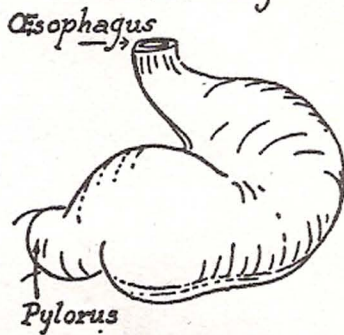


Right side showing relative position of lung, liver & kidney

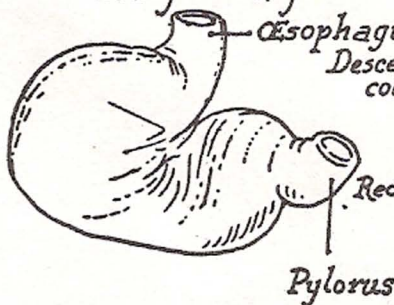


Position of the heart in the rib cage

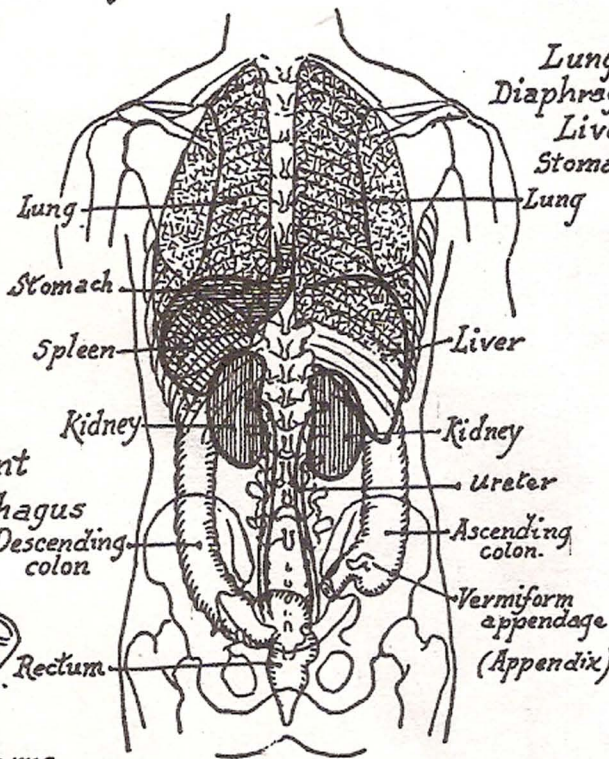
Front view illustrating position of digestive tract



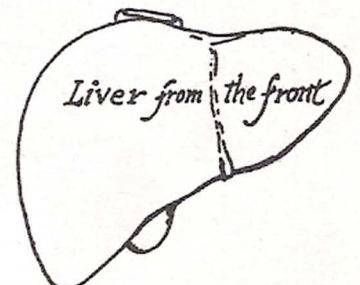
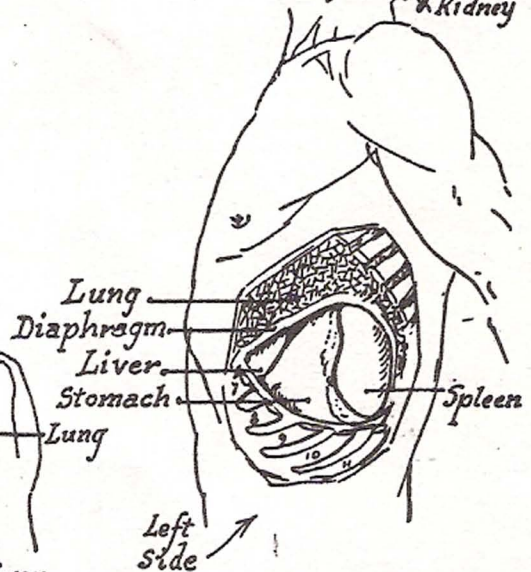
Stomach from the front



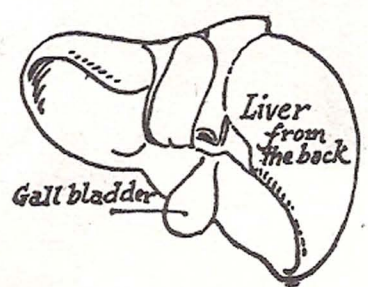
Stomach from the back



Back view illustrating relative positions of internal organs



Liver from the front



Liver from the back